

> E. GHENO<sup>1</sup>, A. PALERMO<sup>2</sup>, L.F. RODELLA<sup>3</sup>, B. BUFFOLI<sup>3</sup>

<sup>1</sup>Private practitioner in Somma Lombardo (Va), Italy;

<sup>2</sup>Private practitioner in Lecce, Italy;

<sup>3</sup>Section of Anatomy and Physiopathology, Department of Clinical and Experimental Sciences, University of Brescia, Italy

## The effectiveness of the use of xenogeneic bone blocks mixed with autologous Concentrated Growth Factors (CGF) in bone regeneration techniques: a case series

### TO CITE THIS ARTICLE

Gheno E, Palermo A, Buffoli B, Rodella LF. The effectiveness of the use of xenogeneic bone blocks mixed with autologous Concentrated Growth Factors (CGF) in bone regeneration techniques: a case series. *J Osseointegr* 2014;6(2):37-42.

### ABSTRACT

**Aim** Different types of biomaterials and surgical techniques are currently used for the augmentation of atrophic ridges in view of implant supported restorations. The aim of this study was to clinically and histologically evaluate the combination of Concentrated Growth Factors (CGF) and xenogeneic bone in vertical and/or horizontal ridge augmentation.

**Materials and methods** Seven patients (3 males and 4 females), who required oral implant and ridge augmentation surgery, were selected: 3 implants were placed during the surgery and 4 implants were inserted 4 months later, in order to allow complete graft integration. All implants were loaded after a 4-month healing time. The following parameters were assessed: a) the capability of CGF to permeate the bone scaffold; b) the degree of bone regeneration; c) the clinical success rate.

**Results** The results obtained showed that: a) with the used medical device porous bone scaffolds can be effectively permeated by the CGF; b) the permeated grafting material resulted in effective bone regeneration, as confirmed by histomorphometric analysis; c) all implants were successfully in function at the 12 months follow-up.

**Conclusion** This technique can be safely performed in the dental office under local anesthesia, so it can be considered a viable option in bone regeneration surgery.

**KEYWORDS** Bone regeneration; CGF; Horizontal ridge augmentation; Scaffold blocks; Vertical ridge augmentation.

### INTRODUCTION

The rehabilitation of partially and totally edentulous arches with osseointegrated implants is now a common practice supported by reliable long-term results (1-11). In some cases the anatomy of the edentulous ridges may be unfavourable to implant placement: large bone defects, in fact, may make the insertion of implants difficult or impossible due to insufficient bone volume. Currently, major bone defects can be filled using different surgical techniques (12, 13) in combination with the use of autografts, allografts and xenografts, as well as different types of natural and synthetic biomaterials (6,14-17). The grafting procedure using autologous bone is considered the gold standard, owing to the osteogenic capacity and the absence of antigenic response. However, it has some disadvantages, namely increased morbidity and limited availability of donor site. Therefore, biomaterials of different origin have been proposed as bone substitutes to overcome these limitations. In literature, there are several studies comparing the use of autologous bone with other bone substitutes; in particular, xenogeneic biomaterials are reported to be as clinically efficient as autologous bone, even if their biological behaviour can significantly vary according to their origin (porcine, bovine, equine) and their macro- and micro-structure, thus affecting the bone regeneration process (17-23).

In the last years the use of platelet preparations, alone or in combination with other biomaterials, has proven to be a good regenerative option (24-25). Concentrated Growth Factors (CGF) are platelet concentrates containing autologous growth factors together with blood cells (26) that are reported to promote bone regeneration (27). As other platelet concentrates, CGF are isolated from whole blood samples with a simple and standardized protocol by means of a specific centrifuge, without the addition of exogenous substances. The main characteristic of CGF is

its consistency: it is an organic matrix rich in fibrin and, therefore denser than other platelet concentrates; this characteristic makes it suitable for different uses, alone or in combination with other materials, as filler or as a scaffold for synthetic and biological membranes. CGF can be mechanically mixed with different biomaterials, in the form of granules or blocks, using a special medical device. The purpose of the present study was to standardize a surgical technique, that can be performed in any dental practice under local anaesthesia, through the assessment of the following parameters: a) ability of xenogeneic bone blocks to be permeated by CGF; b) amount of bone regeneration; c) clinical success rate.

## MATERIALS AND METHODS

### Patient selection and surgical planning

In this study, 7 patients (3 males and 4 females aged between 45 and 63 years old) who needed oral surgery rehabilitation (4 in the maxilla and 3 in the mandible) were enrolled. Patients were selected according to the following inclusion criteria: patients in good general health and not heavy smokers (<10 cigarettes/day), who gave written informed consent for implant surgery. Subjects who had absolute contraindications to surgery were excluded. Two operators (EG and AP) performed surgeries: the treatments described were performed in their private practices, after a written informed consent was signed by each patient, following the Declaration of Helsinki principles. The materials and equipment used have been marketed for a long time, and there is no conflict of interest on the part of the authors.

One month before surgery each patient underwent scaling and root planing, combined with motivational sessions and oral hygiene education. Radiographic evaluation was performed before surgery, 1 month after surgery and every 6 months after prosthetic loading.

Patients were divided into two groups: in Group 1 (3 subjects) implants (SPI; Alpha-Bio Tec, Israel - Ankylos; Dentsply, Bologna, Italy) were placed during oral surgery

session (simultaneous implants); in Group 2 (4 subjects) implants (SPI; Alpha-Bio Tec, Israel - Ankylos; Dentsply, Bologna, Italy) were placed 4 months after surgery (delayed implants), when full graft integration was achieved. Two implants diameters were selected (3.3 and 3.5 mm), in order to be easily contained in the graft, and their length was proportionate to the anatomical site. In addition, a pre-surgical 3D measurement was performed to evaluate bone volume and quality.

### Preparation of CGF and permeation process of biomaterial

Venous blood samples (4 samples of 9 ml) were obtained from each patient. Each blood sample was centrifuged by means of a specific device (Medifuge MF200; Silfradent srl, Italy) in order to obtain the CGF (Fig. 1), according to the manufacturer's instruction. For the permeation process, the whole CGF obtained was mechanically mixed with the blocks of collagenated xenogeneic biomaterial (Sp-Block OsteoBiol® and C-Block; Tecnos, Italy) using the Round Up device (Silfradent srl, Italy). The permeated blocks (Fig. 2) were then placed: Sp-square blocks were used for horizontal ridge augmentation, whereas C-cylinder blocks were used for vertical bone augmentation.

### Surgical procedure

Local anaesthesia (plexus block) was administered (articaine 4% with epinephrine 1:100,000). A full thickness flap was raised to allow site evaluation and selection of bone block size. Bone decortication in the recipient site was performed to help graft integration. After preparing the surgical site, the Sp-Block or C-Block combined with CGF was placed and fixed with osteosynthesis screws (Fig. 3A, 4A) or by means of the implant itself, depending on the simultaneous or delayed protocol used. Flap mobilization was achieved with periosteal incisions; marginal gaps were filled with slow resorbable material, mixed with CGF. Finally, a resorbable membrane (OsteoBiol® Evolution; Tecnos, Coazze, Italy) was placed (Fig. 3B) and the site was sutured without tension. The patient was instructed to apply ice during




FIG. 1 CGF preparation using the centrifuge device. A. Centrifuge device; B. Tube loading and balancing; C. Tubes after centrifugation; D. CGF isolation.

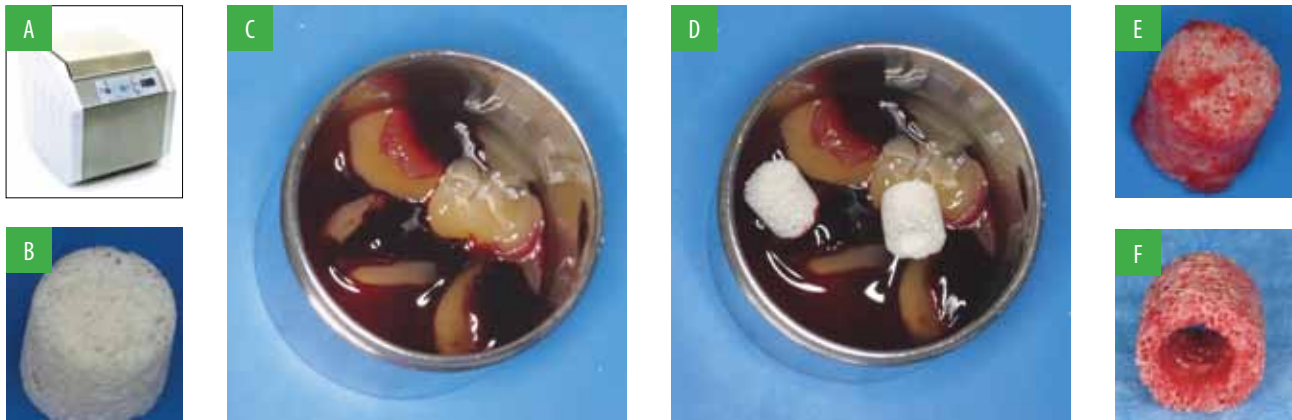


FIG. 2 Permeation of C-Block using Round Up device. A. Round Up; B. Scaffold; C. Placement of CGF in the holder of Round Up; D. Placement of the scaffold in the holder of Round Up; E-F. C-Block permeated with CGF.

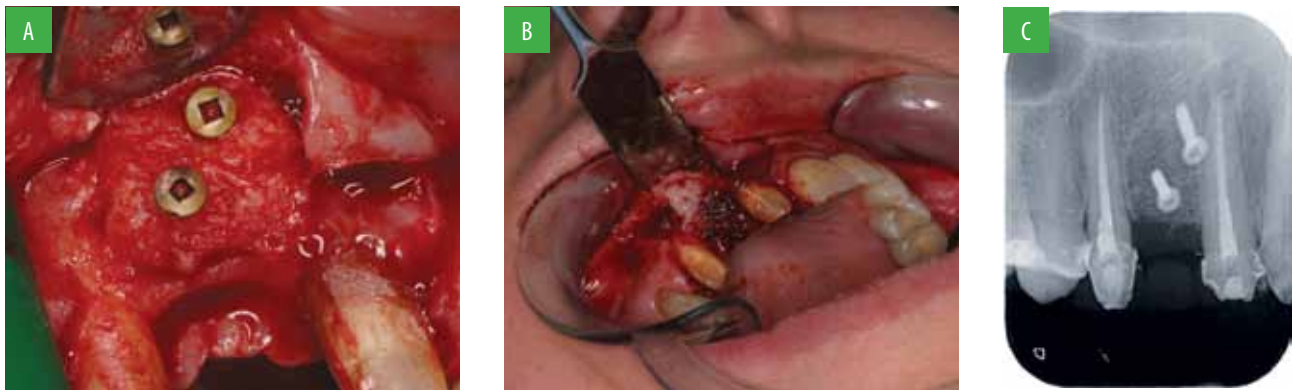


FIG. 3 A. Placement and stabilization of SP-Block; B. Protection of the graft with the membrane; C. Radiographic examination of the bone block.

the first 12 hours and to follow a soft diet throughout the first month; antibiotics and nonsteroidal anti-inflammatory drugs (NSAIDs) were administered. Loading of simultaneous implants with temporary prostheses, and subsequently with permanent ceramic prostheses, was achieved about 4 months after implant placement. Delayed implants were inserted after complete graft integration (about 4 months after surgery); during preparation of the implant site a bone core was harvested for histomorphometric analysis, using a 2 mm trephine bur before the final drill to insert the implant (Fig. 5); loading was achieved 4 months after implant placement.

### Clinical and histomorphometric analysis

Treatment success was evaluated through both clinical examination (lack of mobility and pain, no bleeding on probing) and radiographic examination to assess bone structure (Fig. 3C, 4B, 4C).

Histomorphometric analysis of the bone cores obtained during implant site preparation was performed by the Department of Anatomy and Physiopathology, University of Brescia, Italy. All bone samples were fixed in 10%

neutral buffered formalin, decalcified with Osteodec (Bio-Optica, Italy) and paraffin-embedded according to standard procedures; 7  $\mu$ m thick sections were cut by microtome and stained with haematoxylin and eosin (Bio-Optica, Italy) (Fig. 6). The histomorphometric analysis was performed using an optical light microscope (Olympus, Germany) by operators blinded to the assigned group. Digital images of slices (five fields for each sample) were analyzed by means of a specific software (Image Pro-Plus 4.5.1, Immagini e Computer, Italy), able to quantify the ratio of newly formed bone (NB), non-mineralized tissue (n-MT) and residual graft (RG). Histomorphometric data were reported as mean  $\pm$  standard error of the mean (SEM).

### RESULTS

The histological findings showed that porous bone blocks could effectively be permeated by CGF, using the Round Up medical device (Fig. 7).

Histomorphometric analysis of bone sample (Fig. 8) showed the presence of trabeculae of newly formed

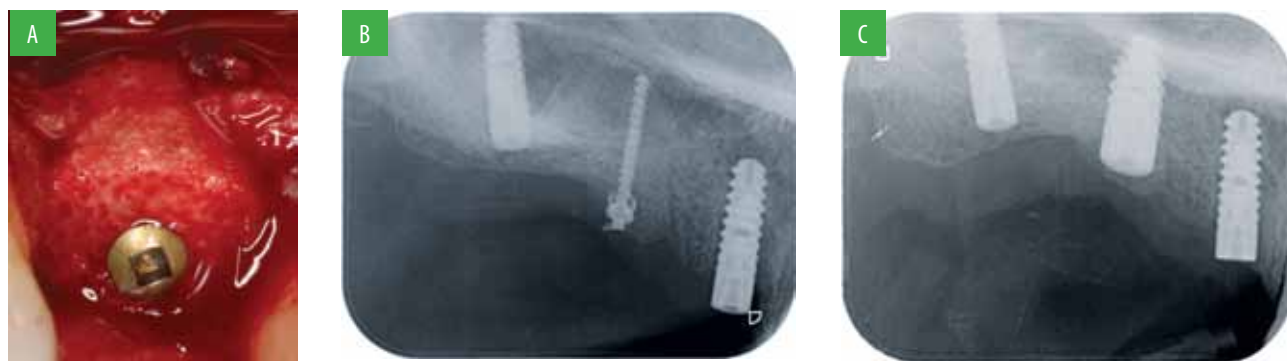

FIG. 4 A. Placement and stabilization of C-Block; B. Radiographic examination of the bone block; C. Radiographic examination of the implant.

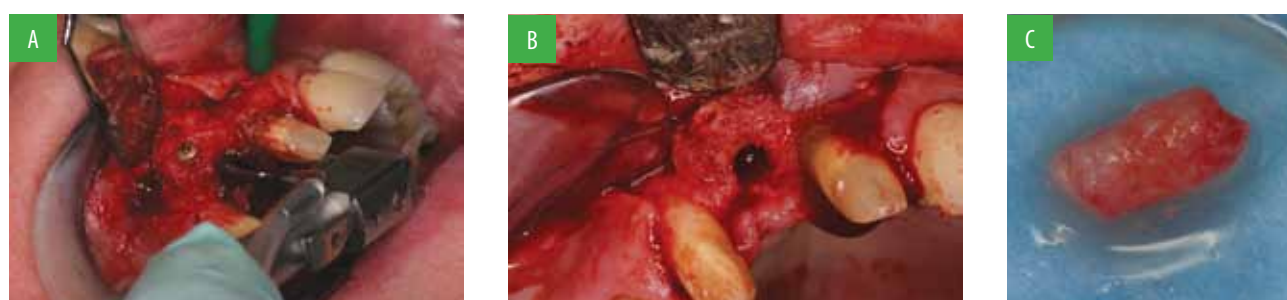
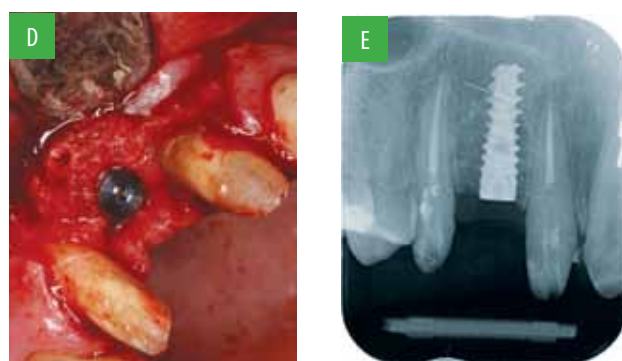

FIG. 5 A. Implant site preparation using a core drill; B. Implant site; C. Bone core;



D. SPI implant (Alpha Bio) placement; E. Radiographic examination of the implant.

bone (NB), together with non-mineralized tissue (n-MT), and residual bone graft (RBG). Quantitative data of NB, n-MT and RBG are shown in Table 1. Concerning clinical success rate, all implants were successfully in function after a 12-month follow-up. No implant mobility, no pain nor bleeding on probing were detected. Radiographic examinations also showed good implant integration in both types of graft. In addition, the specific shape of the used implants ensured significant implant stability, although only the apical third of them was used as anchorage during the healing phase.

## DISCUSSION

Different techniques and biomaterials are now available for the augmentation of atrophic ridges before implant surgery (1-25); however, an ideal procedure does not exist. The oral surgeon has to choose the best

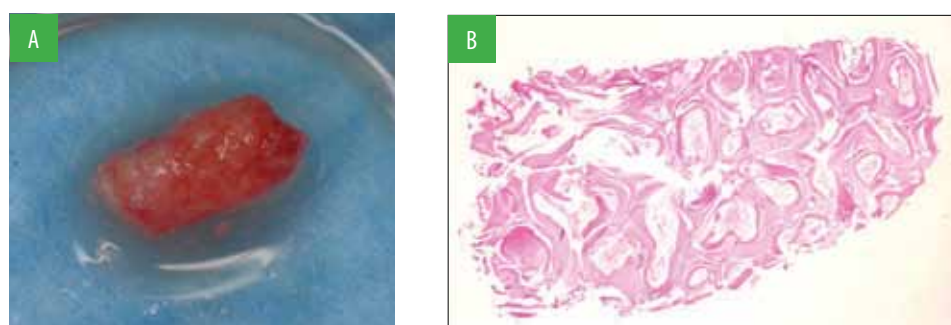


FIG. 6 A. Bone core; B. Histological analysis: haematoxylin-eosin staining. 2X magnification.

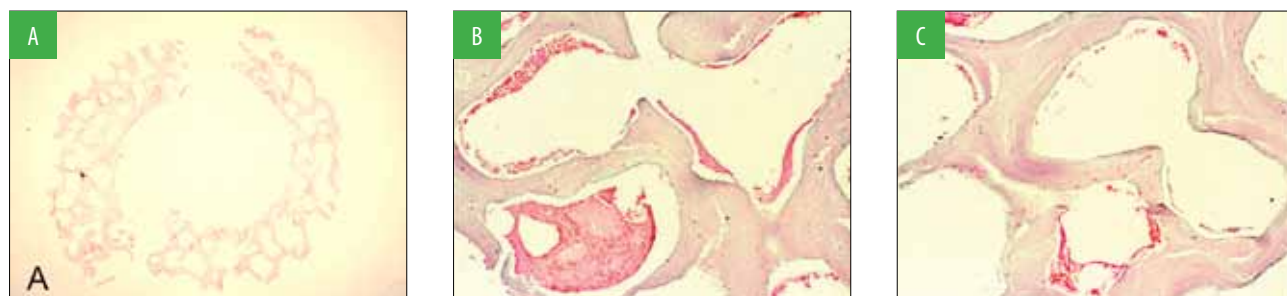


FIG. 7 A Histological aspect of C-Block permeated with CGF, 1.25 magnification; B-C Enlargement - 10X magnification (arrows indicate CGF). Haematoxylin-eosin staining.

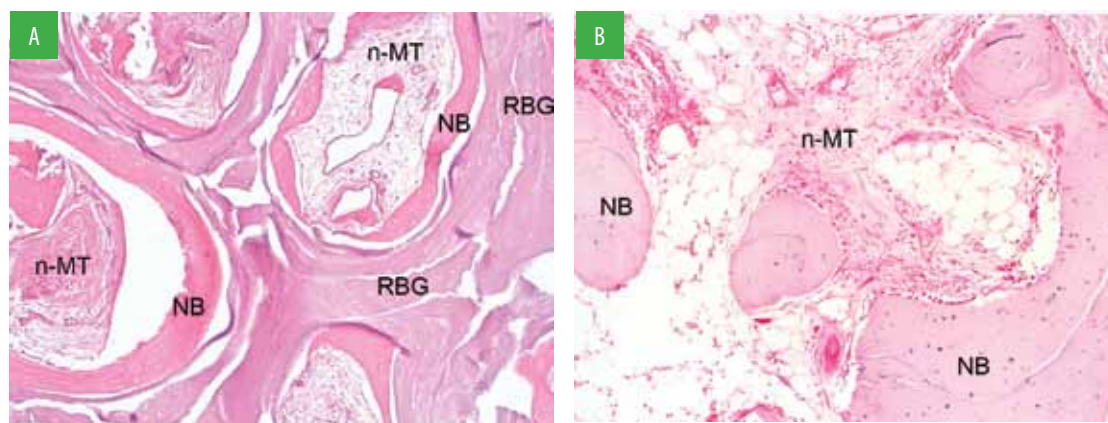


FIG. 8 Histo-morphometric analysis. Haematoxylin-eosin staining. A. Vertical ridge augmentation using C-Block. 10X magnification. B. Horizontal ridge augmentation using SP-Block. 10X magnification.

	NB (%±SEM)	N-MT (%±SEM)	RG (%±SEM)
Vertical augmentation	30.40 +/- 0.57	34.52 +/- 1.42	35.08 +/- 1.42
Horizontal augmentation	46.59 +/- 3.28	48.61 +/- 2.49	2.73 +/- 0.87

TABLE 1 Histomorphometric analysis of the percentage of New Bone (NB); non-Mineralized Tissue (n-MT), Residual Graft (RG) expressed as mean ± standard error of the mean (SEM).

technique for the specific case and, in particular, the one that allows to limit surgical risks, costs and time (28-31). Several types of biomaterials are used in combination with different surgical techniques and many data support the efficacy of bone substitutes, such as xenogeneic bone derived biomaterials (of bovine, equine, porcine origin) (15-20,32-34). Beside these biomaterials, the use of different preparations of platelet concentrates has also been evaluated with promising results (24,25,27,35).

The results of the present study showed that the Round Up device could effectively permeate bone blocks with CGF. This procedure allowed to add to the mechanical properties of the scaffold the biological activity of the CGF; therefore, it represents an effective method for

bone regeneration, where CGF contributes to a better and more rapid healing of both soft and hard tissues, confirming the bone regenerative effect of platelet concentrates.

The bone regeneration efficacy of this scaffold was also proved by histomorphometric analysis of the bone cores obtained during implant site preparation, which, clearly demonstrated that an adequate amount of regenerated bone, necessary for the correct integration of the implant, was present in the grafted sites 4 months after surgery; moreover, these data were supported by radiological examination and by the absence of significant clinical alterations. However, further controlled studies, with greater numbers of patients, are necessary to validate the present results.

### CONCLUSION

The technique proposed in the present study can be safely performed in the dental office under local anesthesia, and can be considered a viable option in bone regeneration surgery.

Future scientific researches should be focused on the study of heterologous materials, which can completely replace the use of autogenous bone, and their combination with platelet concentrates that promote bone regeneration.

## REFERENCES

- Arvidson K, Bystedt H, Frykholm A, von Konow L, Lothigius E. Five-year prospective follow-up report of Astra tech implant system in the treatment of edentulous mandibles. *Clin Oral Implants Res* 1998;9:225-34.
- Carlsson GE, Omar R. The future of complete dentures in oral rehabilitation. A critical review. *J Oral Rehabil* 2010;37:143-56.
- Esposito M, Murray-Curtis L, Grusovin MG, Coulthard P, Worthington HV. Interventions for replacing missing teeth: different types of dental implants. *Cochrane Database Syst Rev* 2007;(4):CD003815.
- Javed F, Ahmed HB, Crespi R, Romanos GE. Role of primary stability for successful osseointegration of dental implants: Factors of influence and evaluation. *Interv Med Appl Sci* 2013;5:162-7.
- Leonhardt A, Grondahl K, Bergstrom C, Lekholm U. Long-term follow-up of osseointegrated titanium implants using clinical, radiographic and microbiological parameters. *Clin Oral Implants Res* 2002;13:127-32.
- Mamalis A, Markopoulou K, Kaloumenos K, Analitis A. Splinting osseointegrated implants and natural teeth in partially edentulous patients: a systematic review of the literature. *J Oral Implantol* 2012;38:424-34.
- Margonar R, dos Santos PL, Queiroz TP, Marcantonio E. Rehabilitation of atrophic maxilla using the combination of autogenous and allogeneic bone grafts followed by protocol-type prosthesis. *J Craniofac Surg* 2010;21:1894-6.
- Meyle J, Gersok G, Boedeker RH, Gonzales JR. Long term analysis of osseointegrated implants in non-smoker patients with a previous history of periodontitis. *J Clin Periodontol* 2014 doi: 10.1111/jcpe.12237 (In Press).
- Parithimarkalaignan S, Padmanabhan TV. Osseointegration: An Update. *J Indian Prosthodont Soc.* 2013;13:2-6.
- Warreth A, McAleese E, McDonnell P, Slami R, Guray SM. Dental implants and single implant-supported restorations. *J Ir Dent Assoc* 2013;59:32-43.
- Weber HP, Crohin CC, Fiorellini JP. A five-year clinical and radiographic study of non submerged dental implants. *Clin Oral Impl Res* 2000;11:144-53.
- Kan JY, Lozada JL, Goodacre CJ et al. Mandibular fracture after endosseous implant placement in conjunction with inferior nerve transposition: a patient treatment report. *Int. J Oral Maxillofac Implants* 2006;21:86-93.
- Felice P, Checchi V, Pistilli R, Scarano A, Pellegrino G, Esposito M. Bone augmentation versus 5 mm dental implants in posterior atrophic jaws. Four month post loading results from a randomized controlled clinical trial. *Eur J Oral Implantol* 2009;2:267-81.
- Acocella A, Sacco R, Niardi P, Agostini T. Early implant placement in bilateral sinus floor augmentation using iliac bone block grafts in severe maxillary atrophy: a clinical, histological, and radiographic case report. *J Oral Implantol* 2009;35:37-44.
- Artese L, Piattelli A, Di Stefano DA, Piccirilli M, Pagnutti S, D'Alimonte E, Perrotti V. Sinus lift with autologous bone alone or in addition to equine bone: an immunohistochemical study in man. *Implant Dent* 2011;20:383-8.
- Buffoli B, Boninsegna R, Rezzani R, Poli PP, Santoro F, Rodella LF. Histomorphometrical evaluation of fresh frozen bone allografts for alveolar bone reconstruction: preliminary cases comparing femoral head with iliac crest grafts. *Clin Implant Dent Relat Res* 2013;15:791-8.
- Di Stefano DA, Artese L, Iezzi G, Piattelli A, Pagnutti S, Piccirilli M, Perrotti V. Alveolar ridge regeneration with equine spongy bone: a clinical, histological, and immunohistochemical case series. *Clin Implant Dent Relat Res* 2009;11:90-100.
- Di Stefano DA, Cazzaniga A, Andreasi Bassi M, Ludovichetti M, Ammirabile G, Celletti R. The use of cortical heterologous sheets for sinus lift bone grafting: a modification of Tulasne's technique with 7-year follow-up. *Int J Immunopathol Pharmacol* 2013;26:549-56.
- Felice P, Marchetti C, Piattelli A, Pellegrino G, Checchi V, Worthington H, et al. Vertical ridge augmentation of the atrophic posterior mandible with interpositional block graft: bone from the iliac crest versus bovine anorganic bone. *Eur J Oral Implantol* 2008; 1:183-98.
- Felice P, Marchetti C, Iezzi G, Piattelli A, Worthington H, Pellegrino G, et al. Vertical ridge augmentation of the atrophic posterior mandible with interpositional block graft: bone from the iliac crest vs bovine anorganic bone. Clinical and histological result up to one year after loading from a randomized-controlled clinical trial. *Clin Oral Implants Res* 2009;20:1386-93.
- Felice P, Piattelli A, Iezzi G, Degidi M, Marchetti C. Reconstruction of an atrophied posterior mandible with the inlay technique and inorganic bovine bone block: a case report. *Int J Periodontics Restorative Dent* 2010;30:583-91.
- Merli M, Migani M, Esposito M. Vertical ridge augmentation with autogenous bone graft: resorbable barriers supported by osteosynthesis plates versus titanium-reinforced barriers. A preliminary report of a blinded, randomized controlled clinical trial. *Int J Oral Maxillofac Implants* 2007;22:373-82.
- Tetè S, Vinci R, Zizzari VL, Zara S, La Scala V, Cataldi A, Gherlone E, Piattelli A. Maxillary sinus augmentation procedures through equine-derived biomaterial or calvaria autologous bone: immunohistochemical evaluation of OPG/RANKL in humans. *Eur J Histochem* 2013;57:e10.
- Del Corso M, Vervelle A, Simonpieri A, Jimbo R, Inchingolo F, Sammartino G, Dohan Ehrenfest DM. Current knowledge and perspectives for the use of platelet-rich plasma (PRP) and platelet-rich fibrin (PRF) in oral and maxillofacial surgery part 1: Periodontal and dentoalveolar surgery. *Curr Pharm Biotechnol* 2012;13:1207-30.
- Simonpieri A, Del Corso M, Vervelle A, Jimbo R, Inchingolo F, Sammartino G, Dohan Ehrenfest DM. Current knowledge and perspectives for the use of platelet-rich plasma (PRP) and platelet-rich fibrin (PRF) in oral and maxillofacial surgery part 2: Bone graft, implant and reconstructive surgery. *Curr Pharm Biotechnol* 2012;13:1231-56.
- Rodella LF, Favero G, Boninsegna R, Buffoli B, Labanca M, Scari G, Sacco L, Batani T, Rezzani R. Growth factors, CD34 positive cells, and fibrin network analysis in concentrated growth factors fraction. *Microsc Res Tech* 2011;74:772-7.
- Sohn DS, Heo JU, Kwak DH, Kim DE, Kim JM, Moon JW, Lee JH, Park IS. Bone regeneration in the maxillary sinus using an autologous fibrin-rich block with concentrated growth factors alone. *Implant Dent* 2011;20:389-95.
- Felice P, Pistilli R, Lizio G, Pellegrino G, Nisii A, Marchetti C. Inlay versus onlay iliac bone grafting in atrophic posterior mandible: a prospective controlled clinical trial for the comparison of the two techniques. *Clin Implant Dent Relat Res* 2009;11:69-82.
- Chiapasco M, Romeo E, Casentini P, Rimondini L. Alveolar distraction osteogenesis vs. vertical guided bone regeneration for the correction of vertically deficient edentulous ridges: a 1-3 years prospective study on humans. *Clin Oral Implants Res* 2004;15:82-95.
- Chiapasco M, Zaniboni M, Rimondini L. Autogenous onlay bone graft vs. alveolar distraction osteogenesis for the correction of vertically deficient edentulous ridges: a 2-4 years prospective study on humans. *Clin Oral Implants Res* 2007;18:432-40.
- Bianchi A, Felice P, Lizio G, Marchetti C. Alveolar distraction osteogenesis versus inlay bone grafting in posterior mandibular atrophy: a prospective study. *Oral Surg Oral Med Oral Pathol Oral Radiol Endod* 2008; 105:282-92.
- Perrotti V, Nicholls BM. Resorption pattern of a porcine-derived bone substitute. *J Osseointegr* 2009; 1: 22-8.
- Scarano A, Piattelli A, Assenza B, Quaranta A, Perrotti V, Piattelli M, Iezzi G. Porcine bone used in sinus augmentation procedures: a 5-year retrospective clinical evaluation. *J Oral Maxillofac Surg* 2010;68:1869-73.
- Scarano A, Piattelli A, Perrotti V, Manzon L, Iezzi G. Maxillary sinus augmentation in humans using cortical porcine bone: a histological and histomorphometrical evaluation after 4 and 6 months. *Clin Implant Dent Relat Res* 2011; 13:13-8.
- Honda H, Tamai N, Naka N, Yoshikawa H, Myoui A. Bone tissue engineering with bone marrow-derived stromal cells integrated with concentrated growth factor in *Rattus norvegicus* calvaria defect model. *J Artif Organs* 2013; 16:305-15.