

Removal, after 7 years, of an implant displaced into the maxillary sinus. A clinical and histologic case report

ABSTRACT

Background The accidental displacement of dental implants into the maxillary sinus is a infrequent but possible complication in dental clinical practice. The main cause of implant displacement is the inadequate bone height in the posterior maxilla. This event usually occurs during surgery and it is more rarely reported in the post-operative period, especially at long-term follow-ups. Here a case of an implant migrated inside the maxillary sinus at the time of abutment connection and removed 7 years later is described. Postoperative recovery was uneventful.

Conclusions To the authors best knowledge, this case represents the first report concerning migration of an oral implant into the maxillary sinus removed after 7 years.

Keywords Complication, implant displacement, long-term, sinus lifting.

INTRODUCTION

Rehabilitation of partially or totally edentulous posterior maxilla with implant-supported prosthesis has become a common practice in the last few decades, with reliable long-term results (1-5). However, local conditions of the edentulous ridges may be unfavorable for implant placement. In particular, the posterior maxilla may be challenging due to both insufficient height and width of the edentulous alveolar crestal bone, and/or maxillary sinus pneumatization (6).

Indeed, when patients lose their teeth, bone shape and density change as the stimulus necessary to maintain the trophisms of such tissue disappears. As a consequence, alveolar crest begins to undergo a resorption process and the osteoclasts of the periosteum adjacent to the sinus membrane through a centrifugal bone resorption process which produces the pneumatization of the maxillary sinus. Therefore, this anatomical condition along with the low density of the maxillary bone and the apico-coronal atrophy makes it difficult to achieve primary stability (7) and may be responsible for the greater failure rate of endosseous

implants placed in the maxilla when compared to the mandible (8). It can also account for the high risk of implant displacement/migration into the maxilla, which has been only rarely reported (8-15). Implant displacement into the maxillary sinus can occur at the time of surgery (16, 17) or after a period of function; the latter event is more rare (8). It may be followed by infectious complications due to the contact of the implant with the mucosa of the sinus interior (18-20), therefore an immediate or early removal of the displaced implants is indicated. This procedure can be performed either through the implant site, or by creating a window in the anterior/lateral wall of the maxillary sinus (if the implant is displaced in the maxillary sinus) (9, 12, 21), or by means of an endoscopic nasal approach (13-15).

There is a paucity of report of actual displacement of implants in function into the maxillary sinus, and report with long term follow-up are very rare.

The aim of this article was to present an unusual case of implant migration in the maxilla towards the interior of the maxillary sinus and its removal 7 years later.

CASE REPORT

In September 2001 a 42-year-old man with a partially edentulous maxilla underwent implant placement. A total of 5 implants (4 x 13 mm) (Implant Innovations, West Palm Beach, Florida, USA) were inserted, 2 in the left and 3 in the right posterior maxilla. Four months later, at the time of abutment connection, the implant located at the site of the maxillary left first molar was accidentally pushed in the sinus.

The implant was not immediately removed. One month later, the patient was referred to the Oral Surgery Division of the Dental

Clinic, University of Chieti-Pescara (Italy) for a slight pain in the left posterior maxilla. Intraoral examination revealed an implant-supported complete fixed prosthetic rehabilitation. The patient presented a sinusitis with a light discomfort on palpation. The orthopantomography (OPT) revealed that the implant and abutment were located within the left maxillary sinus (Fig. 1). A surgical removal of the implant from the maxillary sinus was proposed to the patient; however he refused the operation. After 7 years the symptoms worsened and the patient underwent surgical intervention. Computerized Axial Tomography (CAT) scanimage revealed opacification of the left maxillary sinus with mucosal thickening, and the dental implant displaced within the sinus (Fig. 2).

Surgical procedure

Antimicrobial prophylaxis was obtained with 1 g Amoxicillin twice daily for 5 days starting 1 hour before surgery. Local anesthesia was induced by infiltration with xylocaine/epinephrine, and after a crestal incision, a full-thickness mucoperiosteal flap was elevated, exposing the anterior-lateral wall of the maxilla from the canine to the molar region. The sinus was then transilluminated to reveal its lower and anterior-posterior borders and the implant

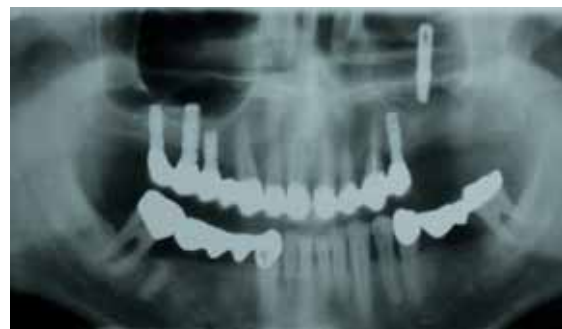

Fig. 1 Panoramic radiograph showing the implant displaced into the maxillary sinus.

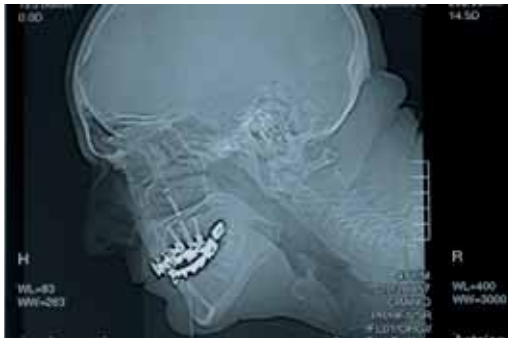

Fig. 2 X ray after the prosthetic rehabilitation. The implant and the abutment are into the sinus.

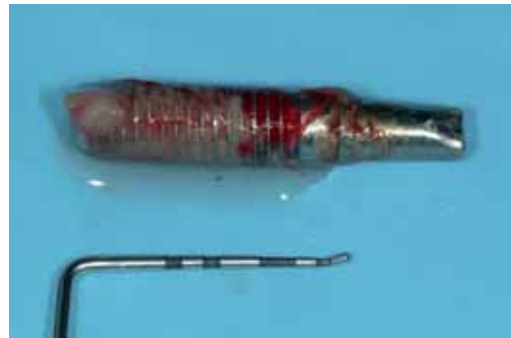

Fig. 3 The retrieved implant is surrounded by inflammatory tissue.

position. Using high-speed instrumentation under cold (4-5 °C) sterile saline irrigation a rectangular box was created in the anterior-lateral maxillary wall to ensure that the lower margin was 5 mm above the sinus floor. The implant was removed by a surgical aspirator (Fig. 3). A bone lamina (Osteobiol, Tecnos, Coazze, Turin, Italy) was used to close the lateral window of the sinus. The mucoperiosteal flap was then replaced and sutured with multiple horizontal mattress sutures.

Analgesics were prescribed for 1 week as required. Sutures were removed 2 weeks after surgery. The patient had a soft diet for 4 weeks, and oral hygiene instructions were provided.

Post-surgical visits were scheduled at monthly intervals to check the healing process. The removed implant underwent histological examination (Fig. 3).

Specimen Processing

The retrieved implant was immediately stored in 10% buffered formalin and processed for histology and histomorphometry at the Implant Retrieval Centre, Dental School, University of Chieti-Pescara (Italy) to obtain thin ground sections with the Precise 1 Automated System (Assing, Rome, Italy).

The specimen was dehydrated in an ascend-

ing series of alcohol rinses and embedded in a glycolmethacrylate resin (Technovit 7200 VLC, Kulzer, Wehrheim, Germany).

After polymerization, the specimen was sectioned longitudinally along its major axis with a high-precision diamond disc at about 150 μm and ground down to about 30 μm . Three slides were obtained. The slides were stained with acid fuchsin and toluidine blue.

The slides were observed in normal transmitted light under a Leitz Laborlux microscope (Leitz, Wetzlar, Germany).

Histological evaluation

At low magnification fibrous connective tissue with hyaline degeneration and a little inflammatory cell infiltration was present around the implant (Fig. 4). No bacteria were observed.

An extensive proliferation of the glandular structures with distinctive interstitial cyst formation could be detected in the removed sinus mucosa (Fig. 5).

The cystic structures often reached rather large proportions causing extensive folding, bulging, and thickening of the sinus membrane.

Further pathologic changes included hyaline degeneration of the connective tissue fibers of the tunica propria and thrombosis (Fig. 5).


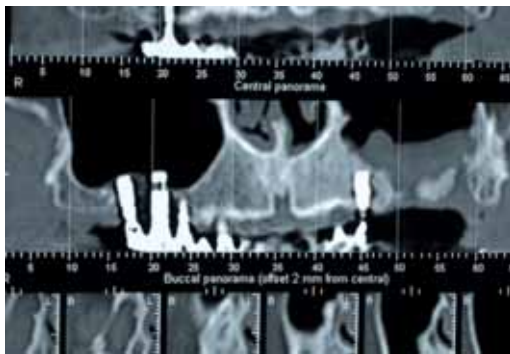


Fig. 4 At low magnification it is possible to observe the presence of fibrous connective tissue with hyaline degeneration and a small inflammatory cell infiltrate around the implant. Acid fuchsin-toluidine blue 6 X.



Follow-up

Seven months after the implant removal from the maxillary sinus a CAT scan image revealed normal mucosal thickness and no opacification of the left maxillary sinus (Fig. 6).

DISCUSSION

In recent years, placement of endosseous implants in the posterior maxilla has become a standard procedure; however, complications are possible. Among these there is implant displacement inside the maxillary sinus, that may cause infectious complications as a consequence of the close contact of the implant with the sinus mucosa (22, 23). Local infection around the implant is the most common effect, and may cause extensive resorption of the surrounding bone. For this reason, implants placed close to the maxillary sinus offer a

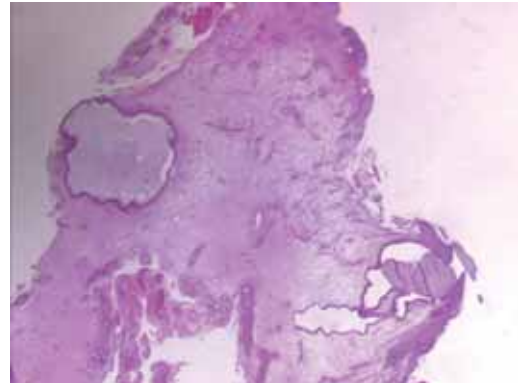


Fig. 5 Hyperplastic and degenerative changes in the sinus mucosa including mucous-serous gland proliferation and pseudocyst formation can be observed. Inflammatory cell infiltrate is present in the endosteal spaces. Acid fuchsin-toluidine blue 100 X.

Fig. 6 Seven months after implant removal from the maxillary sinus a computer tomography scan image shows normal mucosal thickening and no opacification of the left maxillary sinus.

route for infection from the oral cavity to the sinus.

Generally, foreign bodies in the paranasal sinuses should be removed as they may determine inflammation/sinusitis by disturbing or blocking the mucociliary clearance (11, 19, 20). Furthermore, they can determine aspergillosis or even cancer (18, 24-26).

The swelling of the mucosa lining the sinus affects the ostiomeatal complex by reducing the size of the maxillary ostium. This series of events are responsible of a sinus disorder as described by Regev et al. (27), Ueda and Kaneda (22), and Quiney et al. (23). Only in a few cases the patient may remain asymptomatic, as in the present case, and in those reported by Iida et al. (9) and Raghoobar and Vissink (11) where the implants migrated into the maxillary sinus did not determine any inflammatory/infectious reaction.

Theories to explain the displacement of the

implants into the maxillary sinus include changes in intra-sinus and nasal pressures that generate a suction effect, bone destruction secondary to an infection at the implant site before or after its implantation, or an improper distribution of occlusal forces (8).

The treatment depends on the symptoms of maxillary sinusitis and is aimed at the re-establishment of the drainage and ventilation of the antrum (28). Iida et al. (9) opened the wall of the sinus under local anaesthesia and Pagella et al. (29) reported the intraoral endoscopic extraction of a metallic foreign body from the maxillary sinus. Regev et al. (27) used the Caldwell-Luc operation in some cases and sometimes retrieved the implant through the intraoral preparation site. A combination of a medical and surgical approach is generally required for the treatment of odontogenic sinusitis. Elimination of the source of the infection is necessary to prevent recurrence of the sinusitis.

When the displacement of an implant into the sinus has occurred, removal of the implant is mandatory.

In conclusion, the displacement of an implant into the sinus is an uncommon, but possible event. Therefore, it is important to accurately evaluate the specific characteristics of the patient and receptor site before planning an implant-supported rehabilitation in the vicinity of natural cavities (8). This is the first reported case of an implant displaced into the maxillary sinus and retrieved after 7 years.

ACKNOWLEDGMENTS

This work was partially supported by the National Research Council (CNR), Rome, Italy, by the Ministry of Education, University and Research (MIUR), Rome, Italy.

REFERENCES

1. Albrektsson T, Zarb G, Worthington P, Eriksson AR. The long-term efficacy of currently used oral implants: a review and proposed criteria of success. *Int J Oral Maxillofac Implants* 1986;1:1-25.
2. Lekholm U, van Steenberghe D, Herrmann I, Bolender C, Folmer T, Gunne J, Henry P, Higuchi K, Laney WR. Osseointegrated implants in the treatment of partially edentulous jaws: a prospective 5-year multicenter study. *Int J Oral Maxillofac Implants* 1994;9:627-635.
3. Buser D, Mericske-Stern R, Bernard JP, Behneke A, Behneke N, Hirt HP, Belser UC and Lang NP. Long-term evaluation of nonsubmerged ITI implants. Part I: 8-year life table analysis of a prospective multicenter study with 2359 implants. *Clin Oral Implants Res* 1997;8:161-172.
4. Arvidson K, Bystedt H, Frykholm A, von Konow L, Lothigius E. Five-year prospective follow-up report of astra tech implant system in the treatment of edentulous mandibles. *Clin Oral Implants Res* 1998;9:225-234.
5. Leonhardt A, Grondahl K, Bergstrom C, Lekholm U. Long-term follow-up of osseointegrated titanium implants using clinical, radiographic and microbiological parameters. *Clin Oral Implants Res* 2002;13:127-132.
6. Furst G, Gruber R, Tangl S, Zechner W, Haas R, Mailath G, Sanroman F, Watzek G. Sinus grafting with autogenous platelet-rich plasma and bovine hydroxyapatite. A histomorphometric study in minipigs. *Clin Oral Impl Res* 2003;14:500-508.
7. Adell R, Lekholm U, Rockler B, Brånemark P-I. A 15-year study of osseointegrated implants in the treatment of the edentulous jaw. *Int J Oral Surg* 1981;10:387-416.
8. Galindo P, Sánchez-Fernández E, Avila G, Cutando A, Fernandez JE. Migration of implants into the maxillary sinus: two clinical cases. *Int J Oral Maxillofac Implants*. 2005;20:291-5.
9. Iida S, Tanaka N, Kogo M, Matsuya T. Migration of a dental implant into the maxillary sinus. A case report. *Int J Oral Maxillofac Surg*. 2000;29:358-9.
10. Haben CM, Balys R, Frenkiel S. Dental implant

- migration into the ethmoid sinus. *J Otolaryngol* 2003;32:342-344.
11. Raghoobar GM, Vissink A. Treatment for an endosseous implant migrated into the maxillary sinus not causing maxillary sinusitis: case report. *Int J Oral Maxillofac Implants*. 2003;18:745-9.
 12. Nakamura N, Mitsuyasu T, Ohishi M. Endoscopic removal of a dental implant displaced into the maxillary sinus: technical note. *Int J Oral Maxillofac Surg* 2004;33:195-197.
 13. El Charkawi HG, El Askary AS, Ragab A. Endoscopic removal of an implant from the maxillary sinus: a case report. *Implant Dent* 2005;14:30-35.
 14. Kim JW, Lee CH, Kwon TK, Kim DK. Endoscopic removal of a dental implant through a middle meatal antrostomy. *Br J Oral Maxillofac Surg* 2007;45:408-409.
 15. Kitamura A. Removal of a migrated dental implant from the maxillary sinus by transnasal endoscopy. *Br J Oral Maxillofac Surg* 2007;45:410-411.
 16. Felisati G, Lozza P, Chiapasco M, Borloni R. Endoscopic removal of an unusual foreign body in the sphenoid sinus: an oral implant. *Clin Oral Implants Res*. 2007;18:776-80.
 17. Guler N, Delilbasi C. Ectopic dental implants in the maxillary sinus. *Quintessence Int*. 2007;38:238-9.
 18. Kobayashi A. Asymptomatic aspergillosis of the maxillary sinus associated with foreign body of endodontic origin- report of a case. *Int J Oral Maxillofac Surg* 1995;24:243-244.
 19. Scorticati MC, Raina G, Federico M. Cluster-like headache associated to a foreign body in the maxillary sinus. *Neurology* 2002;59:643-644.
 20. Sugiura N, Ochi K, Komatsuzaki Y. Endoscopic extraction of a foreign body from the maxillary sinus. *Otolaryngol Head and Neck Surgery* 2004;130:279-280.
 21. Biglioli F, Goisis M. Access to the maxillary sinus using a bone flap on a mucosal pedicle: preliminary report. *J CranioMaxillofac Surgery* 2002;30:155-159.
 22. Ueda M, Kaneda T. Maxillary sinusitis caused by dental implants: report of two cases. *J Oral Maxillofac Surg* 1992;50:285-287.
 23. Quiney RE, Brimble E, Hodge M. Maxillary sinusitis from dental osseointegrated implants. *J Laryngol Otol* 1990;104:333-334.
 24. Birnmeyer G. On late sequelae of metallic foreign bodies in the region. Of the paranasal sinuses. *Z Laryngol Rhinol Otol*. 1963;42:778-785.
 25. Legent F, Billet J, Beauvillain C, Bonnet J, Miegerville M. The role of dental canal fillings in the development of aspergillus sinusitis. A report of 85 cases. *Arch Otorhinolaryngol* 1989;246:318-320.
 26. De Foer C, Fossion E, Vaillant JM. Sinus aspergillosis. *J Craniomaxillofac Surg* 1990;18:33-40.
 27. Regev E, Smith RA, Perrott DH, Pogrel MA. Maxillary sinus complications related to endosseous implants. *Int J Oral Maxillofac Implants* 1995;10:451-461.
 28. Stammberger H. Endoscopic endonasal surgery. Concepts in treatment of recurring rhinosinusitis. Part I. Anatomic and pathophysiologic considerations. Part II. Surgical technique. *Otolaryngol Head Neck Surg* 1986;94:143-56.
 29. Pagella F, Emanuelli E, Castelnuovo P. Endoscopic extraction of a metal foreign body from the maxillary sinus. *Laryngoscope* 1999;109:339-42.