

Immediate loading of single tooth: case report and review of the literature

ABSTRACT

Aim This was to report a case of immediate loading of a single tooth implant analyzing aesthetic and functional outcomes; a review of the recent literature on the outcomes of immediately loaded single tooth implants is presented, reporting survival rates and providing a classification about success rates of each implant type, in order to define remaining questions requiring further investigation in future researches.

Materials and methods A case of single tooth replacement and immediate loading with switching platform technique is reported. Moreover 78 scientific texts were selected with the key words "immediate loading single tooth". Of these only 45 articles specifically analyzed single tooth immediately loaded dental implant; 16 of 45 were available in full text and were therefore investigated.

Results The immediate loading of dental implants is well documented in the literature. Several clinical trials show that overall implant survival and success rates are influenced by parameters such as implant design, surface characteristic, bone properties and bone augmentation, implant area placement (upper or lower jaw) and postextraction conditions. However, in single tooth replacement with immediate loading aesthetics (especially in the front area) and functionality (posterior area of the jaw) must be considered.

Conclusion This case report and the literature review demonstrated that scientific documentation of implant survival influenced by timing of loading is rather debated. Most of the reported outcome analyses primarily focus on implant survival and follow up. Future researches should analyze how the immediate loading can influence implant success.

Keywords Single tooth, immediate load, treatment outcomes.

INTRODUCTION

Several recently published studies have focused on treatment outcomes of implant rehabilitation and how they can be affected by implant design and surface characteristics, bone properties and bone augmentation, area of implant placement, implant length and diameter and immediate loading. All these parameters are critical in implant treatment.

In this paper the most significant publications on immediate loading of single tooth implants will be reviewed chronologically on order to report survival rates. Moreover, the aesthetic and functional outcomes of this treatment are analysed by means of a case report of immediate loading of a single tooth implant.

LITERATURE REVIEW

For this review 78 scientific texts were selected with the key words "immediate loading single tooth". Of these only 45 articles specifically analyzed single tooth immediately loaded dental implants; 16 out of 45 papers were available in full text and were therefore reviewed.

Gomez et al. published (1) in 1998 the

first case report of immediate loading on single tooth. Specifically, authors analyzed the clinical aspects of the immediate loading of a single hydroxyapatite-coated threaded root form implant. This case described a new surgical concept and a technique to fabricate screw-retained provisional crowns for immediate loading of free-standing single tooth implants. Authors concluded that further clinical and histologic studies were necessary in order to promote routine clinical application of this technique.

An 18 months' follow-up clinical pilot study on immediate loading of single tooth Brånemark implants was published in 2000 by Ericsson et al. (2). Clinical and radiographic examinations were performed to evaluate the treatment outcome of single tooth replacements with artificial crowns retained to implants inserted according to a one stage surgical procedure and immediate loading (Experimental Group, EG) in comparison to the original two stage concept (Control Group, CG). EG comprised 14 patients and the CG 8 patients, all with single tooth losses anterior to the molars. In the EG a temporary crown was connected to the implant within 24 hours following fixture placement. No fixture losses were recorded in the CG and all implants in this group were stable at the follow-ups. At the 6-month and 18-month observation intervals all patients were radiographically examined: the analysis of the radiographs showed that during the 12-months observation period the mean change of bone support was about 0.1 mm in both EG and CG.

Proussaefs and Lozada published in 2001(3) an investigation on the immediate loading of single root form implants with the use of a custom acrylic stent. The article described the technique for fabricating a provisional screw-retained restoration for immediate loading of single implants. Authors

concluded that immediate loading of single implants technique should be used cautiously, since data from other clinical studies showed that the survival rate of immediately loaded implant was significantly lower than that of implants placed according to the well documented two stage technique.

Chaushu et al published in 2001 (4) a clinical report to compare the clinical success of immediately loaded single-tooth implants placed in fresh extraction sockets to that of immediately loaded single-tooth implants placed in healed sites. From the years 1997 to 1998, 26 patients, ranging in age from 18 to 70 years, presented for the placement of 28 immediately loaded implants intended to support single-tooth ceramometal restorations. Nineteen implants were placed into fresh extraction sites, and 9 implants were placed into healed sites. Temporary prefabricated acrylic resin crowns were prepared and adjusted. The survival rates were 82.4% and 100% for immediate and non-immediate implants, respectively. Follow-up ranged from 6 to 24 months after implant placement, with a mean of 13 months for the immediate implants and 16.4 months for the non-immediate implants. Authors concluded that immediate loading of single-tooth implants placed in fresh extraction sites carried a risk of failure approximately of 20% in this patient population.

A prospective 5-year pilot study on immediate loading of single-tooth ITI implants in the anterior maxilla was performed by Andersen et al. in 2002 (5). The aim of the study was to evaluate the success rate of immediately loaded single-tooth solid plasma-sprayed (TPS) ITI implants in the maxilla. Eight implants were loaded immediately after placement in eight different patients, and were followed for five years. Temporary acrylic resin restorations, which were fabricated from

the impressions that were taken immediately after implant placement, were connected one week later. These temporary restorations were adjusted in order to avoid any direct occlusive contacts. After six months, the provisional crowns were replaced by definitive ceramic crowns. Regular follow-ups were performed during the investigation period. No implants were lost, and the mean marginal bone level for the eight implants increased by 0.53 mm (range - 0.83 to + 1.54 mm) from placement to the final examination. Only minor complications were noted, and overall patient satisfaction was high.

The effects of immediate loading on threaded, hydroxyapatite-coated, root-form implants in single maxillary premolar replacements was investigated in a preliminary report by Proussaefs et al. in 2002 (6). In all cases, a screw-retained temporary acrylic resin crown was placed immediately after implant surgery. The definitive screw-retained metal-ceramic crown was placed 6 months later. Standardized radiographs demonstrated 0.58, 0.73, 0.84, and 0.90 mm mean marginal bone loss at 1, 3, 6, and 12 months after implant surgery, respectively. Implant mobility was evaluated with the Periotest device. Recession of 0.43 mm was recorded between the 3rd and 12th month. Probing depth measurements revealed that 3 months after implant placement, average probing depth was 3.6 mm, while at 12 months it was 3.2 mm. The peri-implant soft tissue parameters (bleeding on probing, probing depth, peri-implant soft tissue level), mobility, and marginal bone level appeared to be similar to the findings of previous studies on conventional two stage loading protocol. The authors concluded that, under the condition of their investigation, single root-form implants can be immediately loaded when placed in the maxillary premolar area.

Preliminary results after one year of an immediate loading of single-tooth implants in the anterior maxilla was analyzed by Lorenzoni et al. in 2003 (7). The present study evaluated clinical outcomes of immediately loaded Frialit-2 Synchro implants 12 months after placement in the maxillary incisal area. In the course of the investigation, 9 patients have been treated following an immediate loading protocol. All implants were immediately restored with unsplinted acrylic resin provisional crowns and the patients provided with occlusal splints. Regular controls were performed at monthly intervals, intraoral radiographs were taken directly after implant placement, 6 and 12 months post-insertion. The survival rate, clinical stability (Periotest) and radiographic coronal bone defects were evaluated at delivery of the definitive superstructures and 6 months later. No implant failed up to 12 months after insertion, resulting in a 100% survival rate. The presented results showed promising data for immediately loaded single-tooth implants in the anterior maxilla. Author concluded that It is evident that successful immediate loading protocols require a careful and strict patient selection aimed at achieving the best primary stability and avoiding any excessive functional or non-functional loading.

An interim report of a prospective open-ended clinical multicenter study was published in 2003 by Calandriello et al. (8). The purpose of the study was to evaluate immediate loading of Brånemark System TiUnite Wide-Platform implants (Nobel Biocare AB, Gothenburg, Sweden) supporting single molar crowns in the lower jaw. The study included 44 patients treated in three separate private dental offices between March 2001 and June 2002. A total of 50 implants were placed, and all passed the 6-month follow-up; 24 have been followed up for 1 year. All implants were

provided with provisional crowns in centric occlusion at the time of surgery. No implant was lost. Marginal bone levels were found in accordance with normal biologic width requirements. Resonance frequency analysis showed high and consistent implant stability. No biomechanical problems were found associated with the use of wide implants, and the potential physiologic problem in dense mandibular bone was eliminated. Although limited by being a short-term study, the result encouraged immediate loading of single Brånemark System TiUnite Wide-Platform implants placed in the molar regions in the lower jaw. A case report of immediate tooth extraction, placement of a Tapered Screw-Vent implant, and provisionalization in the esthetic zone was published in 2003 by Schirotti (9). This clinical report described an immediate tooth extraction, followed by placement and provisional restoration of a dental implant in the prepared socket of a right maxillary central incisor. The tooth was extracted with minimal hard and soft tissue trauma and without flap reflection. A flapless, transmucosal surgical approach was used to prepare the socket and insert a tapered implant. The implant was immediately restored with a provisional abutment and crown without occlusal contacts. An impression was made 22 days after implant insertion, and a definitive, all-ceramic restoration was placed 3 days later. During the period of provisional progressive loading, no significant soft tissue contraction was observed related to noninvasive operating techniques and the immediate insertion of the provisional restoration. The patient exhibited no clinical or radiologic complications through 8 months of clinical monitoring after loading. The Tapered Screw-Vent implant and all-ceramic restoration provided the patient with immediate esthetics, function, and comfort without any complication during

the postloading follow-up period.

The contemporary implant concepts in aesthetic dentistry specifically immediate single-tooth implants were analyzed in a study published in 2004 by Mankoo (10). The author underlined the concept that immediate implant placement and provisionalization in the aesthetic region has demonstrated predictable long-term results. Use of the immediate loading protocol significantly reduces the need for a second surgical intervention following implant placement. Based on the patient's preoperative condition, this technique can also be incorporated in selected cases without the need for complicated bone grafting and augmentation procedures in compromised ridges. The article discusses the placement of single-tooth implants in the front area and has the advantages and limitations of the immediate placement protocol.

Abboud et al. published in 2005 (11) an investigation on immediate loading of single-tooth implants in the posterior region. Single-tooth implants were placed in healed extraction sites in 20 adult patients. Temporary pre-fabricated acrylic resin crowns were prepared and adjusted. The crown occlusion was adjusted to obtain minimal contacts in maximum intercuspation. After 6 weeks a ceramometal or all-ceramic crown was cemented. Radiographic and clinical examinations were made at baseline and at 3, 6, and 12 months. Cortical bone response and peri-implant mucosal responses were evaluated. The marginal bone level at the time of implant placement was preserved. The mean change in marginal bone level was 0.01 mm at 12 months. The mean Periotest value after 360 days was -4. The peri-implant mucosal adaptation to the anatomic form of the provisional crown resulted in a natural esthetic outcome, and a gain in papilla length was observed. One

implant failure was recorded because of provisional luting cement impaction. The immediate functional loading of implants resulted in bone adaptation to loading. A satisfactory success rate with positive tissue responses was achieved. The results of this limited investigation indicated that immediate loading of unsplinted single-tooth implants in the posterior region may be a further treatment option with an esthetic outcome.

A literature review of clinical studies on immediate and early implant loading protocols was made in 2005 by Attard and Zarb (12). The purpose of their work was to present the outcomes of clinical studies on immediate and early loading protocols, identify shortcomings, and suggest a number of questions still requiring exploration. English language clinical studies, limited to peer-reviewed journals between 1975 and 2004, were reviewed to identify treatment outcomes with these loading protocols. The data were tabulated from studies reporting on patients treated with fixed and overdenture prostheses. The former included partially edentulous patients treated with single or multi-unit prostheses. Within the limitations of a review, the authors concluded that these treatment protocols are predictable in the anterior mandible, irrespective of implant type, surface topography, and prosthesis design (success rates 90%-100%). Limited evidence for the edentulous maxilla (success rates 90%-100%) and the partially edentulous patient (success rates 93%-100%) are available, underscoring the need for further research. Studies suggest that to achieve predictable results in extraction sites, implant placement should be restricted to sites without a history of periodontal involvement (success rates 61%-100%). More accurate long-term studies reporting on treatment protocols for separate clinical situations are required to

allow meaningful comparisons.

The preliminary results after one year of immediate loading of two single tooth implants in the maxilla was investigated in 2005 by Nuzzolese (13). The report described the traumatic avulsion of the left maxillary central and lateral incisors, followed by placement of provisional restorations of two root-form implants in a 14-year old female patient. Ten days following the avulsion, implant therapy was performed with Summers osteotomes and flapless technique using a root-form 3i osseotite NT. Angulated abutments and acrylic provisional crowns were placed. No occlusal contact was detected. An impression was made 30 days after implant insertion and ceramic restorations were placed 3 months later. No significant soft tissue contraction was observed during the provisional period. The patient exhibited no clinical or radiologic complications for 8 months after loading. In carefully selected under-aged patients implant therapy and immediate loading in the anterior maxilla for traumatic tooth avulsion may prove to be a valid option to avoid soft tissue contraction and alveolar bone resorption, with a positive esthetic and psychological response.

Immediate provisional restoration of postextraction implants for maxillary single-tooth replacement was analyzed in 2006 by Ferrara et al. (14). Authors investigated the timing of implant placement and loading following tooth extraction on the ground that it had recently undergone substantial reconsideration. The authors tested a protocol of immediate loading of single implants placed at the time of tooth extraction in a consecutive case series. Thirty-three patients received a single implant-supported crown to replace a maxillary anterior tooth at the time of extraction. Regular recalls were planned for

the following 4 years. One implant did not integrate, and another became unstable secondary to facial trauma. Overall patient satisfaction as well as clinical and radiographic parameters were good.

Barone et al. (15) analyzed in 2006 single implants placed immediately after tooth extraction and immediately restored with temporary abutments and crowns. A total of 18 patients (12 women and 6 men), 22 to 60 years old, were enrolled in this study. All experimental sites showed the absence of fenestrations or dehiscences of the bone walls and a residual gap between implant surfaces and surrounding bone walls ≤ 2 mm. All temporary prostheses were positioned the same day of surgery and were not in occlusal contact with opposing arches. The comparison between baseline and 12-month visits was performed with Student t test for paired data (statistically significant at a level of $\alpha = 0.05$). During the 12-month follow-up period, one fixture was removed 4 weeks after implant placement following an abscess. All remaining implants healed uneventfully with no complications and were assessed as stable and successful at the 12-month check-up. No technical complications such as screw loosening, resin fracture, or pain during chewing were registered during the 12-month period. The authors suggested that immediate placement and restoration of a single implant can be a valid and successful treatment option in case of single compromised teeth. Moreover, this treatment protocol eliminates the need for removable provisional restoration and seems to maintain the pre-existing architecture of soft and hard tissues in most cases. Nonetheless, further prospective and long-term studies are required to obtain a better insight into the limitations of this protocol. A 3-year evaluation of single-tooth implants restored 3 weeks after 1-stage surgery was published in 2007 by Cooper et

al. (16). This prospective cohort trial tried to determine the 3-year implant success rate and prosthesis complications associated with functional loading 3 weeks after one stage placement of Astra Tech single tooth implants replacing maxillary anterior teeth. A secondary objective was to determine peri-implant tissue responses to these implants. The peri-implant bone and mucosal conditions of 43 implants in 39 subjects were radiographically and clinically recorded 3 years after implant placement. Three of 54 implants failed within the first year. No additional failures were recorded after the 12-month reporting period. Peri-implant bone levels were stable for the 3-year period following implant placement. The change in marginal bone levels after 3 years was 0.42 ± 0.59 mm. Papilla growth was measured at 1 and 3 years (0.61 ± 0.95 mm and 0.74 ± 0.79 mm, respectively). The peri-implant tissue dimensions at the gingival zenith also increased at 1 and 3 years (0.34 ± 0.94 mm and 0.51 ± 1.42 mm, respectively). No abutment screw loosening or fracture occurred. The authors concluded that early loading of endosseous dental implants placed in healed ridges offers benefits to clinicians and their patients.

CASE REPORT

A 35 year old white woman was referred by a general dentist to the Oral Surgery and Implantology Department at the ICP Dental School of Milan University to consider implant treatment for her failing left lateral incisor (fig. 1). The patient had no relevant medical past history. She had undergone a traumatic injury involving this tooth. Clinical examination showed that the residual tooth was un-sensitive to percussion. Apparently there were no signs of occlusal trauma or of periodontal

inflammation. No alveolar height loss was detected. Important parameters, such as quality and quantity of soft and hard tissues were evaluated by the surgical team and the patient was informed that she was an ideal candidate for immediate placement and loading of dental implants.

The surgeon proposed to the patient the extraction of the residual tooth and the

immediate insertion of a dental implant with immediate provisional restoration and non functional loading.

The surgery was performed under local anaesthesia. The tooth was extracted and the implant (Global; Sweden & Martina) was placed in the fresh extraction socket with a 50 N*cm final torque (fig. 2). Radiographic investigation was performed during and after

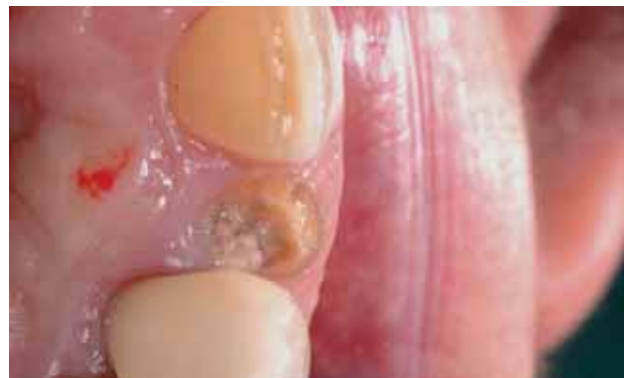
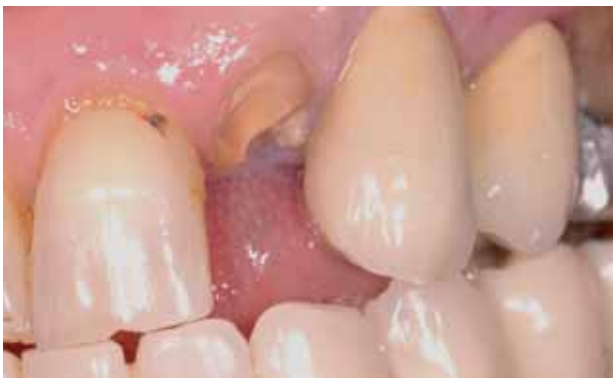
Fig. 1a, 1 b Preoperative clinical examination of the failing left lateral incisor. Frontal and occlusal views.

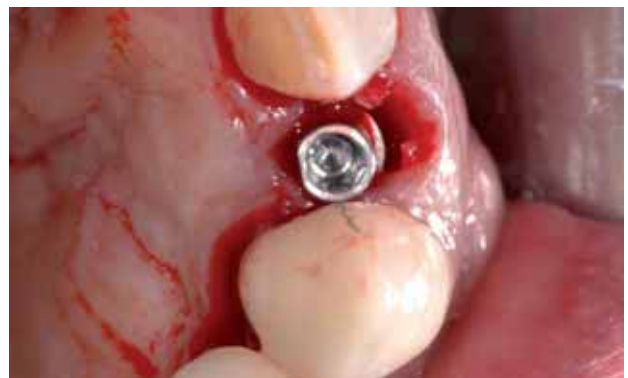
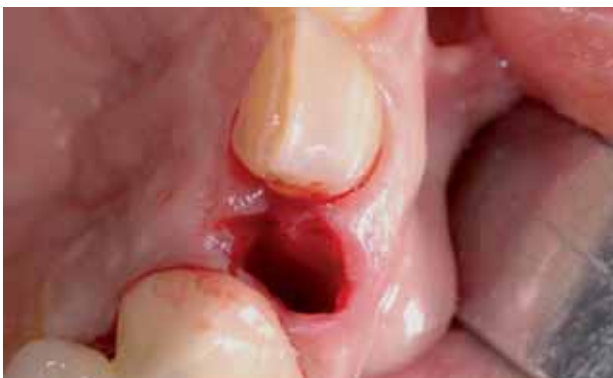
Fig. 2a 2b Tooth extraction and immediate implant placement in the fresh socket.

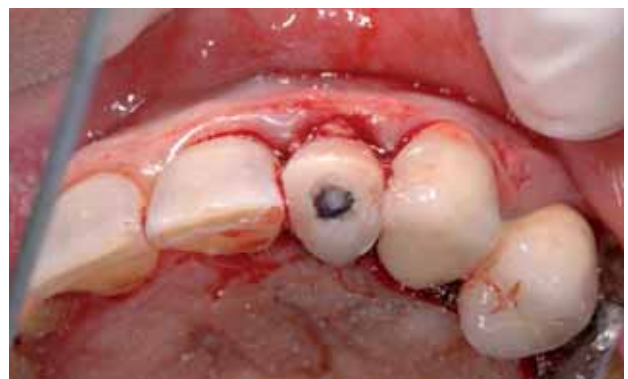
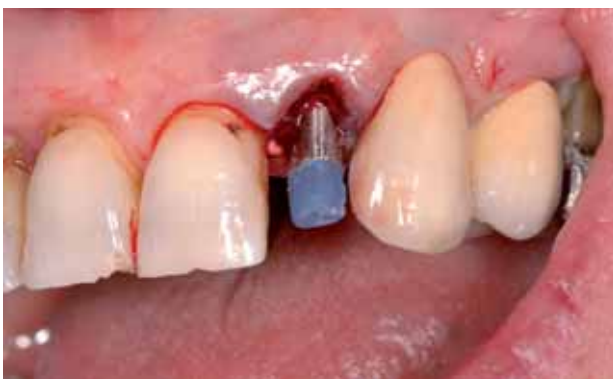
Fig. 3a, 3 b A provisional titanium abutment was used to cement the provisional crown.

implant placement. A 4.3 mm diameter and 15 mm long switching platform implant was placed; the choice of the switching platform implant–abutment is useful for bone preservation (17, 18, 19). The 15 mm dental implant guaranteed the primary stability, extending the preparation 4 mm further from the apex level of the extracted tooth. A provisional titanium abutment (Sweden & Martina) was used. Once the abutment was

ideally shaped, a provisional prefabricated crown was placed. Occlusal contacts on it were eliminated in all lateral and excursive movements. The provisional restoration was cemented with provisional cement (Temp Bond; Kerr) (fig. 3).

The patient was dismissed with postoperative instructions to follow a soft diet and to avoid incising food for 3 months. Chlorhexidine rinse and pain

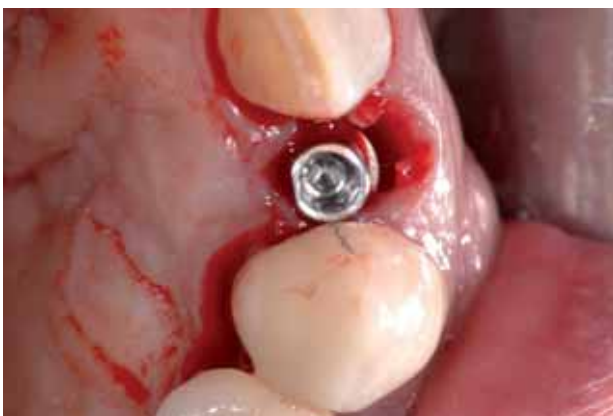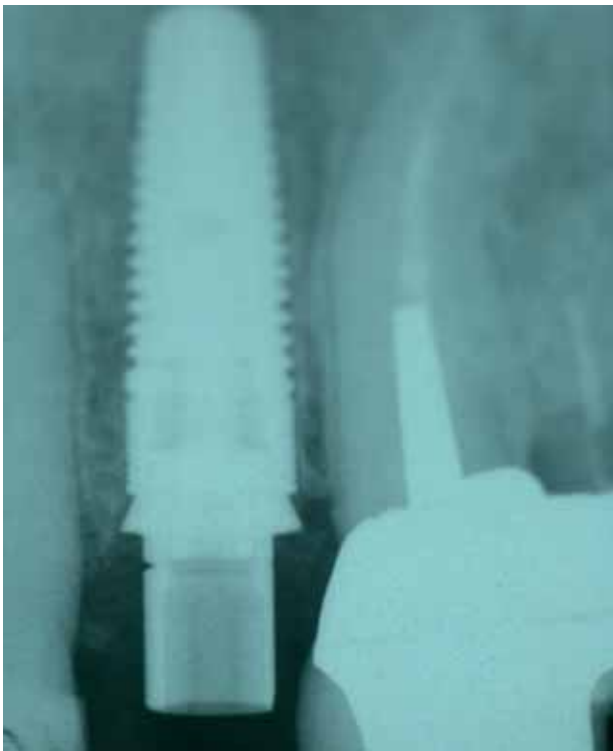


Fig. 4a 4b Radiographic images just after implant placement and 5 months postoperatively.

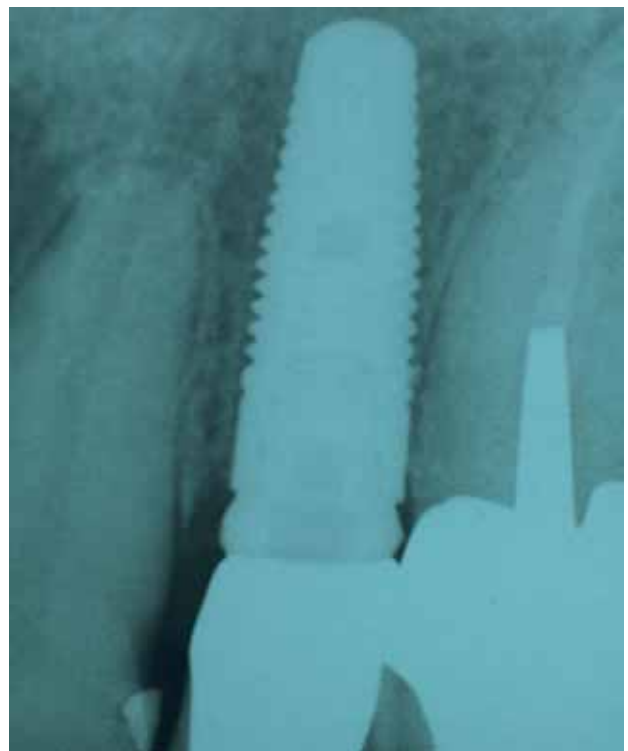
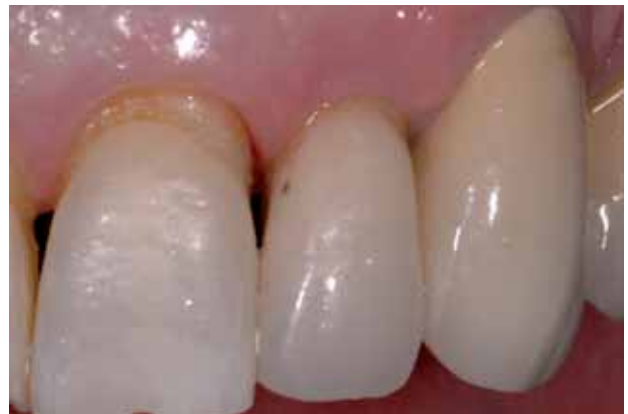

Fig. 5a 5b Final restoration with definitive crown and radiograph taken 18 months after surgery.

control medications were given her. The patient returned after 5 months of healing. No papillae recession or soft tissues were evident. At that time the provisional abutment was removed and an irreversible hydrocolloid impression was taken. When the patient returned after 16 days the definitive crown was applied over the new final abutment and cemented (fig. 4). The patient returned for 18 months control. Radiographic intraoral investigation was performed and only a physiological recession of the medial and distal papillae was observed (fig. 5).

DISCUSSION AND CONCLUSION

The present review clearly highlights that the use of immediately loaded dental implants is well documented in the literature and that a number of clinical trials show that the respective overall implant survival and success rates are satisfactory. However, most of these studies do not include the different parameters that influence the long term success; in fact, occlusal force direction and strength, connection fixture-abutment strains, bone properties, bone conditions and bone augmentation are not always analyzed; on the contrary, the area of implant placement (upper or lower jaw) is always documented in every work.

Summing up, the literature regarding the immediately loaded dental implants is not yet exhaustive. Long term implant therapy outcomes are influenced by different factors and parameters.

This review underlines also that more research is needed before evidence-based surgeons can feel confident in recommending this procedure to their patients.

The case successfully treated shows all those parameters for anterior area; moreover, the

switching platform technique could be a valid solution for the aesthetic area in order to avoid bone loss, as clearly documented by the radiograph at 18 months.

Immediate implant placement and loading require careful patient selection and adequate delivery of care to guarantee soft and hard tissues preservation.

The literature review shows how this topic is today much debated; even if there are no rigid guidelines for this type of surgery, the immediate placement and restoration of a single implant can be considered a valid and successful option in the case of single compromised teeth and an alternative to the conventional two stage technique.

BIBLIOGRAFIA

1. Gomes A, Lozada JL, Caplanis N, Kleinman A. Immediate loading of a single hydroxyapatite-coated threaded root form implant: a clinical report. *J Oral Implantol* 1998;24(3):159-66.
2. Ericsson I, Nilson H, Lindh T, Nilner K, Randow K. Immediate functional loading of Brånemark single tooth implants. An 18 months' clinical pilot follow-up study. *Clin Oral Implants Res* 2000 Feb;11(1):26-33.
3. Proussaefs P, Lozada J. Immediate loading of single root form implants with the use of a custom acrylic stent. *J Prosthet Dent* 2001 Apr;85(4):382-5.
4. Chaushu G, Chaushu S, Tzohar A, Dayan D. Immediate loading of single-tooth implants: immediate versus non-immediate implantation. A clinical report. *Int J Oral Maxillofac Implants* 2001 Mar-Apr;16(2):267-72.
5. Andersen E, Haanaes HR, Knutsen BM. Immediate loading of single-tooth ITI implants in the anterior maxilla: a prospective 5-year pilot study. *Clin Oral Implants Res* 2002 Jun;13(3):281-7.
6. Proussaefs P, Kan J, Lozada J, Kleinman A, Farnos A. Effects of immediate loading with threaded hydroxyapatite-coated root-form implants on single premolar replacements: a preliminary report. *Int J Oral Maxillofac Implants* 2002 Jul-Aug;17(4):567-72.
7. Lorenzoni M, Pertl C, Zhang K, Wimmer G, Wegscheider WA. Immediate loading of single-tooth implants in the anterior maxilla. Preliminary results after one year. *Clin Oral Implants Res* 2003 Apr;14(2):180-7.
8. Calandriello R, Tomatis M, Vallone R, Rangert B, Gottlow J. Immediate occlusal loading of single lower molars using Brånemark System Wide-Platform TiUnite implants: an interim report of a prospective open-ended clinical multicenter study. *Clin Implant Dent Relat Res* 2003;5 Suppl 1:74-80.

9. Schirolli G. Immediate tooth extraction, placement of a Tapered Screw-Vent implant, and provisionalization in the esthetic zone: a case report. *Implant Dent.* 2003;12(2):123-31. Review.
10. Mankoo T. Contemporary implant concepts in aesthetic dentistry--Part 2: Immediate single-tooth implants. *Pract Proced Aesthet Dent* 2004 Jan-Feb;16(1):61-8; quiz 70.
11. Abboud M, Koeck B, Stark H, Wahl G, Paillon R. Immediate loading of single-tooth implants in the posterior region. *Int J Oral Maxillofac Implants* 2005 Jan-Feb;20(1):61-8.
12. Attard NJ, Zarb GA. Immediate and early implant loading protocols: a literature review of clinical studies. *Review J Prosthet Dent* 2005 Sep;94(3):242-58.
13. Nuzzolese E. Immediate loading of two single tooth implants in the maxilla: preliminary results after one year. *J Contemp Dent Pract* 2005 Aug 15;6(3):148-57.
14. Ferrara A, Galli C, Mauro G, Macaluso GM. Immediate provisional restoration of postextraction implants for maxillary single-tooth replacement. *Int J Periodontics Restorative Dent* 2006 Aug;26(4):371-7.
15. Barone A, Rispoli L, Vozza I, Quaranta A, Covani U. Immediate restoration of single implants placed immediately after tooth extraction. *J Periodontol* 2006 Nov;77(11):1914-20.
16. Cooper LF, Ellner S, Moriarty J, Felton DA, Paquette D, Molina A, Chaffee N, Asplund P, Smith R, Hostner C. Three-year evaluation of single-tooth implants restored 3 weeks after 1-stage surgery. *Int J Oral Maxillofac Implants* 2007 Sep-Oct;22(5):791-800.
17. Gardner DM. Platform switching as a means to achieving implants esthetics. *New York Stat Journal* 2005;71:34-37.
18. Satoh T, Maeda Y, Komiyama Y. Biomechanical rationale for intentionally inclined implants in the posterior mandible using 3d finite element analysis. *J Oral Maxillofacial Implants* 2005;20:533-39.
19. Maeda Y, Miura J, Taki I, Sogo M. Biomechanical analysis on platform: is there any biomechanical rationale? *Clinical Oral Implant Research* 2007;18:581-4.