



Exploring the hidden anatomy: Cone-Beam CT insights into mental and median lingual foramen variations in South Indian population

Abstract

Background

The mental foramen (MF) and median lingual foramen (MLF) are key anatomical landmarks in the mandible, crucial for dental implants, extractions, and other mandibular surgeries. Despite their importance, variations in these foramina within specific populations, such as the South Indian demographic, are not well understood. This study aimed to assess these variations among the South Indian population.

Materials and Methods

Cone-beam computed tomography scans of 892 patients (452 men and 440 women), aged 25 to 65, were analyzed. MF characteristics measured included distance from crest to upper border (MF1), distance from lower border to mandibular border (MF2), and emerging angle (EA), on both sides. MLF characteristics included distance from upper border of buccal (BD) and lingual terminals (LD) to the alveolar

crest, canal length (LC), and diameters of the buccal (DB) and lingual terminals (DL), with assessments for supraspinous and infraspinous MLF. The data was collected and statistically analyzed.

Results

MF parameters were significantly larger on the right side compared to the left ($p < 0.05$). Significant differences ($p < 0.05$) were observed between males and females for all MF measurements. Supraspinous and infraspinous MLF measurements also showed significant differences ($p < 0.05$), but no significant gender differences were found in MLF measurements ($p > 0.05$).

Conclusion

MF dimensions were greater on the right side, and males had higher mean values. Also, infraspinous MLF showed greater distances from the alveolar crest, with no significant gender differences.

Authors

Prasanth P.¹
Rajasekar A.^{2*}

¹Postgraduate, Department of Implantology, Saveetha Dental College and Hospitals, Saveetha Institute of Medical and Technical Sciences (SIMATS), Saveetha University, Chennai, India.

²Associate Professor, Department of Periodontology, Saveetha Dental College and Hospitals, Saveetha Institute of Medical and Technical Sciences (SIMATS), Saveetha University, Chennai, India

*Corresponding Author

DOI

10.23805/JO.2025.692

Keywords

Dental implants, Mandible, Mandibular foramen, Imaging, Surgical anatomy.

INTRODUCTION

Dental implants are now a standard treatment for tooth replacement, yet anatomical limitations and restorative demands require precise planning and surgical positioning. Procedures in the anterior mandible, such as implant installation and graft harvesting, can lead to complications involving vascular structures, which may be life-threatening (1). The rising use of dental implants may account for the growing interest in the anatomical features of the mandibular symphysis.

The mandibular foramen marks the beginning of the mandibular canal, which contains the inferior alveolar nerve and artery. At the mental foramen (MF), the mandibular canal divides into its mental and incisive branches. Usually, the MF is located in the space between the premolar teeth on the labial surface. However, mandible undergoes remodeling throughout life, affecting various parameters, including the MF, mandibular foramen, and mandibular canal(2). MF is a critical anatomical landmark on the anterolateral part of the mandibular body, primarily because it is where the terminal branches of the mandibular nerve and blood vessels emerge(3). During surgical procedures, MF may sustain damage that causes sensory dysfunction of the gingiva, lower lip, and chin from MF to midline. Numerous studies have documented both transient and permanent sensory abnormalities of the relevant soft tissue following dental implant implantation(4-6).

Lingual foramina are supplementary foramina located on the mandibular lingual surface.

Though they can also be seen around the second premolar, they are usually found in the interforaminal region. Lingual foramina act as conduits for neurovascular structures, including branches of the lingual artery, submental artery, and mylohyoid nerve(7). Lingual foramina are divided into two categories: median lingual foramen (MLF) and lateral lingual foramen (LLF) based on where they are located on the inner surface of the mandible. With a prevalence ranging from 96% to 100%, MLF are the mandibular lingual foramina that are most frequently observed and reported. Compared to MLF, LLF evaluations are less common, with a prevalence ranging from 6 to 80%(8). The MLF can be located above or below the mental spines and according to their vertical location, can be called supraspinous MLC or infraspinous MLC respectively(9).

Cone-beam computed tomography (CBCT) is crucial for assessing anatomical landmarks for implant placement because it provides three-dimensional, detailed images that enhance the precision and accuracy of treatment planning(10). The ability to

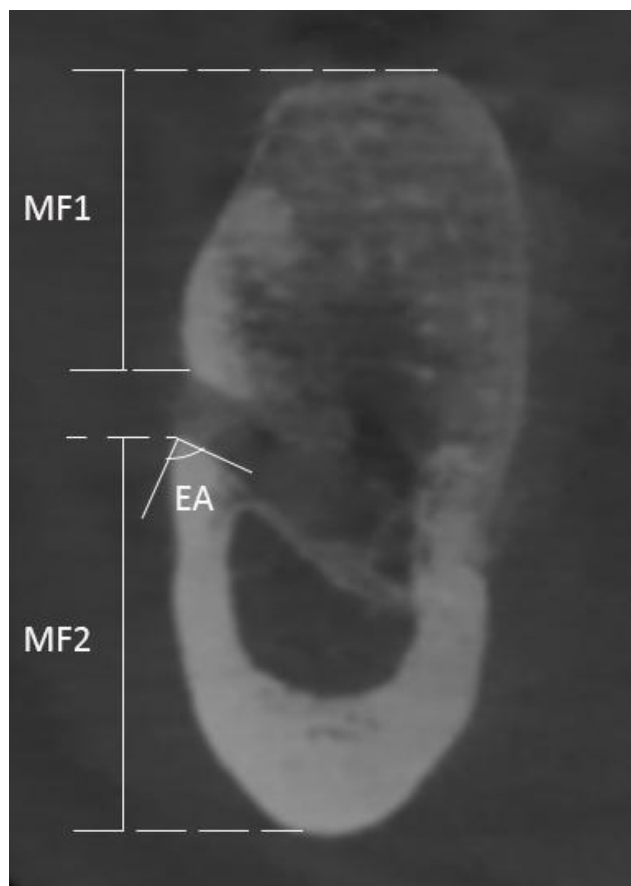


Fig. 1 Mental foramen (MF) characteristics

assess bone quality, quantity, and density, as well as identify anatomical variations, makes CBCT an invaluable tool for pre-surgical planning and ensuring the successful and safe placement of dental implants. The present research was conducted with the primary aim to assess variations in mental foramen (MF) and median lingual foramen (MLF) among the South Indian population. The secondary aim was to determine whether gender and location had an impact on these anatomical landmarks.

MATERIALS AND METHODS

Eight hundred ninety-two patients aged 25 to 65 years were included in this study. This study involved patients who were referred for a head and neck CBCT scan between January 2024 and June 2024 to the Department of Radiology, Saveetha Dental College and Hospitals, Chennai, India. The study was carried out in compliance with 1975 Helsinki Declaration, as amended in 2013, with approval from Saveetha Dental College and Hospitals' Institutional Ethical Committee (IHEC/SDC/MSIMPLANT-2308/24/076). Every participant gave their informed consent. G*Power Software, Version 3.0 was used to calculate the sample size based on the mean and standard deviation values from a prior study(11). 80% power and an α of 0.05 were chosen. The target sample size was 850 subjects. This

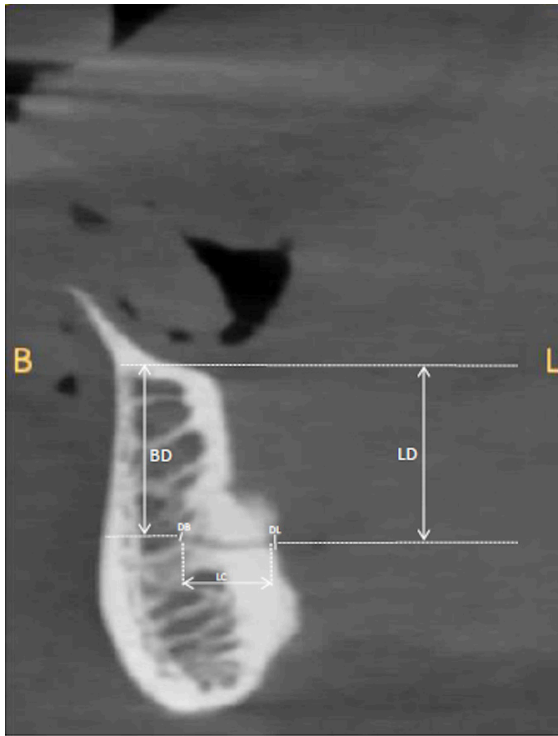


Fig. 2 Supraspinous median lingual foramen (MLF) characteristics

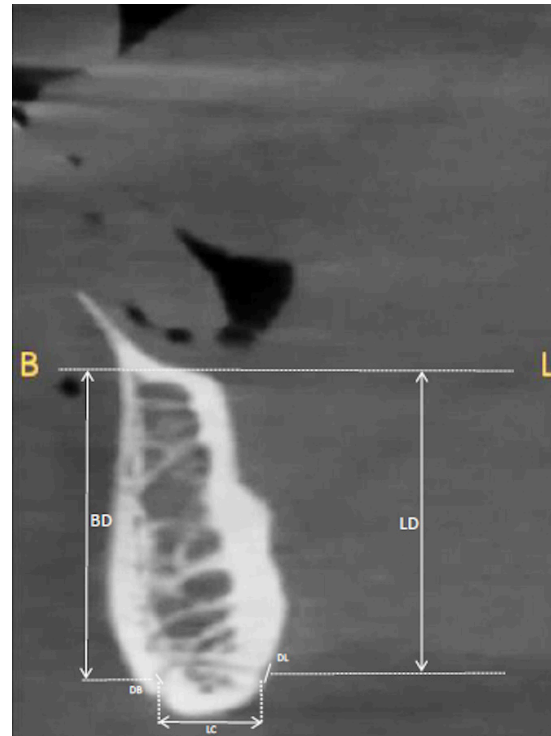


Fig. 3 Infraspinous median lingual foramen (MLF) characteristics

study included patients who were partially edentulous in lower anterior region; free of periodontal disease and pathological conditions or deformities in the mandibular jaw. Patients with history of mandibular surgery; history of trauma or orthognathic surgery, presence of pathologic bone disease and syndromic patients were excluded.

The MF and MLF characteristics were evaluated using CBCT (Carestream CS 9600, GA, US). Standard operating procedures were followed to obtain the CBCT scans: exposure of 90 kVp, 180 μ voxel size, 10 \times 5 cm field of view, and 1 mm slice intervals for cross-sectional images. The images were then analysed using CS 3D Imaging Software (Version 3.10.33.0). MF characteristics (Fig. 1) measured included distance from crest to upper border (MF1), distance from lower border to mandibular border (MF2), and emerging angle (EA). These measurements were made on right and left sides. MLF characteristics in terms of supraspinous MLF (Fig. 2) and infraspinous MLF (Fig. 3) included distance from upper border of buccal (BD) and lingual terminals (LD) to the alveolar crest, canal length (LC), and diameters of the buccal (DB) and lingual terminals (DL). All measurements were performed by one investigator (PP).

Statistical Analysis

Data analysis was conducted using the Statistical Package for Social Sciences (SPSS Software, Version

23.0; IBM Corp., Armonk, NY, USA). Normality was assessed with the Shapiro-Wilk and Kolmogorov-Smirnov tests, which indicated a parametric distribution of the data. The results were presented using means and standard deviations. Differences between the right and left sides and between males and females for all MF characteristics were analyzed using paired and independent t-tests, respectively. Differences between supraspinous MLF and infraspinous MLF and between males and females for all median LC characteristics were assessed using independent t-tests. A p-value below 0.05 was deemed statistically significant.

RESULTS

In the present study, 892 participants of age between 25-60 years (mean age of 44.36 years) were evaluated for the above-mentioned MF and median LC characteristics. Among 892 participants, 452 were males and 440 were females.

MF Characteristics

The mean distance from alveolar crest to upper border of foramen on right side was 9.3 \pm 2.00 mm and left side was 8.13 \pm 1.7 mm. The mean distance from lower border of foramen to mandibular border on right side was 13.7 \pm 0.78 mm and left side was 12.2 \pm 0.63 mm. The mean emerging angle on right side was 64.1 \pm 6.2 degrees and left side was 50.7 \pm 5.4

MF Characteristics	Right		p value	Left		p value
	Males	Females		Males	Females	
MF1 (mm)	11.09±0.6	7.5±1.08	0.00*	9.6±0.59	6.5±0.8	0.00*
MF2 (mm)	14.3±0.3	13.11±0.4	0.00*	12.7±0.42	11.7±0.28	0.00*
EA (degrees)	51.2±7.06	51.19±3.03	0.00*	53.8±8.4	51.9±1.9	0.00*

*Statistically significant

Tab. 1 Genderwise comparison of mental foramen characteristics on right and left sides

Variables	Supraspinous MLF	Infraspinous MLF	p value
BD	9.42±2.4	16.6±1.9	0.00*
LD	9.4±1.5	20±0.9	0.00*
LC	8.9±0.8	7.1±0.3	0.04*
DB	0.61±0.06	0.64±0.05	0.31
DL	0.7±0.08	0.6±0.07	0.33

*Statistically significant

Tab. 2 Comparison of supraspinous MLF and infraspinous MLF measurements

Variables		Males	Females	p value
BD	Supraspinous MLF	9.37±2.37	9.4±2.51	0.70
	Infraspinous MLF	16.5±1.8	16.7±2.08	0.50
LD	Supraspinous MLF	9.26±1.5	9.58±1.50	0.21
	Infraspinous MLF	19.8±1.09	20.1±0.65	0.07
LC	Supraspinous MLF	8.81±0.79	8.91±0.82	0.39
	Infraspinous MLF	7.22±0.32	7.43±0.31	0.49
DB	Supraspinous MLF	0.61±0.069	0.62±0.063	0.24
	Infraspinous MLF	0.64±0.94	0.64±0.097	0.72
DL	Supraspinous MLF	0.70±0.86	0.71±0.89	0.84
	Infraspinous MLF	0.69±0.07	0.68±0.06	0.62

Tab. 3 Genderwise comparison of supraspinous MLF and infraspinous MLF measurements

degrees. On comparing the right and left sides, there was a statistical difference ($p < 0.05$) in terms of all the assessed mental foramen parameters. On genderwise comparison of MF characteristics on right and left sides, males presented higher values in terms of all the assessed parameters than females and the difference was statistically significant ($p < 0.05$) (Table 1).

MLF Characteristics

On assessing supraspinous MLF, the mean BD, LD, LC, DB and DL were 9.42±2.4 mm, 9.4±1.5 mm, 8.9±0.8 mm, 0.6±0.06 mm and 0.7±0.08 mm respectively. In terms of infraspinous MLF, the mean BD, LD, LC, DB and DL were

16.6±1.9 mm, 20±0.9 mm, 7.1±0.3 mm, 0.64±0.09 mm and 0.6±0.07 mm respectively. On comparing supraspinous MLF and infraspinous MLF measurements, there was a statistical difference ($p < 0.05$) in terms of all the parameters (Table 2). On genderwise comparison of supraspinous MLF and infraspinous MLF measurements, there was no statistical difference in terms of mean BD, LD, LC, DB and DL with the p value of more than 0.05 (Table 3).

DISCUSSION

Although oral implants are commonly used to restore the edentulous mandible, some patients

have experienced nerve disturbances in the anterior mandible following implant placement. Therefore, preoperative radiographic planning should take into account the mandibular mental foramen and lingual canal to prevent neurovascular complications. This study was conducted among the South Indian population to identify anatomical variations in the mental foramen and median lingual foramen.

The results of this investigation showed that distance from crest to upper border, distance from lower border to mandibular border, and emergence angle were greater on the right side. Additionally, males exhibited higher mean values for these measurements. This observation aligns with the study by Muinelo-Lorenzo J et al.(12), who evaluated scans of 344 patients to assess the dimensions of the MF, including the distance from MF to crest and MF to lower border of mandible. Males demonstrated significantly larger MF dimensions than females, and they found that the MF dimensions were related to both gender and mandibular side, with the right side having larger distances than the left. Studies on dry mandibles(13,14)revealed similar results, demonstrating that the males had noticeably larger dimensions, which validates the current study's findings. Furthermore, study by Haktanir A et al.(15) revealed that men had higher mean values than females and that the right side had a larger distance from MF to crest.

Kalender A et al.(16) demonstrated greater emergence angle among males. The location and angle of emergence of the mental foramen are crucial for planning dental implant placement. A greater emergence angle might necessitate adjustments in the diameter and length of dental implants. Also, in cases where the emergence angle is more pronounced, surgeons may opt to change the entry point for the implant. Indeed, studies have reported findings that contrast with the results of current study, indicating that mean height from MF to alveolar crest was greater in females(17,18). There were no statistically significant differences between the right and left mental foramen in a different study by Chkoura A et al.(19), which assessed 794 panoramic radiographs for the location and symmetry of the mental foramina. These studies suggest that gender and location differences in mandibular anatomy can vary significantly across different populations.

Regarding the median lingual foramen, the present study observed that distance from upper border of buccal and lingual terminals to alveolar crest were greater in infraspinous MLF than supraspinous MLF. In case of edentulousness, thickness of crestal bone might be insufficient to place an implant directly. In such cases, it may be necessary to reduce bone vertically to reach a wider and more stable section of bone for implant placement. However, reducing the vertical bone height can bring the implant closer to LC. The present study found that the average distance

from the crest of the ridge to the supraspinous MLF was 9.42 ± 2.4 mm. This relatively short distance indicates that during implant placement in anterior mandible, the supraspinous MLF is a critical anatomical feature to consider to avoid accidental damage. In contrast, the infraspinous MLF was located at an average distance of 16.6 ± 1.9 mm from the crest of the ridge, suggesting that this canal is usually at a safer distance from typical implant sites. Chaar MS et al.(20), explored vascular and neurosensory complications in edentulous patients following the placement of single implants in the mandibular midline, focusing on their connection to lingual canals. The study reported lesser height in relation to supraspinous and hence injury to the supraspinous MLF may occur more commonly during midline implant placement.

The present study also documented that the diameter of buccal and lingual terminals was almost similar in supraspinous MLF and infraspinous MLF, within 1 mm. If the diameter of the median lingual foramen is greater than 1 mm, there is an increased risk of bleeding, but this risk only materialises in the event that the lingual cortex is perforated(21). In this study, the average diameters were 0.61 ± 0.06 mm for the buccal terminal of the supraspinous MLF, 0.64 ± 0.05 mm for the infraspinous MLF, 0.7 ± 0.08 mm for the lingual terminal of the supraspinous MLF, and 0.6 ± 0.07 mm for the infraspinous MLF. Each of these average diameters fell within the acceptable range. According to a recent meta-analysis, the lingual canal's diameter is a crucial anatomical variation to take into account when placing implants in the mandible's midline(22). There is also a high chance that a single midline implant will come into contact with the lingual foramen, according to CBCT studies on edentulous cadaveric mandibles (23-24). The present study also reported no gender related variations regarding MLF dimensions, which is in agreement with previous studies (25,26). In contrast, few studies have noted genderwise differences in MLF dimensions(27,28).

The contrasting findings highlight the complexity of mandibular anatomy and emphasize the need for clinicians to consider a wide range of anatomical variations when planning surgical interventions in order to minimize the risk of nerve injury or other complications. Moreover, these studies underscore the importance of using large, diverse sample sizes in research to capture the full spectrum of anatomical variability. By acknowledging and understanding these variations, practitioners can enhance their diagnostic and treatment planning processes, ensuring more personalized and effective care for patients.

CONCLUSION

In this study, CBCT images were used to examine anatomical variations in the mandible, specifically the

mental foramen and lingual canal. Findings showed that for the mental foramen, distance from crest to upper border, distance from lower border to mandibular border, and the angle of emergence were all greater on the right side. Additionally, males had higher mean

values for these measurements. For the median lingual foramen, distances from upper borders of buccal and lingual terminals to the alveolar crest were greater in the infraspinous median lingual foramen, with no significant gender differences.

REFERENCES

- La Monaca G, Pranno N, Polimeni A, Annibaldi S, Di Carlo S, Pompa G, et al. Hemorrhagic complications in implant surgery: A scoping review on etiology, prevention, and management. *J Oral Implantol*. 2023 Aug 1;49(4):414-27.
- Aminoshariae A, Su A, Kulild JC. Determination of the location of the mental foramen: A critical review. *J Endod*. 2014 Apr 1;40(4):471-5.
- Smajilagic A, Dilberovic F. Clinical and anatomy study of the human mental foramen. *Bosn J Basic Med Sci*. 2004 Aug;4(3):15-23.
- Walton JN. Altered sensation associated with implants in the anterior mandible: A prospective study. *J Prosthet Dent*. 2000 Apr 1;83(4):443-9.
- Fernandes J, Rohinikumar S, Nessapan T, Rani D, Abhinav RP, Gajendran P. CBCT Analysis of prevalence of the canalis sinuosus on the alveolar ridge in the site of endosseous implant placement: A retrospective study. *J Long Term Eff Med Implants*. 2022;32(2):45-50.
- Nelke K, Janeczek M, Pasicka E, Żak K, Łukaszewski M, Jachach R, et al. The temporary mental nerve paresthesia as an outcome of dentigerous cyst removal during preparation for dental implant placement: A case report. *Medicina*. 2023 Apr 5;59(4):711-9.
- He P, Truong MK, Adeeb N, Tubbs RS, Iwanaga J. Clinical anatomy and surgical significance of the lingual foramina and their canals. *Clin Anat*. 2017 Mar;30(2):194-204.
- Bernardi S, Bianchi S, Continenza MA, Macchiarelli G. Frequency and anatomical features of the mandibular lingual foramina: Systematic review and meta-analysis. *Surg Radiol Anat*. 2017 Dec;39:1349-57.
- Jayabalan J, Muthusekhar MR, Muthukrishnan A. Prevalence of variations in the lingual foramina—A CBCT study. *J Comp Med Research*. 2020 Oct 14;11:195-202.
- Jacobs R. Dental cone beam CT and its justified use in oral health care. *J Belg Soc Radiol*. 2011 May 4;94(5):254-65.
- Felicita AS, Maheswari TU. The identification of possible reference planes on a CBCT scan taken with a small FOV—an observational analytical study. *Australasian Orthodontic Journal*. 2022;39(2):174-84.
- Muinelo-Lorenzo J, Fernández-Alonso A, Smyth-Chamosa E, Suárez-Quintanilla JA, Varela-Mallou J, Suárez-Cunqueiro MM. Predictive factors of the dimensions and location of mental foramen using cone beam computed tomography. *PloS one*. 2017 Aug 17;12(8):e0179704.
- Apinhasmit W, Methathrathip D, Chompoonong S, Sangvichien S. Mental foramen in Thais: An anatomical variation related to gender and side. *Surg Radiol Anat*. 2006 Oct;28:529-33.
- Udhaya K, Saraladevi KV, Sridhar J. The morphometric analysis of the mental foramen in adult dry human mandibles: A study on the South Indian population. *J Clin Diagn Res*. 2013 Aug;7(8):1547-51.
- Haktanir A, Ilgaz K, Turhan-Haktanir N. Evaluation of mental foramina in adult living crania with MDCT. *Surg Radiol Anat*. 2010 Apr;32:351-6.
- Kalender A, Orhan KA, Aksoy U. Evaluation of the mental foramen and accessory mental foramen in Turkish patients using cone beam computed tomography images reconstructed from a volumetric rendering program. *Clin Anat*. 2012 Jul;25(5):584-92.
- Chen Z, Chen D, Tang L, Wang F. Relationship between the position of the mental foramen and the anterior loop of the inferior alveolar nerve as determined by cone beam computed tomography combined with mimics. *J Comput Assist Tomogr*. 2015 Jan 1;39(1):86-93.
- Sahman H, Sisman Y. Anterior loop of the inferior alveolar canal: a cone-beam computerized tomography study of 494 cases. *J Oral Implantol*. 2016 Aug 1;42(4):333-6.
- Chkoura A, El Wady W. Position of the mental foramen in a Moroccan population: A radiographic study. *Imaging Sci Dent*. 2013 Jun 1;43(2):71-5.
- Chaar MS, Naguib AA, Abd Alsamad AM, Ahmed DF, Abdel Nabi N, Kern M. Vascular and neurosensory evaluation in relation to lingual canal anatomy after mandibular midline implant installation in edentulous patients. *Clin Oral Investig*. 2022 Mar;26(3):3311-23.
- Rosano G, Taschieri S, Gaudy JF, Testori T, Del Fabbro M. Anatomic assessment of the anterior mandible and relative hemorrhage risk in implant dentistry: A cadaveric study. *Clin Oral Implants Res*. 2009;20:791-5.
- Bernardi S, Bianchi S, Continenza MA, Macchiarelli G. Frequency and anatomical features of the mandibular lingual foramina: Systematic review and meta-analysis. *Surg Radiol Anat*. 2017;39:1349-57.
- Birkenfeld F, Becker M, Sasse M, Gassling V, Lucius R, Wiltfang J, et al. Detection of the genial spinal canal in atrophic mandibles with a CBCT: A cadaver study. *Dentomaxillofac Radiol*. 2015;44:20140290.
- Liang X, Jacobs R, Lambrechts I, Vandewalle G. Lingual foramina on the mandibular midline revisited: A macroanatomical study. *Clin Anat*. 2007;20:246-51.
- Soto R, Concha G, Pardo S, Cáceres F. Determination of presence and morphometry of lingual foramina and canals in Chilean mandibles using cone-beam CT images. *Surg Radiol Anat*. 2018 Dec;40:1405-10.
- Kim DH, Kim MY, Kim CH. Distribution of the lingual foramina in mandibular cortical bone in Koreans. *J Korean Assoc Oral Maxillofac Surg*. 2013 Dec;39(6):263-8.
- Alqutaibi AY, Alassaf MS, Elsayed SA, Alharbi AS, Habeeb AT, Alqurashi MA, et al. Morphometric analysis of the midline mandibular lingual canal and mandibular lingual foramina: A cone beam computed tomography (CBCT) evaluation. *Int J Environ Res Public Health*. 2022 Dec 16;19(24):16910.
- Sheikhi M, Mosavat F, Ahmadi A. Assessing the anatomical variations of lingual foramen and its bony canals with CBCT taken from 102 patients in Isfahan. *Dent Res J*. 2012 Dec;9(Suppl 1):S45-S50.