

A randomized clinical trial in “All on four” rehabilitations with 6-years follow-up: digital versus traditional workflow

Abstract

Aim

The present study compares and evaluates the “All on Four” type rehabilitations obtained through a traditional technique, with “All on Four” rehabilitations made using an entirely digital method, with a 6-years follow-up.

Materials and methods

The workflow displayed in this study analyzes in detail each design and clinical phase of both methods, which were applied to a total of 50 patients recruited by the Department of Dentistry of the University Vita e Salute San Raffaele. The selected patients were divided into two randomized groups of 25 people: in total, 100 implants were placed in 25 patients who received a full-arch rehabilitation performed using the traditional All on Four method and 100 implants in 25 patients who received a full-arch rehabilitation performed using a digital method.

After 6 years, different percentages of success were obtained: 98% of success for the group of patients treated with the traditional “All on Four” protocol and 100%

of success for the group treated with the digital protocol. At each time interval a significant difference ($P < 0.0001$) in peri-implant crestal bone loss between the two groups was detected, with an average Marginal Bone Level (MBL) at 6 years of 1.12 ± 0.25 mm in patients treated with traditional method and 0.88 ± 0.10 mm in patients treated with digital method. Patients belonging to the digital group have judged the immediate loading (92%), digital smile preview (93%), the mock-up test (98%) and guided surgery (94%) as very effective. All patients treated with a digital method reported a lower value of during-surgery and post-surgery pain compared to patients rehabilitated using traditional method.

Conclusion

The totally digital protocol described in the present study represents a valid therapeutic alternative to the traditional “All on Four” protocol for implant-supported rehabilitations of edentulous dental arches.

Authors

**F. Cattoni^{1*},
A. Merlone¹,
L. Chirico¹,
A. Bosio¹,
M. Manacorda¹,
R. Vinci²,
E. F. Gherlone³**

¹*DDS, Dental School, Vita-Salute San Raffaele University, Milan, Italy and Department of Dentistry, IRCCS San Raffaele Hospital, Milan, Italy.

²MD MFS Dental School, Vita-Salute San Raffaele University, Milan, Italy and Department of Dentistry, IRCCS San Raffaele Hospital, Milan, Italy.

³MD, DMD, Full Professor and Chairman, Dental School, Vita Salute University and Department of Dentistry, IRCCS San Raffaele Hospital, Milan, Italy.

*Corresponding author

DOI

10.23805/JO.2024.673

Keywords

Full-arch rehabilitations;
digital workflow;
edentulous dental arches.

INTRODUCTION

Obtaining an effective implant supported prosthetic device in edentulous patients is the main goal of an oral rehabilitation. This type of rehabilitation is becoming more and more used considering the increase of life expectancy and the growth in the number of edentulous patients with specific and aesthetic needs, especially in cases where more traditional removable prosthetic solutions are not well tolerated. To satisfy the need to stabilize the prosthetic devices, solutions have been developed that use multiple osseointegrated titanium implants as support systems (1-3).

The therapeutic efficacy of rehabilitations based on the use of a small number of implants, with a high aesthetic and functional yield, is now universally recognized (4-8). Among the most used implantology protocols for the treatment of dental arches with moderate/severe bone atrophy, the "All on Four" technique continues to achieve great success within the scientific community (4-6). This method involves the placement of 4 implants: two axial ones positioned in the anterior sector and two inclined at about 30 - 35 ° with respect to the occlusal plane in the posterior sectors. This inclination allows to distalize the implant emergency and to provide support to a prosthetic arch up to the first molar, and to avoid any damage the noble structures such as the maxillary sinus (upper arch) and the inferior alveolar vascular-nerve bundle (lower arch). This also avoids the bone regeneration procedure in the presence of severe atrophies (9). In recent years, digital technologies have significantly changed the clinical dental practice with regards to diagnosis, prosthetic planning, guided surgery and implant-supported rehabilitations (4-6).

With the recent introduction of software specifically programmed for clinicians and dental technicians, it is possible to combine the aforementioned procedures (4). It is therefore possible to elaborate an implant-prosthetic rehabilitation, even in the more complex scenarios, using a software, thus having the opportunity to pre-visualize the final result and consequently improve the communication between the clinician and the patient, as well as between prosthodontist, surgeon and dental technician, also obtaining a better quality of the project and the final result (4,5). Starting from 2014, clinicians from the Department of Dentistry of the Vita-Salute San Raffaele University, have developed and applied a specific digital protocol. More than 4 years later, the results of this work highlighted the main differences between a digital and a traditional method.

The aim of the present study is to describe and apply the two protocols on two homogeneous groups of patients, evaluating Marginal Bone Level values (at 12, 24, 36, 48, 60, and 72 months) by radiographic evaluation, implant and prosthetic complications and failures, appreciation by the patient of the procedures used, and evaluation of operative and post-operative pain.

MATERIALS AND METHODS.

Patients Selection

All procedures executed in this study involving human participants were in accordance with institutional and/or national research committee ethical standards and the 1964 Declaration of Helsinki and its subsequent amendments or comparable ethical standards. The ethics committee approval number is CE/INT/10/2015.

The study was conducted at the Dentistry Department of the IRCCS San Raffaele, Milan, Italy.

Patients were enrolled from January 2017 to November 2017; the study data were collected from the date of patient recruitment until January 2024.

The implant-prosthetic protocol included a population of 50 patients, between 46 and 85 years, who underwent rehabilitation of the edentulous maxilla with a reduced number of implants.

Twenty-five patients were randomly selected and subjected to the implant-prosthetic protocol with the digital method. The remaining twenty-five underwent the traditional "All On Four" protocol.

Inclusion criteria were: patients of any ethnicity over 18 years of age, male and female; patients with good general health, without chronic disease (immunosuppression, untreated coagulation problems, chemotherapy and radiotherapy, assumption of bisphosphonate drugs, cardiac conditions and uncompensated diabetes). The selected patient must have had at least one totally edentulous arch or with few hopeless elements, upper mouth opening wider than 50 mm, sufficient bone available for implant fixtures placement: for the edentulous maxilla the anatomical inclusion criterion was a residual ridge crest of a minimum of 4 mm wide buccolingually and higher than 10 mm high from canine to canine; for the lower maxilla a residual ridge crest at least 4 mm wide buccolingually and higher than 8 mm high in the intraforaminal area.

Exclusion criteria were: smoking and drug habits, pregnancy, irregular or thin bone crest and high smile line in the maxilla that would have needed bone reduction

Clinical Procedure

Patients from both groups underwent a preliminary oral examination. During this, after a detailed compilation of the medical and dental history, the clinicians would:

- confirm the presence of an edentulous maxilla and treat the patients with few hopeless elements before the procedure with remediation and delivery of a temporary immediate total prosthesis;
- prescribe an initial orthopantomography to the patient;
- take alginate impressions for the construction of occlusal rim, in order to produce a total diagnostic prosthesis correct from an aesthetic and functional point of view.

Once it was clear that a patient could be included in

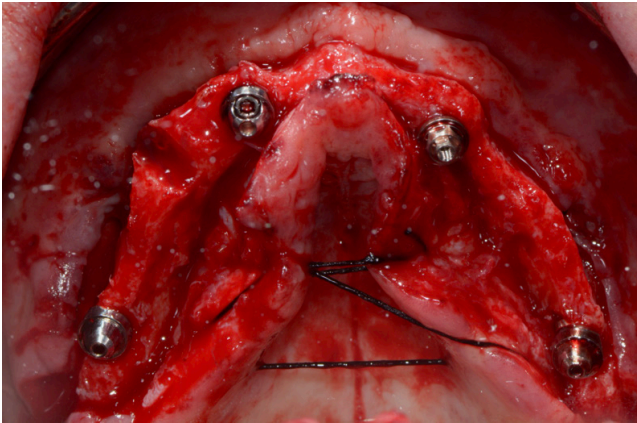


Fig. 1 Open flap surgery (traditional protocol).

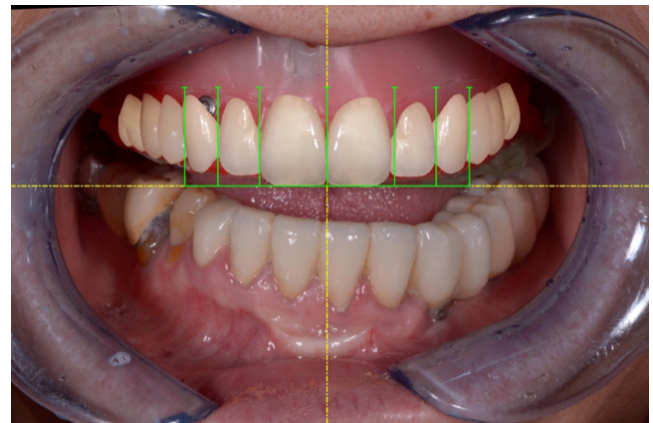


Fig. 2 Bidimensional digital project.

the clinical protocol, he/she signed a specific Informed Consent document for implant surgery with immediate loading. Before the next session, the patients were divided into two groups through a randomization process: 25 patients underwent the digital protocol, and the remaining 25 underwent the traditional protocol. Randomization processes occurred by lots in closed envelopes and were performed by a blinded operator.

During the second appointment:

- the patient underwent a professional oral hygiene session of the antagonist arch;
- the photos of the edentulous jaw were taken;
- the wax wall was "functionalized" using a traditional method;
- a Cone Beam CT was prescribed: in the case of a digital method, it was performed with the functionalized wall and a radiopaque reference marker for radiographic evaluation (Scan Marker 3DIEMME, Milan, Italy).

As for the traditional protocol, the third visit:

- denture structure and functionality test;
- aesthetic and phonetic evaluation test;
- one-dimensional VRS scale for the assessment of the patient's appreciation of the aesthetic test (1-very effective, 2-effective, 3-ineffective).

As for the traditional protocol, in the fourth appointment, we went to the surgical phase, with subsequent immediate loading prosthesis. One hour before the procedure 2g of amoxicillin + clavulanic acid were administered to the patient, who continued to assume (1g twice a day) for the week following the intervention as a post-surgical prophylaxis.

After local anesthesia, an incision was made in the center of the ridge alongside the entire length of the ridge, from the area of the first molar to the area of the first contralateral molar, with bilateral discharge incisions; The oral surgeon then performed a subperiosteal dissection and a bone remodeling, if necessary to obtain

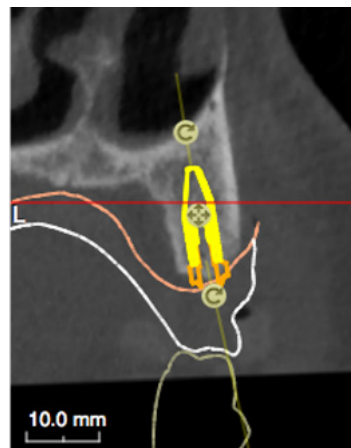


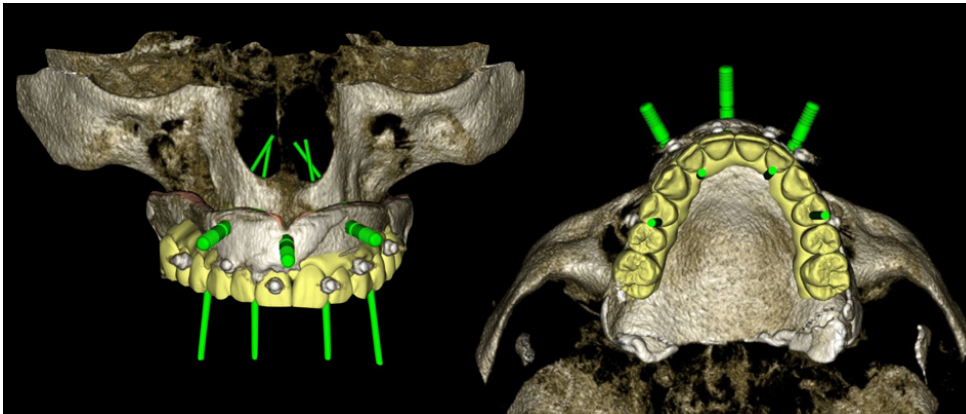
Fig. 3 Virtual positioning of the implants, based on the aesthetic prosthetic project.

a uniformly leveled bone crest. The two-implant fixtures were inserted in the posterior sector, tilted by about 30 - 35 degrees relative to the occlusal plane. Then the two axial fixtures were carried out in the anterior sector (Figure 1). Only Winsix TTx implants (Biosafin S.R.L., Ancona - Italy), diameter 3.3 or 3.8 (Tab. 1) were used.

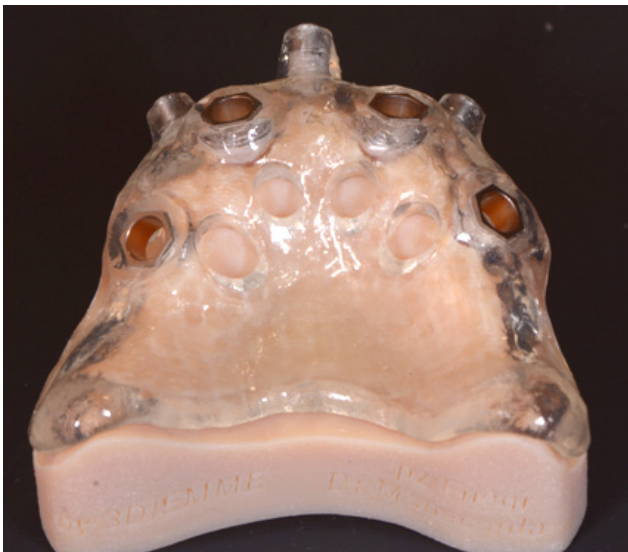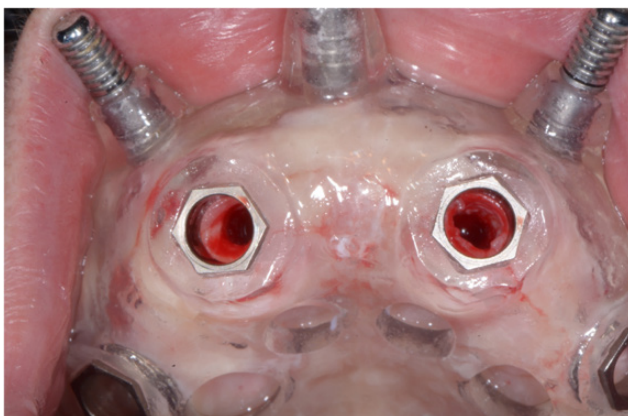
In the presence of bone with a well-represented trabecular portion, an under-preparation has been performed, to obtain a high primary stability, necessary for the subsequent immediate loading. The insertion torque range of all implants was 35-55 N / m. EATx WinSix extreme abutments (Biosafin S.R.L., Ancona - Italy) of 0 °, 17 ° or 30 ° were screwed in, in order to compensate for the lack of parallelism between the implants; the angle was chosen to obtain the position of the screw access hole at the occlusal or lingual level of the prosthesis. The access flap was adapted and sutured with non-absorbable 4-0 sutures; At the end of the surgery, the temporary prosthesis, previously made, was directly adapted and relined directly into the patient's mouth and polished in the on-site laboratory, to obtain immediate loading of the implants.

As for the digital protocol, the third visit included:

- test of the occlusal rim, that was previously

**Fig. 4**

Virtual positioning of the implants, based on the aesthetic prosthetic project.

**Fig. 5** Surgical guide on the stereolithographic model.**Fig. 6** Surgical template in the oral cavity and implant positioning.

functionalized according to traditional phonetic and aesthetic criteria.

- The execution of the specific photographic protocol for digital planning, including intraoral and extraoral photos of the patient (with a specific measurement marker);
- the realization of a two-dimensional digital project

of the new smile (smile design) using the Smile Lynx software (8853 S.P.A. - Milan, Italy) (Figure 2);

- V.R.S. one-dimensional scale for assessing the patient's appreciation of the computerized pre-visualization of the prosthetic project.

Between the third and fourth appointments of the digital protocol, we proceeded with:

- producing the scans of the edentulous model and the occlusal rim using a laboratory scanner (with and without Scan Marker);
- matching of the 2D digital project and scans within the Lynx CAD design software (8853 S.P.A. - Milan, Italy), thus allowing the three-dimensional design of the prosthesis;
- the provisional total prosthesis complete with the palatal portion was milled in PMMA (Poly(methyl methacrylate)) by a five-axis CAD/CAM milling machine.

A fourth visit followed, which provided for the oral test of the mock-up (temporary prosthesis in PMMA), with a relative one-dimensional VRS scale for the patient's assessment of the appreciation of the mock-up test.

A specific device with the radiographic landmark (Evo-Bite with 3D-Marker, 3DIEMME, Como, Italy) was then adapted to the prosthesis directly in the oral cavity with radio transparent silicon and delivered to the patient at the end of the appointment for the radiological exam. Various scans were then acquired with the same spatial coordinates: one of the stereolithographic model alone, one of the temporary prosthesis placed on the model and one of the prosthesis on the model with the Evo bite positioned on it (3D-Marker, 3DIEMME, Como, Italy). A CBCT (Cone Beam Computed Tomography) was prescribed to the patient. This exam had to be taken with the patient wearing the temporary prosthesis with the Evo-Bite positioned on it, including an additional radiopaque marker to be used as a reference for the following radiologic evaluation (Scan Marker, 3DIEMME, Como, Italy) (Figure 3, Figure 4).

Using the RealGuide Implant Design Software (3DIEMME, Milan, Italy), the Digital Imaging and Communications

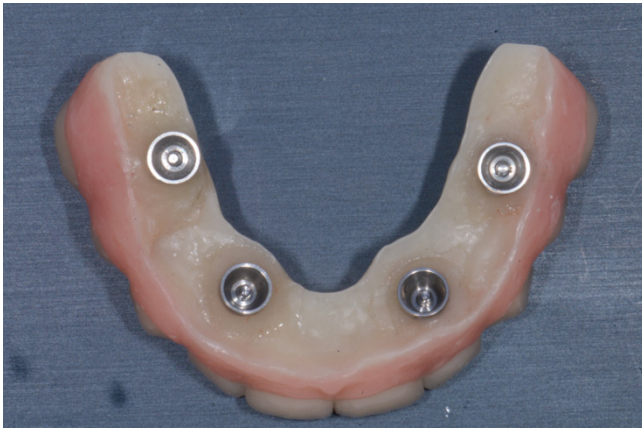

Fig. 7 Adapted, relined and refined provisional prosthesis.

in Medicine (DICOM) data of the patient's CBCT was then matched within the STL data of the previously mentioned scans, and the virtual position of the implants was planned, based on the aesthetic prosthetic project (Figure 5, Figure 6). The implant project was then sent to the laboratory for the realization of the stereolithographic model, which reported the exact sites for the placement of the analogs, and the surgical guide (3DIEMME, Milan, Italy).

During the fifth appointment (digital protocol), we proceeded to the surgical phase and immediate loading prosthesis:

An hour before the surgery, 2g of amoxicillin + clavulanic acid were administered to the patient, which he continued to assume for the week following the intervention (1g twice a day). After local anesthesia, the surgical template was positioned and fixed in the patient's oral cavity (Figure 7). We continued with the insertion of the implants through the surgical guide, with the flapless technique, using a preordained sequence of drills dedicated to guided surgery (Figure 8). The two-implant fixtures were inserted in the posterior sector, tilted by about 30 - 35 degrees relative to the occlusal plane. Then the two axial fixtures were carried out in the anterior sector. Only Winsix TTx implants (Biosafin S.R.L., Ancona - Italy), diameter 3.3 or 3.8 (Tab. 1) were used. All implants were inserted with 35-55 N / m torque. The EATx WinSix extreme abutments (Biosafin SRL, Ancona - Italy) of 0 °, 17 ° or 30 ° were screwed on, previously selected according to the prosthetic-implant project within the specific software for guided surgery, to compensate for the lack of parallelism between implants; the angle was chosen to obtain the position of the screw access hole at the occlusal or lingual level of the prosthesis. Immediate loading was performed, positioning the complete temporary denture of the palatal portion, made with the CAD-CAM method, adapted and relined directly into the patient's oral cavity (Figure 9, Figure 10).

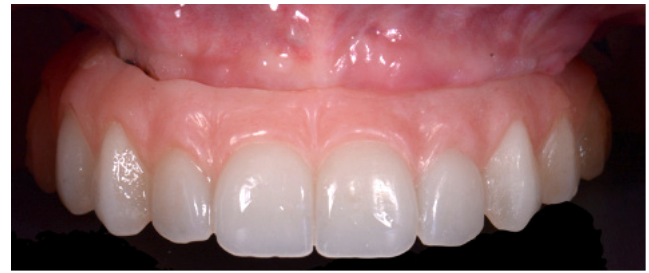

Fig. 8 Provisional prosthesis screwed in the patient's mouth.

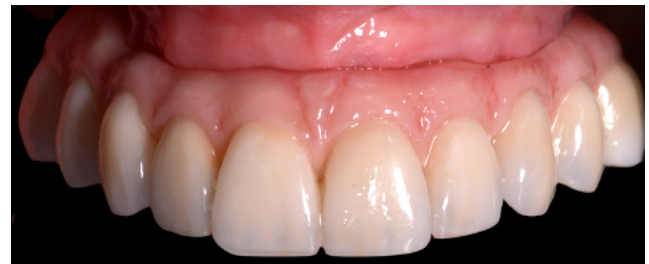
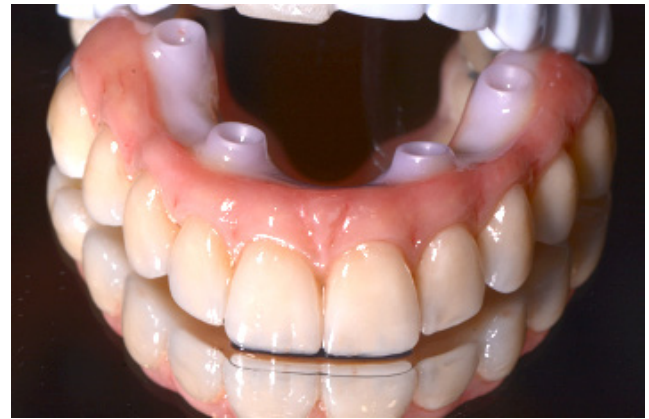
Fig. 9/10 Monolithic zirconia final prosthesis.

After all the surgical-prosthetic procedures, a VAS scale was submitted to both groups to evaluate pain (pre-during-post surgery). Four months after the surgery, an impression was taken. For the traditional group, impressions were taken using a conventional method, while for the digital group an intraoral scanner was used. The impression transfers were screwed over the fixtures and the impression material used was Impregum (Impregum Penta, 3M Italy, Pioltello, Italy). For the

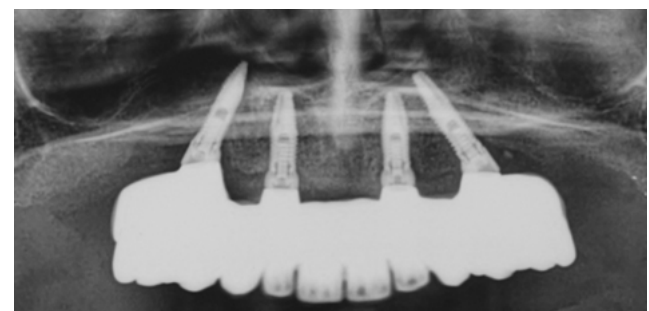


Fig. 11 Final orthopantomography.

scans the scanning bodies (for Ttx, Winsix, Biosafin S.R.L., Ancona, Italy) were screwed over the equipment and splinted together. The intraoral scanner used was a Carestream CS 3500 (Version 2.5 Acquisition Software, Care stream Dental LLC, Atlanta, GA, USA). Monolithic zirconium final prostheses with vestibular ceramization were delivered using CAD-CAM technology in both groups. A final orthopantomography was prescribed to the patient (Figure 11).

Follow-up

The clinicians visited the patients during follow-up appointments at 12, 24, 36, 48, 60 and 72 months after the placement of the implants. These appointments provided for radiographic analysis for the evaluation of marginal bone loss. The intraoral radiographs were made with a parallel long cone technique, performing the radiography perpendicular to the longitudinal axis of the implant, using a custom occlusal model to measure the level of the marginal bone. It was then possible to measure the difference in bone level through specific software (DIGORA 2.5, Soredex, Tuusula, Finland), calibrated for each image using the implant diameter calculated on the most coronal portion of the implant neck. The linear distance between the most coronal point of the B.I.C. (bone-implant contact) and the coronal margin of the implant neck was measured on both mesial and distal sides, at the value closest to 0.01 mm, and then a mean value was calculated. Besides, professional oral hygiene procedures were performed six months after implant placement and every four months after that to reduce risk of infection and inflammation of peri-implant tissues (10-14).

Statistical Analysis

Dedicated software (Prism 8.1.2, GraphPad) was used for statistical analysis, and peri-implant bone level measurements were reported as mean \pm standard deviation values at 12, 24, 36, 48, 60, and 72 months; through the one-way ANOVA test ($P < .05$), peri-implant bone loss was compared between the two groups at each time interval (12, 24, 36, 48, 60, 72 months) and within each group by analyzing each time stage with the following ones.

RESULTS

A total of 200 Winsix TTx implants (Biosafin SRL, Ancona - Italy) of diameter comprised between 3.3 or 3.8 mm. 100 of them were used in 25 cases of full-arch rehabilitations performed with the traditional All on Four method. The other 100 implants were used in 25 cases of full-arch rehabilitations performed with the digital method (Table 1). All patients received a temporary denture and, after 6 months from the procedure, a definitive prosthetic device. All implants were inserted at a torque of at least 35 Ncm and were subjected to immediate loading.

Implant Failure and Complications

Among the patients rehabilitated according to the traditional protocol, during the first 4 months after implant insertion, 2 failures were recorded, one in the upper maxilla and one in the lower maxilla, both concerning tilted implants (Table 2). The implant fixtures were replaced immediately without compromising the prosthetic function. 100% implant survival was achieved in patients rehabilitated according to the digital protocol. A patient treated with the traditional protocol showed discomfort, pain, swelling and the presence of pus three months after surgery, while no episode of peri-implantitis, pain, paresthesia or pus was observed among the patients rehabilitated according to the digital protocol. Two fractures of the provisional prosthetic device were recorded for each group.

Occlusal screw loosening of provisional prosthesis was observed in five cases: three were treated with the traditional method and two with the digital method. In the definitive prostheses, three unscrewing was reported in rehabilitations performed with the traditional method and four unscrewing in digitally treated patients. At 12 months, a case of chipping of the definitive device obtained using the traditional method was found; at 24 months a case of chipping of a definitive prosthesis obtained by the digital method was observed. In both cases, direct repair of the existing prosthesis was performed. Implant failures and complications were in the following table (Table 3).

Marginal bone loss

The marginal bone level was recorded during follow-up at 12, 24, 36, 48, 60 and 72 months (Table 4) through radiographic evaluation. As for patients treated with the traditional protocol, the loss of peri-implant crestal bone over time has remained constant. At 72 months the mean value for bone loss for axial implants in the maxilla was 1.12 ± 0.32 mm ($n = 30$), 1.15 ± 0.24 mm for tilted implants in the maxilla ($n = 30$), 1.09 ± 0.26 for axial implants in the jaw ($n = 20$) and 1.14 ± 0.24 for jaw tilted implants ($n = 20$) (Tab. 4). Bone loss in patients treated with the digital protocol at 72 months was 0.84 ± 0.11 mm for axial jaw implants ($n = 34$), 0.87 ± 0.10 mm for tilted jaw implants ($n = 34$), 0.85 ± 0.13 mm for axial implants in the mandible ($n = 16$) and 0.85 ± 0.10 mm for tilted implants in the mandible ($n = 16$) (Tab. 4). The difference in the Marginal Bone Level between the two groups was statistically significant ($P < .0001$) in each time interval. The difference within each group in the different time intervals was significant between the average MBL of the digital group at 12 months compared to the same group at 36 months ($P = .0066$), 48 months ($P < .0001$), 60 months ($P < .0001$) and 72 months ($P < .0001$).

Patients acceptance

Patients treated with the traditional protocol considered immediate loading with a temporary prosthesis to be

Implants' diameters (D) and lengths (L)					
			L 11 mm	L 13 mm	L 15 mm
Traditional protocol (n = 100)	Maxilla (n = 60)	D 3.3	0	16	0
		D 3.8	0	27	17
	Mandible (n = 40)	D 3.3	0	12	0
		D 3.8	0	19	9
Digital protocol (n = 100)	Maxilla (n = 68)	D 3.3	6	14	0
		D 3.8	12	32	6
	Mandible (n = 32)	D 3.3	0	6	0
		D 3.8	4	22	0

Table 1. Dental implants features.

Implants survival rate					
			Implants placed	Implants failed	Implants survival rate (%)
Traditional protocol					
Maxilla (n = 60)	Axial		30	0	100 %
	Tilted		30	1	96.67 %
Mandible (n = 40)	Axial		20	0	100 %
	Tilted		20	1	95.00 %
Digital protocol					
Maxilla (n = 68)	Axial		34	0	100 %
	Tilted		34	0	100 %
Mandible (n = 32)	Axial		16	0	100 %
	Tilted		16	0	100 %

Table 2. Implant survival rate.

very effective (95%). As for the tooth test, 45% of the patients considered it very effective, 37% effective, and 18% expressed a neutral opinion. Traditional surgery was rated as very effective by 71% of patients and effective for the remaining 29% (Tab. 5). Patients treated with the digital protocol considered digital smile previsualization (93%), mock-up test (98%), guided surgery (94%), and immediate loading (92%) to be very effective (Table 5). At the end of the surgical procedures and after seven days, a visual analog scale (V.A.S.) was submitted to the patients for the evaluation of postoperative pain, with values from 0 (absent pain) to 10 (the maximum possible pain). All patients belonging to the group treated with the digital method, which provides flapless surgery, reported a significantly lower value of pain compared to patients treated with the traditional method.

DISCUSSION

The purpose of this study is to evaluate and compare the success of prosthetic implant rehabilitation performed using a digital protocol with the traditional "All on Four" technique, which has been extensively validated by numerous studies in the literature (9, 15, 16). Full-arch implant-prosthetic rehabilitations

have been shown to be effective even in patients with compensated systemic diseases, according to several authors (23-26).

The initial phase of the digital design for an implant-prosthetic rehabilitation begins with the use of Smile Design software. This tool allows for the creation of a two-dimensional projection of the patient's future smile, providing several significant advantages. Chief among these is the improved interaction between specialists and patients, which leads to a higher quality of treatment (26). The current technological advancements enable the transition from a two-dimensional smile pre-visualization to a comprehensive three-dimensional volumetric study. By leveraging CAD-CAM technology, clinicians can fabricate definitive prostheses that have shown to achieve excellent results, comparable to those produced using traditional methods (27).

The Fifth Consensus Conference of the European Association of Integration has recognized the overlapping of photographs, models, and scans as a valid methodology (27). This digital planning process, which combines project data with information obtained through Cone Beam Computed Tomography (CBCT), facilitates the precise realization of prosthetic devices. Studies conducted by Schneider et al. in 2009 and

Implant failures and complications																								
		Traditional method												Digital Method										
Months	12		24		36		48		60		72		12		24		36		48		60		72	
	n	%	n	%	n	%	n	%	n	%	n	%	n	%	n	%	n	%	n	%	n	%	n	%
Implant Failure	2	2%	0	0	0	0	0	0	0	0	0	0	0	0	0	0	0	0	0	0	0	0	0	0
Perimplantitis	1	1%	0	0	0	0	0	0	0	0	0	0	0	0	0	0	0	0	0	0	0	0	0	0
Fractures of fixture	0	0	0	0	0	0	0	0	0	0	0	0	0	0	0	0	0	0	0	0	0	0	0	0
Unscrewing	3	3	1	1	0	0	1	1	0	0	1	1	2	2	1	1	1	1	1	1	1	1	1	1
Provisional prosthetic fractures	2	n.a.	/	/	/	/	/	/	/	/	/	/	2	n.a.	/	/	/	/	/	/	/	/	/	/
Definitive prosthetic fractures	1	n.a.	0	0	0	0	0	0	0	0	0	0	2	n.a.	0	0	0	0	0	0	0	0	0	0
Episodes of pus	1	n.a.	0	0	0	0	0	0	0	0	0	0	0	0	1	n.a.	0	0	0	0	0	0	0	0
Pain	1	n.a.	0	0	0	0	0	0	0	0	0	0	0	0	0	0	0	0	0	0	0	0	0	0
Paresthesia	0	0	0	0	0	0	0	0	0	0	0	0	0	0	0	0	0	0	0	0	0	0	0	0

Table 3. Implants failure and complications.

Marginal Bone loss							
		12 months	24 months	36 months	48 months	60 months	72 months
Traditional method							
		mm	mm	mm	mm	mm	mm
Maxilla	Axial (n=30)	1.02 ± 0.33	1.08 ± 0.34	1.10 ± 0.32	1.11 ± 0.32	1.11 ± 0.31	1.12 ± 0.32
	Tilted (n=30)	1.05 ± 0.27	1.08 ± 0.26	1.11 ± 0.25	1.13 ± 0.24	1.14 ± 0.25	1.15 ± 0.24
Mandible	Axial (n=20)	1.04 ± 0.28	1.05 ± 0.26	1.06 ± 0.26	1.08 ± 0.25	1.08 ± 0.25	1.09 ± 0.26
	Tilted (n=20)	1.05 ± 0.29	1.09 ± 0.25	1.12 ± 0.23	1.13 ± 0.23	1.14 ± 0.24	1.14 ± 0.24
Total	n=100	1.04 ± 0.29	1.08 ± 0.28	1.10 ± 0.27	1.12 ± 0.26	1.11 ± 0.26	1.12 ± 0.25
Digital method							
Maxilla	Axial (n=34)	0.65 ± 0.10	0.72 ± 0.13	0.76 ± 0.11	0.80 ± 0.10	0.83 ± 0.10	0.84 ± 0.11
	Tilted (n=34)	0.69 ± 0.11	0.78 ± 0.11	0.81 ± 0.11	0.85 ± 0.10	0.86 ± 0.10	0.87 ± 0.10
Mandible	Axial (n=16)	0.69 ± 0.19	0.73 ± 0.16	0.79 ± 0.14	0.82 ± 0.15	0.83 ± 0.15	0.85 ± 0.13
	Tilted (n=16)	0.71 ± 0.14	0.77 ± 0.11	0.80 ± 0.10	0.84 ± 0.10	0.84 ± 0.11	0.85 ± 0.10
Total	N=100	0.68 ± 0.13	0.75 ± 0.13	0.79 ± 0.11	0.83 ± 0.11	0.84 ± 0.11	0.88 ± 0.10

Table 4. Marginal bone level.

Vinci et al. in 2020, along with other researchers, have demonstrated the efficacy and accuracy of computer-assisted implant surgery (28-29). Moreover, the digital procedure offers the advantage of planning interventions that allow for the insertion of implants without flaps and with immediate loading. This approach has been shown to reduce post-operative pain compared to traditional open flap procedures (30,31).

In this study, mucosal-supported surgical templates were utilized. Gallardo et al. in 2016 and Vinci et al. in 2020 confirmed the predictability of this method for implant placement (32,33). Despite its advantages, guided surgery has several disadvantages as noted by Schneider et al. in 2009, Vinci et al. in 2020, and D’Haese et al. in

2009 (30-31-33). Potential issues include the risk of bone damage due to insufficient irrigation, the inability to visualize surgical anatomical landmarks, an increased risk of errors in implant positioning with greater degrees of maxillary bone atrophy, a discrepancy between the virtual plan and the actual position of the implant in the oral cavity post-surgery, and challenges in positioning the surgical template during both the CBCT scan and the surgical procedure.

However, the accuracy and predictability of intraoral scanners for implant full-arch rehabilitations have been demonstrated by numerous authors, making digital impressions a viable alternative to traditional analog techniques (34, 35). The findings of this study reveal

Patient acceptance			
	Very effective	Effective	Neutral
Traditional method			
Tooth test	45%	37%	18%
Traditional surgery	71%	29%	0%
Immediate loading	95%	5%	0%
Digital method			
Digital smile pre-visualisation	93%	7%	0%
Mock-up	98%	2%	0%
Guided surgery	94%	6%	0%
Immediate loading	92%	8%	0%

Table 5. Patients acceptance level.

that peri-implant bone loss levels are similar to those reported in existing literature for both the experimental and control groups (15, 36). This indicates that a fully digital protocol can serve as a valid therapeutic alternative to the traditional protocol. Nonetheless, it is essential to consider the contraindications mentioned earlier. Successful outcomes are contingent upon the careful selection of clinical cases and the appropriate assessment of which method—digital or traditional—is most suitable for each individual patient.

Furthermore, the digital approach introduces a level of customization and precision that can enhance the overall patient experience. The ability to pre-plan and simulate the final outcome allows patients to visualize the expected results, thereby increasing their confidence and satisfaction with the treatment process. This pre-visualization can also facilitate better communication between the clinician and the patient, ensuring that expectations are aligned and that any concerns are addressed prior to the actual procedure.

In addition to patient satisfaction, the efficiency of digital workflows should not be overlooked. The integration of digital tools can streamline the treatment process, potentially reducing the time required for procedures and minimizing the number of visits needed. This efficiency not only benefits patients by reducing inconvenience but also allows clinicians to optimize their practice and manage more cases effectively.

Despite these benefits, it is critical to acknowledge that the success of digital protocols heavily depends on the clinician's expertise and familiarity with the technology. Continuous education and training are necessary to stay abreast of technological advancements and to ensure that the digital tools are used to their full potential. Moreover, the initial investment in digital equipment and software can be significant, and practices must weigh these costs against the long-term benefits and improvements in patient care.

The potential for complications and the necessity for

precise execution highlight the importance of selecting appropriate cases for digital protocols. Not all clinical scenarios may be suitable for a fully digital approach, and traditional methods may still be preferable in certain situations. Thus, a hybrid approach that leverages the strengths of both digital and traditional techniques may offer the best outcomes for patients.

In this context, it becomes evident that digital implant-prosthetic rehabilitation is not a one-size-fits-all solution. The clinician must exercise judicious decision-making in identifying cases that will benefit most from digital techniques. For instance, patients with complex anatomical challenges or significant bone loss might benefit more from a traditional approach where tactile feedback during surgery plays a crucial role. Conversely, patients requiring high aesthetic outcomes with precise implant positioning might be better suited for a digital workflow.

Additionally, the role of interdisciplinary collaboration cannot be understated. Prosthodontists, oral surgeons, and dental technicians must work in tandem to harness the full potential of digital technologies. This collaborative approach ensures that each step of the rehabilitation process, from initial planning to final prosthesis delivery, is optimized for the best possible patient outcomes.

Future research should focus on long-term outcomes of digital versus traditional implant-prosthetic rehabilitations, examining not only clinical success rates but also patient-reported outcomes such as comfort, aesthetics, and overall satisfaction. Such studies will further elucidate the advantages and limitations of digital protocols, providing a clearer framework for their application in clinical practice.

CONCLUSION

In conclusion, taking into account the limitations of this study mainly due to the short follow-up, it would seem that the use of digital technology for the planning and realization of the rehabilitation of an entire arch can be a valid alternative to the protocol "All On Four". However, we must keep in mind that not all patients are suitable for this technique and that the success of this procedure also depends on the skill of the clinician, in fact, you must have a wide knowledge and mastery of topographical anatomy, radiographic imaging and surgical techniques. In addition, studies with a longer follow-up are needed to assess their real effectiveness and it is hoped that with the passage of time and the evolution of technologies, a digital workflow as described can be further simplified and increasingly within the reach of each clinician.

Author Contributions

Conceptualization, E.G. and F.C.; methodology, R.V. and M.M.; validation, E.G.; supervision, F.C.; resources, M.M.; data curation, F.C. and L.C.; writing—editing, A.B. and L.C.; review and editing, A.B. and L.C.. All authors

have read and agreed to the published version of the manuscript.

Funding

This research received no external funding.

Institutional Review Board Statement

The study was conducted in accordance with the

Declaration of Helsinki and approved by the Institutional Review Ethics Committee of Vita-Salute San Raffaele University, Dental School Department of Dentistry IRCCS San Raffaele Hospital, Milan, 20132, Italy.

Informed Consent Statement

Informed consent was obtained from all subjects involved in the study.

REFERENCES

- D'Orto B, Chiavenna C, Leone R, Longoni M, Nagni M, Capparè P. Marginal Bone Loss Compared in Internal and External Implant Connections: Retrospective Clinical Study at 6-Years Follow-Up. *Biomedicines*. 2023 Apr 8;11(4):1128. doi: 10.3390/biomedicines11041128.
- Di Stefano DA, Gastaldi G, Vinci R, Polizzi EM, Cinci L, Pieri L, Gherlone E. Bone Formation Following Sinus Augmentation with an Equine-Derived Bone Graft: A Retrospective Histologic and Histomorphometric Study with 36-Month Follow-up. *Int J Oral Maxillofac Implants*. 2016 Mar-Apr;31(2):406-12. doi: 10.11607/jomi.4373.
- Tetè G, Polizzi E, D'orto B, Carinci G, Capparè P. How to consider implant-prosthetic rehabilitation in elderly patients: A narrative review. *Journal of Biological Regulators and Homeostatic Agents*. 2021, 35(4), 119-126. doi:10.23812/21-4supp1-11.
- Akça BS, Kucukkurt S. Comparison of the Rehabilitation of Posterior Atrophic Edentulous Mandible with Different Interforaminal Implant Placement Concepts: A 3D Finite Element Analysis. *Journal of Osseointegration*. 2023, 15(3), 155-164. <https://doi.org/10.23805/JO.2023.560>.
- Kucukkurt S, Konuklu R, Çelikkol Ş. Is it beneficial to support interforaminal implant placement techniques with ultra-short implants in the posterior region? A 3D finite element analysis. *Journal of Osseointegration*. 2023, 15(2), 95-104. <https://doi.org/10.23805/JO.2023.15.01.11>.
- Capelli M, Zuffetti F, Del Fabbro M, Testori T. Immediate rehabilitation of the completely edentulous jaw with fixed prostheses supported by either upright or tilted implants: A multicenter clinical study. *Int. J. Oral Maxillofac. Implant*. 2007, 22, 639-644.
- Hinze M, Thalmair T, Bolz W, Wachtel H. Immediate loading of fixed provisional prostheses using four implants for the rehabilitation of the edentulous arch: A prospective clinical study. *Int. J. Oral Maxillofac. Implant*. 2010, 25, 1011-1018.
- Capparè P, Tetè G, D'Orto B, Nagni M, Gherlone EF. Immediate Loaded Full-Arch Mandibular Rehabilitations in Younger vs. Elderly Patients: A Comparative Retrospective Study with 7-Year Follow-Up. *J Clin Med*. 2023 Jul 6;12(13):4524. doi: 10.3390/jcm12134524.
- Nagni M, Pirani F, D'Orto B, Ferrini F, Cappare P. Clinical and Radiographic Follow-Up of Full-Arch Implant Prosthetic Rehabilitations: Retrospective Clinical Study at 6-Year Follow-Up. *Appl. Sci*. 2023, 13, 11143. <https://doi.org/10.3390/app132011143>.
- Cattoni F, Tetè G, D'orto B, Bergamaschi A, Polizzi E, Gastaldi G. Comparison of hygiene levels in metal-ceramic and stratified zirconia in prosthetic rehabilitation on teeth and implants: a retrospective clinical study of a three-year follow-up. *J Biol Regul Homeost Agents*. 2021 Jul-Aug;35(4 Suppl. 1):41-49. doi: 10.23812/21-4supp1-4.
- Tetè G, Cattoni F, Polizzi E. Anti-discoloration system: a new chlorhexidine mouthwash. *J Biol Regul Homeost Agents*. 2021 Jul-Aug;35(4 Suppl. 1):113-118. doi: 10.23812/21-4supp1-10.
- Gherlone E, Polizzi E, Tetè G, Capparè P. Dentistry and Covid-19 pandemic: operative indications post-lockdown. *New Microbiol*. 2021 Jan;44(1):1-11.
- Polizzi E, Tetè G. Manual vs Mechanical Oral Hygiene Procedures: Has the Role of the Dental Hygienist in Phase 2 Post-lockdown Really Changed? *Oral Health Prev Dent*. 2020;18(1):1031-1037. doi: 10.3290/j.ohpd.b871059.
- Tetè G, D'orto B, Ferrante L, Polizzi E, Cattoni F. Role of mast cells in oral inflammation. *Journal of Biological Regulators and Homeostatic Agents*. 2021, 35(4), 65-70.
- Barone A, Covani U, Cornellini R, Gherlone E. Radiographic bone density around immediately loaded oral implants. *Clin Oral Implants Res*. 2003 Oct;14(5):610-5. doi: 10.1034/j.1600-0501.2003.00878.x.
- Schnitman PA, Wohrle PS, Rubenstein JE, DaSilva JD, Wang NH. Ten-year results for Brånemark implants immediately loaded with fixed prostheses at implant placement. *Int. J. Oral Maxillofac. Implant*. 1997, 12, 495-503.
- Makkad RS, Hamdani S, Agrawal A. Cone Beam Computed Tomography in Dentistry: Principle, Application & Diagnosis; Lap Lambert Academic Publishing: Saarbrücken, Germany, 2012.
- Jung RE, Schneider D, Ganeles J, Wismeijer D, Zwahlen A. Computer technology applications in surgical implant dentistry: A systematic review. *Int. J. Oral Maxillofac. Implant*. 2009, 24, 92-109.
- Joda T, Bragger U. Complete digital workflow for the production of implant-supported single-unit monolithic crowns. *Clin. Oral Implant. Res*. 2013, 25, 1304-1306.
- Coachman C, Calamita MA, Coachman FG, Coachman RG, Sesma N. Facially generated and cephalometric guided 3D digital design for complete mouth implant rehabilitation: A clinical report. *J. Prosthet. Dent*. 2017, 117, 577-586.
- Monaco C, Ragazzini N, Scheda L, Evangelisti E. A fully digital approach to replicate functional and aesthetic parameters in implant-supported full-arch rehabilitation. *J Prosthodont Res*. 2018 Jul;62(3):383-385. doi: 10.1016/j.jpjor.2017.10.005.
- Marradi F, Staderini E, Zimbalatti MA, Rossi A, Grippaudo CM, Gallenzi P. How to Obtain an Orthodontic Virtual Patient through Superimposition of Three-Dimensional Data: A Systematic Review. *Appl. Sci*. 2020, 10, 5354.
- D'Orto B, Tetè G, Polizzi E. Osseointegrated dental implants supporting fixed prostheses in patients affected by Sjögren's Syndrome: A narrative review. *J Biol Regul Homeost Agents*. 2020 Nov-Dec;34(6 Suppl. 3):91-93.
- Aghaloo T, Pi-Anfruns J, Moshaverinia A, Sim D, Grogan T, Hadaya D. The Effects of Systemic Diseases and Medications on Implant Osseointegration: A Systematic Review. *Int J Oral Maxillofac Implants*. 2019 Suppl;34:s35-s49. doi: 10.11607/jomi.19suppl.g3.
- Gherlone EF, Capparè P, Tecco S, Polizzi E, Pantaleo G, Gastaldi G, Grusovin MG. Implant Prosthetic Rehabilitation in Controlled HIV-Positive Patients: A Prospective Longitudinal Study with 1-Year Follow-Up. *Clin. Implant. Dent. Relat. Res*. 2016, 18, 725-734.
- Coachman C, Calamita M, Sesma N. Dynamic Documentation of the Smile and the 2D/3D Digital Smile Design Process. *Int. J. Periodontics Restor. Dent*. 2017, 37, 183-193.
- Hammerle CF, Cordaro L, Van Assche N, Benic GI, Bornstein M, Gamper F. Digital technologies to support planning, treatment and fabrication processes and outcome assessments in implant dentistry. summary and

- consensus statements. The 4th EAO consensus conference, 2015. *Clin. Oral Implant. Res.* 2015, 26, 97–101.
28. Almayah H, Hassa TA, Al-Jumaily HA, Al-Ghurabi ZH. Evaluation of marginal bone loss around SLActive implants by CBCT using different implant dimensions and surgical approaches: a clinical and radiological prospective study. *Journal of Osseointegration.* 2021, 14(1), 21–25. <https://doi.org/10.23805/JO.2021.14.1>.
29. Vinci R, Manacorda M, Abundo R, Lucchina A, Scarano A, Crocetta C, Muzio LL, Gherlone E, Mastrangelo F. Accuracy of Edentulous Computer-Aided Implant Surgery as Compared to Virtual Planning: A Retrospective Multicenter Study. *J. Clin. Med.* 2020, 9, 774.
30. Meloni SM, De Riu G, Pisano M, Cattina G, Tullio A. Implant treatment software planning and guided flapless surgery with immediate provisional prosthesis delivery in the fully edentulous maxilla. A retrospective analysis of 15 consecutively treated patients. *Eur. J. Oral Implantol.* 2010, 3, 245–251.
31. Komiyama A, Klinge B, Hultin M. Treatment outcome of immediately loaded implants installed in edentulous jaws following computer-assisted virtual treatment planning and flapless surgery. *Clin. Oral Implant. Res.* 2008, 19, 677–685.
32. Gallardo YNR, Da Silva-Olivio IRT, Mukai E, Morimoto S, Sesma N, Cordaro L. Accuracy comparison of guided surgery for dental implants according to the tissue of support: A systematic review and meta-analysis. *Clin. Oral Implant. Res.* 2017, 28, 602–612.
33. D'Haese J, Van De Velde T, Elaut L, De Bruyn H. A Prospective Study on the Accuracy of Mucosally Supported Stereolithographic Surgical Guides in Fully Edentulous Maxillae. *Clin. Implant. Dent. Relat. Res.* 2009, 14, 293–303.
34. Ferrari M, Tricarico MG, Cagidiaco MC, Vichi A, Gherlone EF, Zarone F, Sorrentino R. 3-Year Randomized Controlled Prospective Clinical Trial on Different CAD-CAM Implant Abutments. *Clin Implant Dent Relat Res.* 2016 Dec;18(6):1134–1141. doi: 10.1111/cid.12418.
35. Gherlone EF, Ferrini F, Crespi R, Gastaldi G, Capparé P. Digital Impressions for Fabrication of Definitive “All-on-Four” Restorations. *Implant. Dent.* 2015, 24, 125–129.
36. Krekmanov L, Kahn M, Rangert B, Lindstrom H. Tilting of posterior mandibular and maxillary implants of imprecise prosthesis support. *Int. J. Oral Maxillofac. Implant.* 2000, 15, 405–414.