

# The outcome of tilted distal implants immediately loaded under screw-retained cross-arch prostheses. A 5-year retrospective cohort study

► F. GIORDANO<sup>1</sup>, F. DI SPIRITO<sup>1\*</sup>, A. ACERRA<sup>1\*</sup>, A. RUPE<sup>3</sup>, G. CIRIGLIANO<sup>2</sup>, M. CAGGIANO<sup>1\*</sup>

<sup>1</sup>Department of Medicine, Surgery and Dentistry "Scuola Medica Salernitana" University of Salerno, Via S. Allende; 84081; Baronissi (Salerno), Italy

<sup>2</sup>Private Practitioner in Sala Consilina (Salerno), Italy

<sup>3</sup>Private Practitioner in Benevento, Italy

\*Corresponding authors

## TO CITE THIS ARTICLE

Giordano F, Di Spirito F, Acerra A, Rupe A, Cirigliano G, Caggiano M. The outcome of tilted distal implants immediately loaded under screw-retained cross-arch prostheses. A 5-year retrospective cohort study. *J Osseointegr* 2024; 16(1): 31-38.

DOI 10.23805/JO.2024.601

**KEYWORDS** Dental implants, immediate loading, fully edentulous jaws

## ABSTRACT

**Aim** The aim of this retrospective cohort study was to evaluate the clinical outcome of tilted distal implants immediately loaded with metal-resin screw-retained cross-arch fixed prostheses 5 years after loading.

**Material and Methods** One-hundred-seventy-six consecutive patients received four to six implants to be placed with a torque superior 35 Ncm. Two-hundred-nineteen metal-resin screw-retained fixed prostheses (120 mandibular and 98 maxillary) were to be delivered within 3 days. Implant failures and biological complications were evaluated by the treating clinician.

**Results** A total of 922 implants were placed, 407 of which were tilted distal implants. Two patients dropped-out (died). Five years after loading all patients were wearing fixed prostheses. Ten tilted distal implants failed in 9 (5.17%) patients versus six non-distal implants in five patients (2.87%). Fifty-one biological complications occurred at tilted distal implants in 42 patients (24.14%) versus 37 complications occurred at non-distal implants in 24 patients (13.79%).

**Conclusions** In conclusion, tilted distal implants have a double chance of failing or having biological complications when compared to mesial implants.

implants can be placed distal to the mental foramina if there is sufficient bone height above the mandibular canal (3).

In maxillae, the number of implants to be inserted may be limited by large pneumatized maxillary sinuses and by reduced bone volumes (4).

Distal implants can also be placed in a tilted or angulated position to position more distally the emergence of the implant neck, thus reducing the length of the cantilevered portion of the prosthesis (5-7).

The choice of a tilted implant often avoids regenerative bone augmentation surgery for implant placement (8,9).

In cases of maxillary sinus hyper-pneumatization, tilted implant insertion must be very precise to avoid the sinus, and computer-guided implant placement can also be done, ensuring accuracy and predictability of outcome, achieved through preoperative planning of the procedure (10,11).

However, the more implants are placed, the more costs and difficulties to fabricate precise metal frameworks to be passively seated on the implants. Implants can be loaded immediately after their placement without increasing too much the risk for failures, especially in fully edentulous mandibles but also in fully edentulous maxillae (12-15).

Distal angulated implants are potentially associated with some advantages and some risks that have been discussed for more than 30 years (16,17).

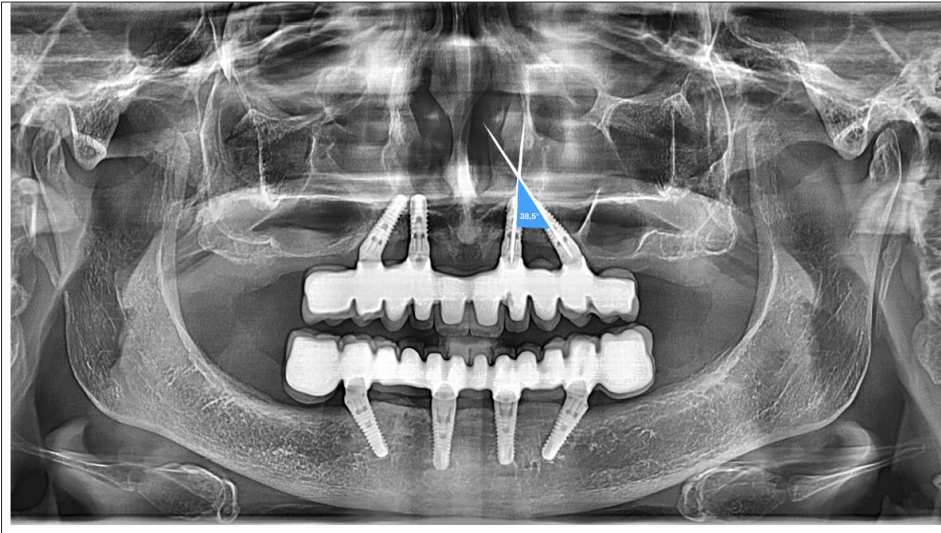
The potential advantages are that by emerging more distally, shorter cantilevers could be used, decreasing the risks of mechanical complications for the prosthesis (18).

In addition, longer implants could be placed by

## INTRODUCTION

Four to six implants are often placed to support fixed cross-arch prostheses in totally edentulous patients (1,2).

While it may be difficult to place more than four implants between the mental foramina without risking compromising oral hygiene procedures, more



**FIG. 1** Panoramic radiograph showing how distal angulated implants were defined to be eligible in the study. The angle formed by the two lines of the distal and its mesial implant had to form an angle superior to 15 degrees. This patient provided four angulated distal implants to the study.

angulating them. The potential risks are that implants subjected to non-axial loads might suffer more biomechanical (fractures) and biological (peri-implant bone loss) problems (19–21).

In addition, oral hygiene procedures could be more complicated, and these could be associated with a higher risk of peri-implant mucositis that could evolve into peri-implantitis and eventually implant loss.

The current conclusions of the literature so far support the view that angulated distal implants are not at higher risk for failures and complications, though statistically significantly higher failure rates of angulated implants were found in maxillae (22–24).

However, these results come from poorly conducted original studies summarized in poor-quality systematic reviews. Recently, the first randomized controlled trial has been published on this topic, unfortunately yet with a too short follow-up (25).

The trial showed no differences between the angulated or not angulated distal implants one year after loading.

Therefore, it would be interesting to know whether angulated distal implants under immediately loaded cross-arch prostheses could be at higher risk or not for failures and complications when compared to non-distal implants. In particular, it would be useful to evaluate implants with a follow-up function of at least 5 years.

This retrospective cohort study aimed to evaluate the clinical outcome of angulated distal implants immediately loaded under metal-resin screw-retained cross-arch fixed prostheses supported by four to six implants. The present article is reported according to the Strengthening the Reporting of Observational studies in Epidemiology (STROBE) guidelines ([www.strobe-statement.org](http://www.strobe-statement.org)).

## MATERIALS AND METHODS

Any angulated distal implant from edentulous patients rehabilitated with immediately loaded cross-arch implant-supported prostheses up to December 2017, was eligible for inclusion in this study. A distal implant was considered to be angulated if the angle formed by the line passing in its middle and the one of its mesial implant was more than 15 degrees, as visualized on panoramic radiographs (Fig. 1).

Patients needed to have bone volumes allowing the placement of four to six implants at least 11 mm long and with a diameter of at least 4.5 mm. Immediate post-extractive implants were included. Patients were not accepted into the study if any of the following exclusion criteria were present (Table 1).

EXCLUSION CRITERIA
<ul style="list-style-type: none"> <li>• general contraindications to implant surgery at the discretion of the surgeon;</li> <li>• cardio-vascular diseases over the previous 6 months;</li> <li>• immunodeficient or immunosuppressed patients;</li> <li>• patients with a glucose level above 150 mg/dl;</li> <li>• pregnancy or lactation;</li> <li>• irradiated in the head and/or neck in the previous 6 months;</li> <li>• treated or under treatment with intravenous amino-bisphosphonates;</li> <li>• poor oral hygiene and motivation;</li> <li>• an active infection or severe inflammation in the area intended for implant placement;</li> <li>• lack of opposing occluding dentition/prosthesis/dentures.</li> </ul>

**TABLE 1.** Exclusion criteria

Patients were categorized according to what they declared into three groups: non-smokers; moderate smokers (up to 10 cigarettes per day); and heavy smokers (more than 10 cigarettes per day). Patients were also classified according to the type of dentition in the opposite jaw (natural/fixed or full dentures).

Patients were treated by the same Author (F.G.) with extensive experience in immediate loading procedures.

Depending on the anatomical conditions, preliminary screening was performed on panoramic radiographs with patients wearing thermoplastic radiographic guides with small gutta-percha balls as reference points. When needed Cone-Beam computed tomography (CBCT) scans were taken still using the thermoplastic radiographic guide. Such guides were also used during surgery to facilitate ideal implant positioning position. All patients received professional oral hygiene prior to the operation and received prophylactic antibiotic therapy: 2 g of amoxicillin plus clavulanic acid orally one hour prior to the intervention. Patients with chronic infections at future implant sites, received 1 g of amoxicillin plus clavulanic acid three times a day starting 2 days before implant surgery. In the latter case or in case of complicated surgeries, the same antibiotic treatment was continued for 3 days after implantation. Patients allergic to penicillin were given 500 mg of clarithromycin 1 hour prior to the intervention. Patients rinsed with a chlorhexidine mouthwash 0.2% for 1 minute just prior to the intervention. All patients were sedated intravenously with a cocktail combining different drugs Local anesthesia was administered using mepivacaine with adrenaline 1:100,000 or 1:50,000. Crestal incisions were made and, in the presence of large bone volumes at implant sites, minimal flaps were elevated up to the coronal portion of the alveolar process. In the presence of reduced bone volumes, larger flaps were elevated exposing the mental foramina in mandibles or the prominence of the maxillary sinuses.

When present residual teeth/roots were carefully extracted to minimize damage to the buccal plate and sites were thoroughly cleaned from all granulation tissue. SPI-Contact (Thommen Medical; Grenchen, Switzerland) conical-cylindrical implants with a smooth 1.5 mm Long Collar were used mainly with a length of 11 mm and 4.5 mm in diameter. Implants were placed following the protocol suggested by the manufacturer except for the use of a 4.0 mm profile drill in order to underprepare the sites to achieve a higher insertion torque. Distal implants were distally tilted in premolar areas.

Implants were placed with the 1.5 mm polished neck in the supracrestal position, as well as in the case of post-extractive implants. Implants were inserted with the motor set with a torque of 70 Newton/cm

and once the motor stopped implant stability was confirmed manually using the SPI-MONO torque ratchet (Thommen). If one of the four placed implants could not be placed with a torque superior to 35 Ncm a fifth or a sixth implant was added near to the implant that did not achieve the required torque. If two or more implants could not achieve a torque above 35 Ncm, implants were submerged and loaded conventionally after 3 months.

To decrease possible interference with the peri-implant bone, a manual bone profiler was used, and healing abutments were placed. In the presence of buccal bone dehiscence/fenestrations, a layer of granular autogenous bone harvested using a bone-scraper (14620.10 Stoma; Emmingen-Liptingen, Germany) was laid to cover the exposed portion of the implant. The graft was covered with a second layer of an organic bovine bone (Bio-Oss, Geistlich, Wolhusen, Switzerland) and a double layer of a collagen resorbable barrier (Bio-Gide, Geistlich) was positioned on top of the graft and fixated with titanium pins (initially with Kalos, Orbetello, Italy and later with Smartact, Meta, Reggio Emilia, Italy). Healing abutments were positioned and single resorbable sutures (Vicryl 4-0 SH1 plus 22 mm 1/2c; Ethicon, New Brunswick, NJ, US) were placed.

After surgery, analgesics (ibuprofen 600 mg) were suggested to be taken twice a day during meals on patient demand. A soft diet was recommended for 45 days. Oral hygiene procedures were professionally implemented during the 3 following days necessary to prepare the prosthesis. Patients were instructed to avoid brushing at the surgical site and rinsing until suture removal, about 10 days after surgery. They were instructed to clean the prostheses with a gauze moistened with 0.2% chlorhexidine, then to use a soft and then medium toothbrush and finally the waterjet. Prosthetic procedures were initiated immediately after implant placement. Individual trays were used to take impressions and were perforated to allow their seating over the transfers. Impregum F (Espe Dental AG, Seefeld, Germany) was used as impression material. Definitive screw-retained prostheses were made by placing titanium abutments (VARIOtemp for fixed prostheses, Thommen) on the model which were connected using titanium rods of 2 mm diameter soldered with an argon syncrystallization device (WELDER INTRAORAL MIDI, Implamed, Cremona, Italy), an intraoral welder, to create a rigid framework. It was not necessary to use angulated abutments for tilted implants since the abutments tolerated substantial disparallelism between implants. The framework was covered by wax and 12 preformed resin teeth were added. On the second day, the framework was tried in the patient's mouth to check aesthetic, function and phonetic. It was then finalized with a lining in acrylic resin. Cantilevers including a maximum of one

premolar and one molar in extension per side were allowed. The cantilever length did not exceed 1.5 cm. On the third day after surgery, prostheses were screwed onto the implants using a standard torque of 25 Ncm and the screw households were sealed with gutta-percha. A panoramic radiograph was taken to check proper abutment seating on the implants. Prostheses were designed to have a group function occlusal scheme and were adjusted to have homogeneous occlusal contacts also on cantilevers, when present. Sutures were removed after approximately 10 days by cutting the knot and leaving the remaining portion of the absorbable suture inside the soft tissues to be spontaneously resorbed. Oral hygiene instructions were delivered. Patients were seen again after 1 and 3 months. At 3 months follow-up the prostheses were rebased. Patients were recalled for maintenance and occlusion was checked every six months when screw-retained prostheses were removed to check implant stability and to be cleaned.

In case of framework fracture or to prevent them, the original metal-resin prostheses were gradually replaced by newly made screw-retained monobloc white resin (top.lign professional, Bredent, Senden Germany) prostheses using a reinforced titanium framework, characterized externally by layers of enamel resin of various shades of pink and white colours (monolithic resin metal reinforced prostheses). The outcome measures evaluated for the present study were:

- Implant failure: the presence of any mobility of the individual implant and/or any infection dictating implant removal, and/or biomechanical complications (implant fracture or deformations of the connections) rendering the implant unusable. Individual implant stability was measured 1 month, 3 months after implant placement and thereafter every 6 months by removing the screw-retained prosthesis and rocking the implant with the handles of two instruments.
- Any biological complications such as hemorrhage, numbness of the lower lip and chin, peri-implant mucositis (inflammation of the peri-implant soft tissues without appreciable bone loss), peri-implantitis (inflammation of the peri-implant soft tissues with peri-implant bone loss), fistulas, etc.

This study was designed as a retrospective single cohort study aimed to include any patient having angulated distal implants treated with a fixed cross-arch prosthesis which were planned to be loaded immediately. No sample size calculation was performed. The patient was the statistical unit of the analyses. Descriptive statistics was used.

## RESULTS

One-hundred-seventy-six patients were consecutively recruited and treated from January 2014 to December

Patients' and interventions characteristics	Numbers
Females	106 (60.23%)
Mean age at implant insertion (range)	63.06 years (37-87)
Non-smokers	118 (67.05%)
Smoking up to 10 cigarettes/day	40 (22.73%)
Smoking more than 10 cigarettes/day	18 (10.23%)
Patients with a positive general anamnesis	27 (15.34%)
Patients wearing dentures in the opposite jaw at implant loading	23 (13.07%)
Total number of inserted implants	922
Implants inserted in mandibles (98 jaws)	396 (42.95%)
Implants inserted in maxillae (120 jaws)	526 (57.05%)
Angulated distal implants in mandibles	188 (46.19%)
Angulated distal implants in maxillae	219 (53.81%)
Angulated distal implants in extraction sockets	93 (31.96%)
Other implants in extraction sockets	198 (69.04%)
Angulated distal implants placed with a torque inferior or equal to 35 Ncm	19 (29.23%)
Other implants placed with a torque inferior or equal to 35 Ncm	46 (70.77%)
Angulated distal implants that caused fenestration/dehiscence of buccal bone	14 (50.00%)
Other implants that caused fenestration/dehiscence of buccal bone	14 (50.00%)
Total number of mandibles prostheses	98 (44.95%)
Total number of maxillary prostheses	120 (55.05%)

TABLE 2. Patients' and interventions characteristics (179 patients)

2017. Two-hundred-nineteen metal-resin screw-retained fixed prostheses (120 mandibular and 98 maxillary) were delivered on 922 implants (291 were post-extractive implants). There were 407 angulated distal implants (219 in mandibles and 188 in maxillae). The follow-up focused on the time between implant placement and 5 years after implant loading. Two patients dropped out because of death at 4 years after loading. The main baseline patient, site, and treatment characteristics are presented in Table 2. A total of 27 patients with various medical conditions and pathologies were included.

At the placement, 65 implants in 42 patients did not achieve

Patient number	Patient's characteristics	Implant position characteristics & failure timing	Symptoms
12	66 y.o. male, non-smoker	16 angulated 12 post-ex 23 post-ex	1* 1* 3* severe spontaneous pain severe spontaneous pain none
15	63 y.o. male, non-smoker	15 angulated	3* moderate pain on chewing
19	59 y.o. male, non-smoker	16 angulated post-ex	24* moderate pain on chewing, peri-implantitis
42	66 y.o. female, moderate smoker	22 post-ex, torque < 35 Ncm 25 angulated	3* 36* moderate pain on chewing none, peri-implantitis
47	59 y.o. male, non-smoker	42 post-ex 35 angulated post-ex 45 angulated post-ex	1* 1* 1* severe spontaneous pain severe spontaneous pain severe spontaneous pain
77	65 y.o. female, non-smoker	31 post-ex	3* none
86	48 y.o. female, moderate smoker	22 post-ex	3* moderate pain on chewing
104	65 y.o. female, non-smoker	45 angulated	12* none
122	77 y.o. female, moderate smoker	35 angulated post-ex	48* none
145	47 y.o. male, moderate smoker	45 angulated	36* moderate pain on chewing
146	66 y.o. female, non-smoker	16 angulated	12* none

\*Months post-loading. All patient had negative anamnesis.

TABLE 3. Description of the implant failures occurred up to 5-years post-loading

the minimal insertion torque required (above 35 Ncm). Twenty-three maxillary prostheses were conventionally loaded, because at least two implants could not be placed with a torque superior to 35 Ncm.

- Implant failures (Table 3): In total 16 implants failed in 11 patients and more specifically, 10 angulated distal implants failed in nine (5.17%) patients versus six non-distal implants in five patients (2.87%). Ten of the failed implants were placed in fresh extraction sockets, eight were placed in maxillae and 10 failed within 3 months after their placement.
- Biological complications (Table 4) were accounted for only in those implants that did not fail. Eighty-eight biological complications occurred in 52 patients and more specifically, 51 angulated distal implants in 42 patients (24.14%) had complications versus 37 non-distal implants in 24 patients (13.79%).

When focusing on the most severe biological complications, i.e. peri-implantitis, defined as progressive marginal bone at implants with inflamed peri-implant tissues, it affected 10 angulated distal implants in seven patients (4.12%) and 8 non-angulated distal implants in seven patients (4.12%). Implants affected by peri-implantitis were treated either with surgical or non-surgical debridement or implant removal.

## DISCUSSION

The present 5-year retrospective cohort study was

designed to evaluate whether angulated distal implants supporting fixed cross-arch prostheses could be at higher risk for failures and complications when compared to non-distal implants under the same prostheses. The findings of the present study are quite straightforward: angulated distal implants have a double chance of failing or having biological complications when compared to all other implants that are not angulated distal ones. Our findings are in contradictions with the conclusions of several systematic reviews, cohort studies, and the only RCT, however, our follow-up is longer and the sample size much more robust, and in some systematic reviews significantly higher failure rates were observed at angulated distal implants but only in maxillae and more peri-implant bone loss (19–22,25).

The differences in failure rates and complications observed in the present study between the distal angulated implant and the other implants could be explained by multiple factors, including higher masticatory forces exerted on posterior regions associated with more complex oral hygiene procedures for patients as demonstrated by the higher number of peri-implant mucositis affecting angulated distal implants (26). Most of the early implant failures (10 implants) affected immediate post-extractive implants (eight implants). This observation is in line with other studies, that showed trends for post-extractive implants to fail more often than delayed-placed implants (12,27–30). The number of implants affected by peri-implantitis was similar in both groups. Treatment of peri-implantitis consisted of close or open flap-debridement (31).

Patient number	Type of complication	Type of implant
1	Peri-implantitis at 32	Non-angulated distal
4	Peri-implant mucositis at 34	Angulated distal
5	Peri-implant mucositis at 34 Peri-implant mucositis at 44	Angulated distal Non-angulated distal
17	Peri-implant mucositis at 14 and 24	Angulated distal
22	Peri-implant mucositis at 32	Non-angulated distal
26	Peri-implantitis at 44	Angulated distal
33	Peri-implant mucositis at 45	Angulated distal
36	Peri-implantitis at 13 and 22	Non-angulated distal
41	Peri-implant mucositis at 44	Angulated distal
44	Peri-implant mucositis at 34 and 44 Peri-implant mucositis at 32 and 42	Angulated distal Non-angulated distal
46	Peri-implantitis at 35 and 45	Angulated distal
51	Peri-implant mucositis at 45	Angulated distal
53	Peri-implant mucositis at 34 Peri-implantitis at 42	Angulated distal Non-angulated distal
56	Peri-implant mucositis at 42	Non-angulated distal
58	Peri-implant mucositis at 15 and 25	Angulated distal
60	Peri-implant mucositis 32 and 42	Non-angulated distal
61	Peri-implant mucositis at 16	Angulated distal
62	Peri-implant mucositis at 25 Peri-implant mucositis at 13	Angulated distal Non-angulated distal
64	Peri-implantitis at 22	Non-angulated distal
66	Peri-implant mucositis at 15 Peri-implant mucositis at 11	Angulated distal Non-angulated distal
74	Peri-implant mucositis at 45	Angulated distal
77	Peri-implant mucositis at 44 Peri-implant mucositis at 31	Angulated distal Non-angulated distal
78	Peri-implantitis at 16 and 26	Angulated distal
79	Peri-implant mucositis 14 and 23	Non-angulated distal
82	Peri-implant mucositis at 34 Peri-implant mucositis at 32 and 42	Angulated distal Non-angulated distal
83	Peri-implant mucositis at 15	Angulated distal
84	Peri-implant mucositis at 15 and 25 Peri-implant mucositis at 12, 22, 24 and 32	Angulated distal Non-angulated distal
86	Peri-implantitis at 23	Non-angulated distal
87	Peri-implant mucositis at 15	Angulated distal
90	Peri-implant mucositis at 44	Angulated distal
91	Peri-implantitis at 34 and 44	Angulated distal
92	Peri-implant mucositis at 44 Peri-implant mucositis at 32 and 42	Angulated distal Non-angulated distal
94	Peri-implant mucositis at 15 and 23	Non-angulated distal
95	Peri-implant mucositis at 26 Peri-implant mucositis at 12 and 22	Angulated distal Non-angulated distal
97	Peri-implant mucositis at 16	Angulated distal
98	Peri-implant mucositis at 16 and 26 Peri-implant mucositis at 22	Angulated distal Non-angulated distal

TABLE 4. Description of biological complications occurred up to fifth year in function

99	Peri-implant mucositis at 26 Peri-implant mucositis at 22	Angulated distal Non-angulated distal
101	Peri-implant mucositis at 35	Angulated distal
103	Peri-implant mucositis at 14	Angulated distal
104	Peri-implantitis at 35	Angulated distal
106	Peri-implantitis at 45	Angulated distal
108	Peri-implant mucositis at 26	Angulated distal
109	Peri-implant mucositis at 25	Angulated distal
110	Peri-implant mucositis at 35	Angulated distal
114	Peri-implantitis at 12	Non-angulated distal
116	Peri-implant mucositis at 25	Angulated distal
120	Peri-implant mucositis at 26	Angulated distal
121	Peri-implant mucositis at 25	Angulated distal
144	Peri-implant mucositis at 16 and 26 Peri-implant mucositis at 13 and 21	Angulated distal Non-angulated distal
150	Peri-implant mucositis at 45 Peri-implant mucositis at 32 and 42	Angulated distal Non-angulated distal
153	Peri-implantitis at 15	Angulated distal
176	Peri-implant mucositis at 16	Angulated distal
<b>Totals</b>	<b>Totals</b>	
52 patients	88 implants affected by complications	
	<b>Angulated distal only</b>	
42 patients	51 implants affected by complications	
	<b>Non Angulated distal only</b>	
24 patients	37 implants affected by complications	

**TABLE 4** Description of biological complications occurred up to fifth year in function

Systemic antibiotics were not used due to the lack of clear evidence of their efficacy (32,33).

It is also important to stress that at the end of the 5-year follow-up period, all patients had their fixed prostheses in function. The major limitation of the present study is its retrospective design. If the goal of the study is to evaluate the outcome of distally angulated implants to reduce the length of prosthetic cantilevers, the comparison should be made with shorter axially placed implants, either positioned more distally or supporting longer cantilevers using a randomized controlled trial study design as done by Mohamed et al. (25).

In addition, these trials should present follow-ups of at least 5 to 10 years to provide clinically reliable information. On the other hand, in this study, treatments were delivered under normal clinical conditions, using broad patient inclusion criteria, therefore the results of this could be extrapolated to wider patient populations with similar characteristics.

## CONCLUSIONS

Angulated distal implants have a double chance of failing or having biological complications when compared to mesial implants.

## Author Contributions

Conceptualization, M.C. and F.G.; methodology, A.A.; validation, M.C., F.G. and F.D.S.; formal analysis, F.D.S.; investigation, A.A.; data curation, G.C.; writing—original draft preparation, M.C. and A.A; writing—review and editing, M.C. and F.G.; visualization, F.D.S. All authors have read and agreed to the published version of the manuscript.

## Funding

This research received no external funding  
Institutional Review Board Statement: This study was conducted according to the guidelines of the Declaration of Helsinki and approved by the Ethics Committee of Federico II University of Naples (05/03/2018; NO 347/18).

## Informed Consent Statement

Informed consent was obtained from all subjects involved in the study.

## Data Availability Statement

All generated or collected data were presented in the article.

## Acknowledgments

We are in debt to Prof. Marco Esposito for his suggestion on how to write this manuscript.

## Conflicts of Interest

The authors declare no conflict of interest.

## REFERENCES

- Brånemark PI, Hansson BO, Adell R, Breine U, Lindström J, Hallén O, Ohman A. Osseointegrated implants in the treatment of the edentulous jaw. Experience from a 10-year period. *Scand J Plast Reconstr Surg Suppl*. 1977;16:1-132.
- Pantaleo G, Acerra A, Giordano F, D'Ambrosio F, Langone M, Caggiano M. Immediate Loading of Fixed Prosthesis in Fully Edentulous Jaws: A 7-Year Follow-Up from a Single-Cohort Retrospective Study. *Applied Sciences*. 2022; 12(23):12427. .
- Sammartino G, Wang HL, Citarella R, Lepore M, Marenzi G. Analysis of occlusal stresses transmitted to the inferior alveolar nerve by multiple threaded implants. *J Periodontol*. 2013 Nov;84(11):1655-61. .
- Lim HC, Kim S, Kim DH, Herr Y, Chung JH, Shin SI. Factors affecting maxillary sinus pneumatization following posterior maxillary tooth extraction. *J Periodontal Implant Sci*. 2021 Aug;51(4):285-295.
- Aparicio C, Perales P, Rangert B. Tilted implants as an alternative to maxillary sinus grafting: a clinical, radiologic, and periotest study. *Clin Implant Dent Relat Res*. 2001;3(1):39-49..
- DE Vico G, Bonino M, Spinelli D, Schiavetti R, Sannino G, Pozzi A, Ottria L. Rationale for tilted implants: FEA considerations and clinical reports. *Oral Implantol (Rome)*. 2011 Jul;4(3-4):23-33..
- Romanos GE, Gupta B, Gaertner K, Nentwig GH. Distal cantilever in full-arch prostheses and immediate loading: a retrospective clinical study. *Int J Oral Maxillofac Implants*. 2014 Mar-Apr;29(2):427-31. .
- Caggiano M, D'Ambrosio F, Giordano F, Acerra A, Sammartino P, Iandolo A. The "Sling" Technique for Horizontal Guided Bone Regeneration: A Retrospective Case Series. *Applied Sciences*. 2022; 12(12):5889.
- Lang NP, Hämmerle CH, Brägger U, Lehmann B, Nyman SR. Guided tissue regeneration in jawbone defects prior to implant placement. *Clin Oral Implants Res*. 1994 Jun;5(2):92-7..
- Pomares C. A Retrospective Study of Edentulous Patients Rehabilitated According to the "all-on-Four" or the "All-on-Six" Immediate Function Concept Using Flapless Computer-Guided Implant Surgery. *Eur J Oral Implantol*. 2010, 3, 155-163.
- Caggiano M, Amato A, Acerra A, D'Ambrosio F, Martina S. Evaluation of Deviations between Computer-Planned Implant Position and In Vivo Placement through 3D-Printed Guide: A CBCT Scan Analysis on Implant Inserted in Esthetic Area. *Applied Sciences*. 2022; 12(11):5461.
- Esposito M, Grusovin MG, Maghaireh H, Worthington HV. Interventions for replacing missing teeth: different times for loading dental implants. *Cochrane Database Syst Rev*. 2013 Mar 28;2013(3):CD003878.
- Chiapasco M, Abati S, Romeo E, Vogel G. Implant-retained mandibular overdentures with Brånemark System MKII implants: a prospective comparative study between delayed and immediate loading. *Int J Oral Maxillofac Implants*. 2001 Jul-Aug;16(4):537-46. .
- Romeo E, Chiapasco M, Lazza A, Casentini P, Ghisolfi M, Iorio M, Vogel G. Implant-retained mandibular overdentures with ITI implants. *Clin Oral Implants Res*. 2002 Oct;13(5):495-501.
- Cannizzaro G, Leone M, Esposito M. Immediate versus early loading of two implants placed with a flapless technique supporting mandibular bar-retained overdentures: a single-blinded, randomised controlled clinical trial. *Eur J Oral Implantol*. 2008 Spring;1(1):33-43.
- Bellini CM, Romeo D, Galbusera F, Agliardi E, Pietrabissa R, Zampelis A, Francetti L. A finite element analysis of tilted versus nontilted implant configurations in the edentulous maxilla. *Int J Prosthodont*. 2009 Mar-Apr;22(2):155-7.
- Bellini CM, Romeo D, Galbusera F, Taschieri S, Raimondi MT, Zampelis A, Francetti L. Comparison of tilted versus nontilted implant-supported prosthetic designs for the restoration of the edentulous mandible: a biomechanical study. *Int J Oral Maxillofac Implants*. 2009 May-Jun;24(3):511-7.
- Shackleton JL, Carr L, Slabbert JC, Becker PJ. Survival of fixed implant-supported prostheses related to cantilever lengths. *J Prosthet Dent*. 1994 Jan;71(1):23-6.
- Francetti L, Romeo D, Corbella S, Taschieri S, Del Fabbro M. Bone level changes around axial and tilted implants in full-arch fixed immediate restorations. Interim results of a prospective study. *Clin Implant Dent Relat Res*. 2012 Oct;14(5):646-54.
- Del Fabbro M, Ceresoli V. The Fate of Marginal Bone around Axial vs. Tilted Implants: A Systematic Review. *Eur J Oral Implantol* 2014, 7 Suppl 2, S171-189.
- Chrcanovic BR, Albrektsson T, Wennerberg A. Tilted versus axially placed dental implants: a meta-analysis. *J Dent*. 2015 Feb;43(2):149-70.
- Del Fabbro M, Bellini CM, Romeo D, Francetti L. Tilted implants for the rehabilitation of edentulous jaws: a systematic review. *Clin Implant Dent Relat Res*. 2012 Aug;14(4):612-21..
- Mehta SP, Sutariya PV, Pathan MR, Upadhyay HH, Patel SR, Kantharia NDG. Clinical success between tilted and axial implants in edentulous maxilla: A systematic review and meta-analysis. *J Indian Prosthodont Soc*. 2021 Jul-Sep;21(3):217-228..
- Batista RG, Faé DS, Bento VAA, Rosa CDDR, Souza Batista VE, Pellizzer EP, Lemos CAA. Impact of tilted implants for implant-supported fixed partial dentures: A systematic review with meta-analysis. *J Prosthet Dent*. 2022 Dec 23:S0022-3913(22)00739-9.
- Mohamed LA, Khamis MM, El-Sharkawy AM, Fahmy RA. Evaluation of immediately loaded mandibular four vertical versus tilted posterior implants supporting fixed detachable restorations without versus with posterior cantilevers. *Oral Maxillofac Surg*. 2022 Sep;26(3):373-381.
- Ogawa T, Dhaliwal S, Naert I, Mine A, Kronstrom M, Sasaki K, Duyck J. Impact of implant number, distribution and prosthesis material on loading on implants supporting fixed prostheses. *J Oral Rehabil*. 2010 Jul;37(7):525-31.
- Esposito M, Cannizzaro G, Bozzoli P, Checchi L, Ferri V, Landriani S, Leone M, Todisco M, Torchio C, Testori T, Galli F, Felice P. Effectiveness of prophylactic antibiotics at placement of dental implants: a pragmatic multicentre placebo-controlled randomised clinical trial. *Eur J Oral Implantol*. 2010 Summer;3(2):135-43.
- Esposito M, Barausse C, Pistilli R, Jacotti M, Grandi G, Tuco L, Felice P. Immediate loading of post-extractive versus delayed placed single implants in the anterior maxilla: outcome of a pragmatic multicenter randomised controlled trial 1-year after loading. *Eur J Oral Implantol*. 2015 Winter;8(4):347-58.
- Felice P, Pistilli R, Barausse C, Trullenque-Eriksson A, Esposito M. Immediate non-occlusal loading of immediate post-extractive versus delayed placement of single implants in preserved sockets of the anterior maxilla: 1-year post-loading outcome of a randomised controlled trial. *Eur J Oral Implantol*. 2015 Winter;8(4):361-72.
- Berti C, Barausse C, Breschi L, Felice P. Immediate, Early (6 Weeks) and Delayed (4 Months) Post-Extractive Single Implants- a 3-Year RCT. *Clinical Oral Implants Research*. 2019, 30, 36-36
- Smeets R, Henningsen A, Jung O, Heiland M, Hammächer C, Stein JM. Definition, etiology, prevention and treatment of peri-implantitis--a review. *Head Face Med*. 2014 Sep 3;10:34.
- Boccia G, Di Spirito F, D'Ambrosio F, Di Palo MP, Giordano F, Amato M. Local and Systemic Antibiotics in Peri-Implantitis Management: An Umbrella Review. *Antibiotics (Basel)*. 2023 Jan 8;12(1):114.
- Esposito M, Grusovin MG, Worthington HV. Interventions for replacing missing teeth: treatment of peri-implantitis. *Cochrane Database Syst Rev*. 2012 Jan 18;1(1):CD004970.