

# Digital workflow from immediate to definitive CAD/CAM dentures: a case report

➤ **A. CASUCCI<sup>1\*</sup>, L.F. D'ARIENZO<sup>1</sup>, G. VERNIANI<sup>1</sup>, A. BORRACCHINI<sup>1</sup>, M. FERRARI<sup>1</sup>**

<sup>1</sup>Department of Prosthodontics and Dental Biomaterials, School of Dental Medicine, University of Siena, Italy

\* corresponding author

## TO CITE THIS ARTICLE

Casucci A, D'Arienzo LF, Verniani G, Borracchini A, Ferrari M. Digital workflow from immediate to definitive CAD/CAM dentures: a case report. *J Osseointegr* 2023;15(3):174-180.

DOI 10.23805 /JO.2023.577

## ABSTRACT

**Aim** The present article describes a simplified protocol based on a digital workflow used for a patient rehabilitation from immediate pre-extraction (ID) to definitive complete dentures (DD).

**Materials and Methods** A 67 year old patient previously rehabilitated with removable partial dentures (RPD) referred to Siena University Prosthodontic Department complaining functional and aesthetic discomforts. The anamnestic data and photos were collected at the first visit. The clinical observation and x-ray evidenced an hopeless dentition in both arches due to stage IV periodontal disease. Digital intraoral and bite scans were recorded with and without the existing Removable partial denture (RPD) for case study. The treatment plan included the extraction of all residual teeth and the delivery of ID maintaining the previous inter-maxillar relationship and all the aesthetics parameters. The ID were obtained by a single step milling procedure (Ivotion, Ivoclar Vivadent AG, Liechtenstein) and after healing at 9 months it was decided to scan the relined ID in order to reproduce the cameo surface and tooth arrangement required for a new DD fabrication.

**Results** The patient was collaborative during all treatment, reported a positive adaption from the ID delivery, a good aesthetic integration and optimal functional comfort even with DD.

**Conclusions** The digital workflow for complete dentures fabrication requires limited time and effort compared to conventional protocols. Thanks to the digital workflow the patient obtained a good adaptation to the prostheses and an enhanced aesthetics and functional results. The authors have no conflicts of interest to declare. All co-authors have seen and agree with the contents of the manuscript and there is no financial interest to report. We certify that the submission is original work and is not under review at any other publication.

## INTRODUCTION

Complete dentures (CD) still remains one of the most common and predictable treatment, in particular for edentulous patients who have systemic, anatomic, and/or financial limitations (1-3).

In case of terminal dentition, when the patient becomes edentulous, he may experience detrimental effects on functional activities (4), aesthetics (5) and the self-esteem (6), thus a decreasing their quality of life is usually expected (7,8). The construction of immediate dentures (ID) before the extractions can reduce this impairment condition (4) providing an efficient temporary prosthetic solution.

Different procedures have been described to obtain an ID (5,6,7). The conventional methods can be reliable but require multiple clinical appointments, lengthy and complex laboratory schedules (8). These aspects can lead to processing errors, inaccuracies, and increased time and cost.

In order to obtain CD in a conventional workflow, five visits are usually required in the dental practice, including preliminary impressions, final impressions, inter-maxillar registration (determining the centric relationship and the vertical dimension), teeth arrangement try-in (in order to verify aesthetic, phonetic and occlusal function) and delivery (9). To date the most of the clinicians still to use conventional procedures for impressions and occlusal recoding that can be digitized in laboratory (10,11), however it can determine a reduced precision of prostheses due to the several steps required.

Recently, computer aided design and computer aided manufacturing (CAM-CAM) technology has been used to fully fabricate ID (12-14) and digital complete dentures (DD) (15). It was been reported that DD can provide improved denture retention and fit (16,17), a time reduction of both clinical and labora-

**KEYWORDS** digital workflow, CAD/CAM, case report, digital denture

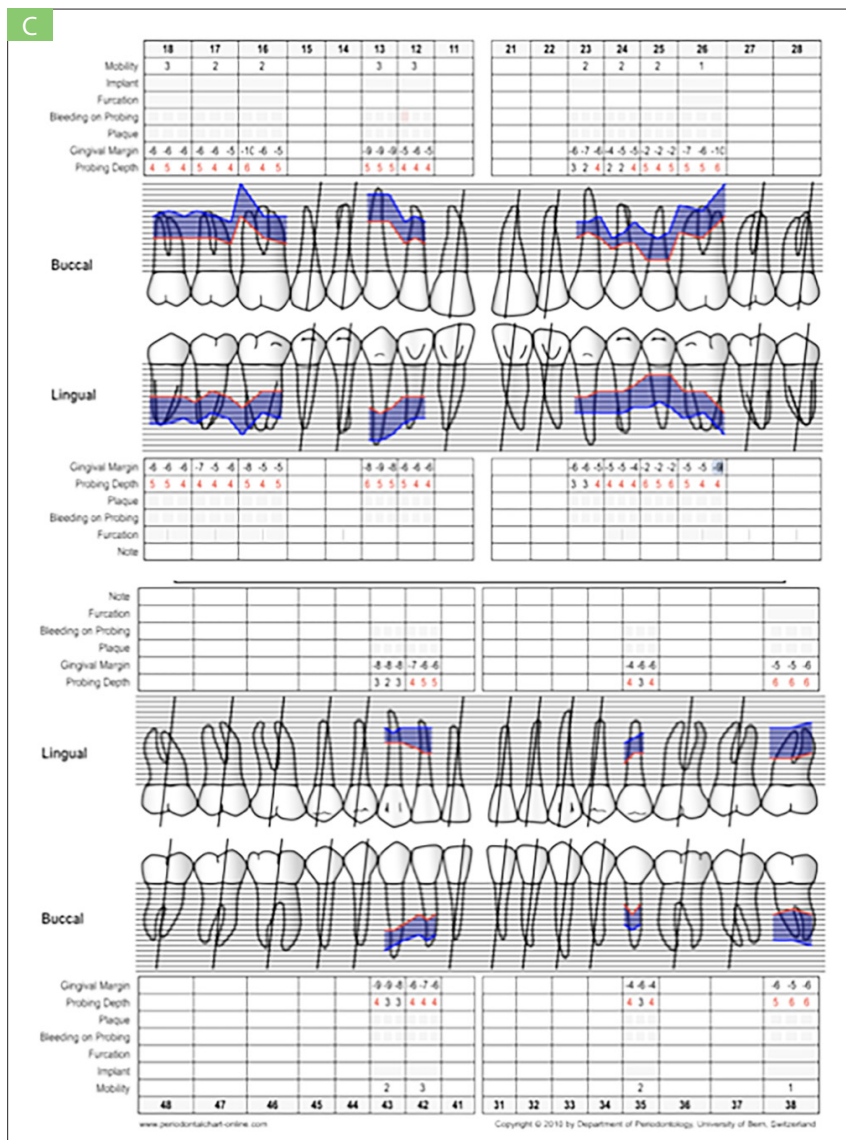
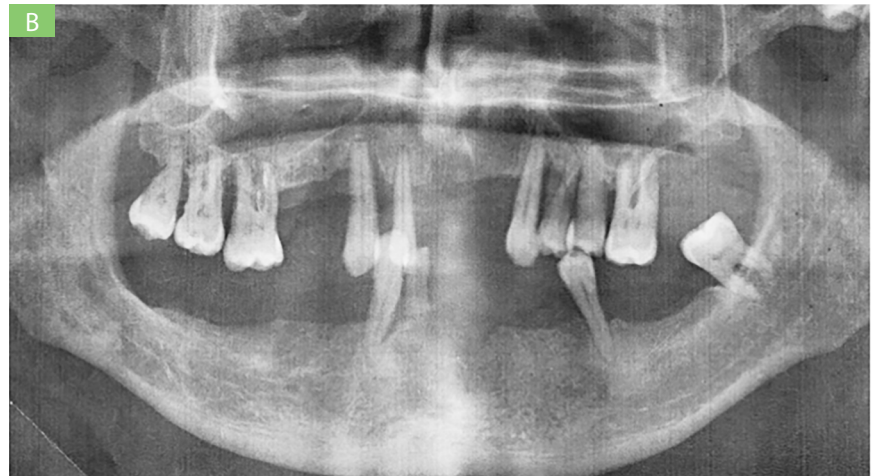


FIG. 1  
Preoperative condition.  
A: Full-face view  
B: Orthopantomography  
C: Periodontal Charting

tory procedures (18), higher patients' satisfaction (19) and reduced costs (20) comparing to the analogic protocols. Recently it was reported that the IOS (Intraoral scanner) may be accurate for complete denture (21-24), and the proof of

concept for realizing a functional maxillary complete denture on intraoral scans have been reported (25-28). The use of this technology allows to minimize the inconveniences associated with the use of traditional impression

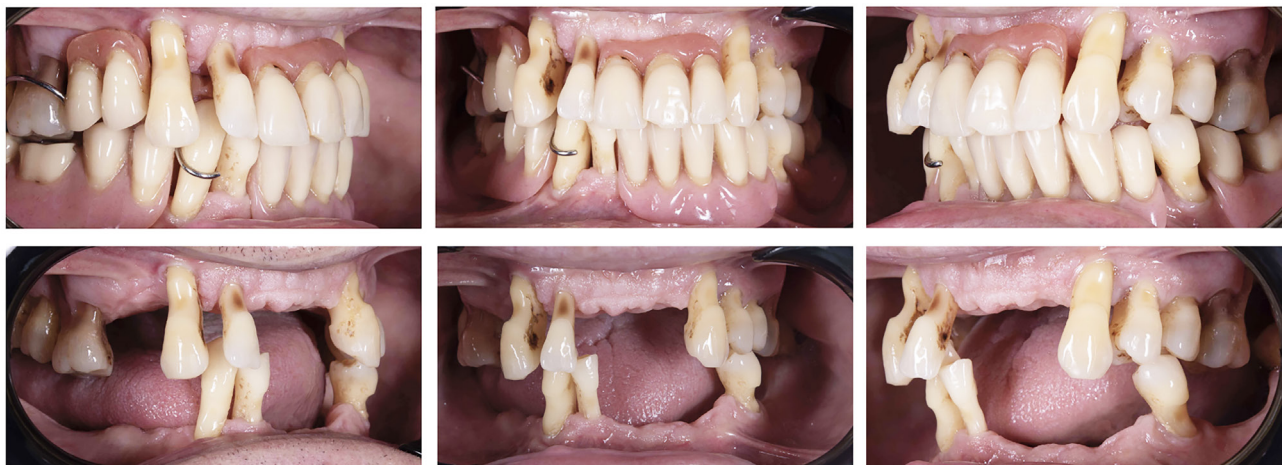

FIG. 2 Intraoral photos

materials (29). Especially in case of ID the mobility of the remaining teeth would not allow easy removal of the impression tray without exposing the patient to the risk of avulsions.

Furthermore the design softwares allow to simulate the aesthetic proposal thanks to the possibility to superimpose additional IOSs (temporaries or old dentures) to patient face scans or photos (30,31). The predictability of this digital options are still updating and are not fully documented in the scientific literature, for this reason it was chosen to report this clinical case in order to evaluate the correspondence of the esthetic results obtained from digital design software to patient mouth thought immediate denture treatment.

After the extraction, when sites have healed, the transition from the ID to DD can be done by rebasing the ID with a laboratory technique or fabricating new dentures (32). Although the first option is economical, it deprives patients of their prostheses and does not permit repositioning of individual teeth (33).

The second option can be performed by using a digital workflow, that offers more a rapid and straightforward procedure, compared to the conventional workflow, for obtaining definitive CDs (34-36).

In fact a direct digital scanning of ID using an IOS can facilitate the transition toward definitive CDs (37) thanks to the possibility to because it can be obtained from the data from the ID tested by the patient during the healing time.

This technique article presents a digital workflow to rehabilitate a patient with an ID and a DD.

### Case presentation

In 2020, a 67-year old man referred to Siena University Prosthodontic Department complaining about chewing efficiency, due to mobility of residual teeth and poor fit of the existing RPD, and aesthetics.

The patient requested a simple prosthetic rehabilitation for both maintenance and costs, and to obtain a good comfort with a removable solution.

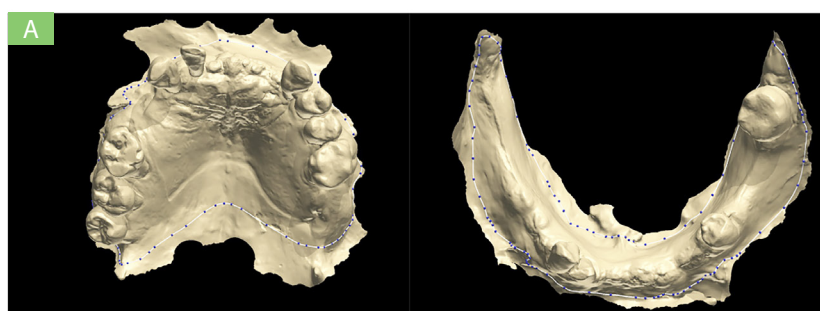
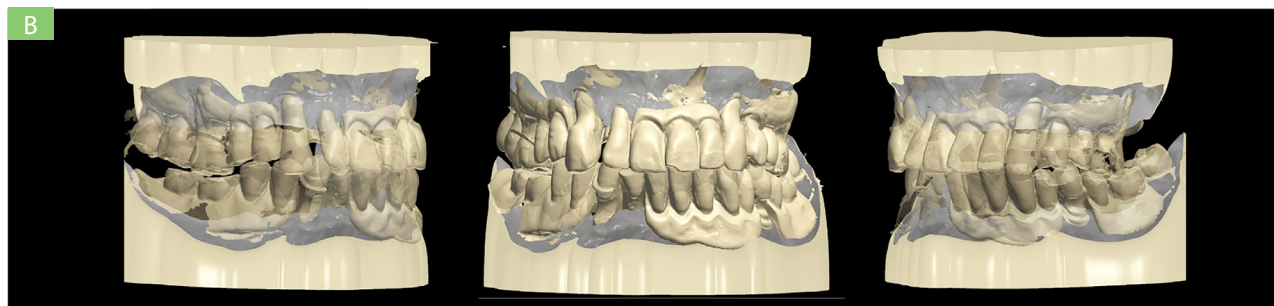
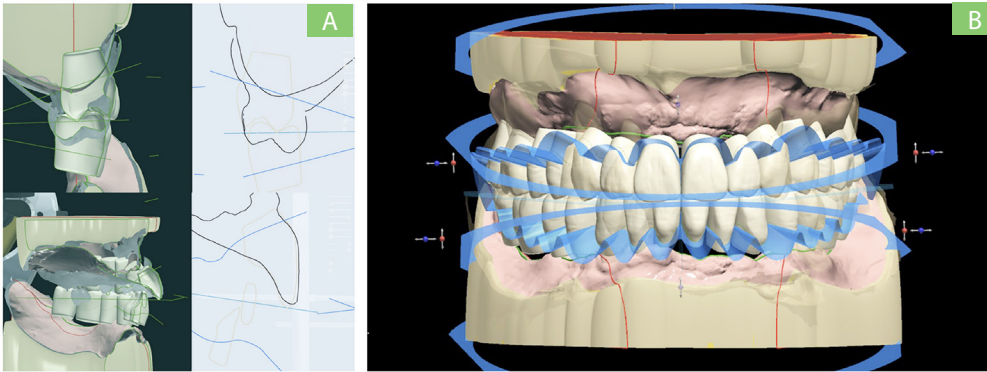


FIG. 3

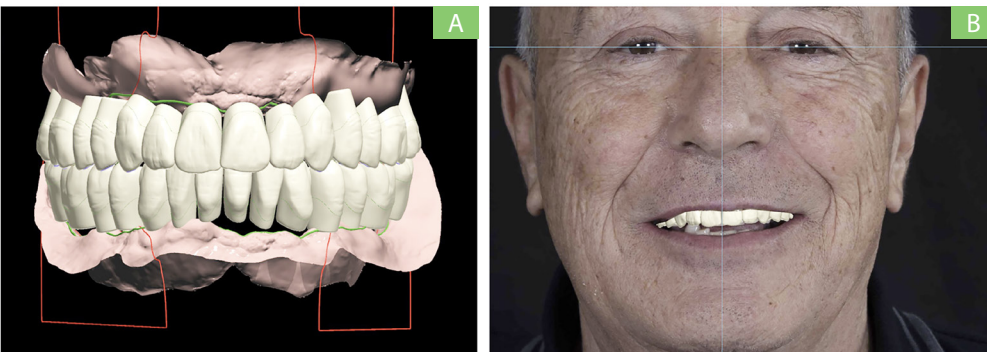
A: IOS

B: Digital master models superimposition with study models.





**FIG. 4**  
 A: cross section of the text arrangement and the previous prostheses scans  
 B: Definitive computer-aided design and shell geometry (blue rings) positioned for definitive production.



**FIG. 5**  
 A: teeth arrangement  
 B: superimposition to patient face for Smile design simulation.

At first visit all the evaluations (clinical, periodontal status and ortopanoramic XR) confirmed a diagnosis of stage 4 and grade c periodontitis (Fig. 1). Digital intraoral photographs were taken from a retracted frontal view and lateral view and extra oral photos (Fig 2).

**Treatment Plan**

The uncertain periodontal prognosis and his limited finances led to a treatment plan that included extraction of the remaining maxillary and mandibular teeth and delivery of digital ID followed by digital CD after the extraction sites had healed.

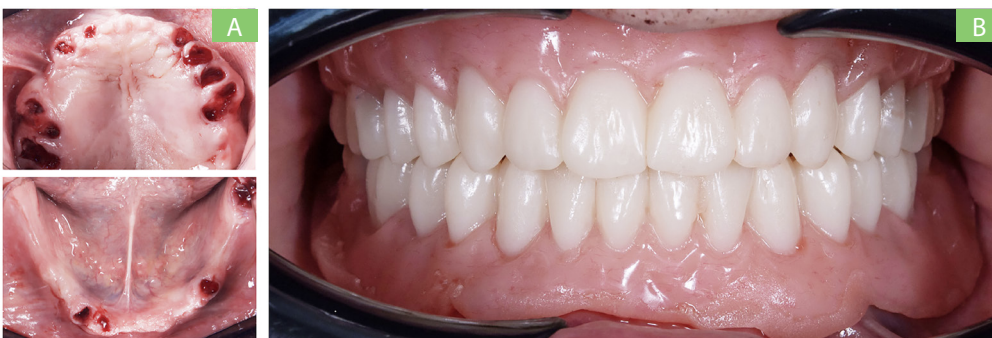**Operative sequence**

The IOS of both arches were recorded with intraoral scanner (3Shape, Trios, Denmark), the first one registered the residual teeth and the supporting area, the second was recorded with RPD in situ. The inter-maxillar position was registered thanks to the first one; whereas the other impressions were used for the aesthetic of the frontal teeth. (Fig 3)

From the outcome of the smile design and alignment of the intraoral scans, the digital immediate complete dentures were designed (Dental System 2020; 3Shape A/S, Denmark) after the virtual extraction of the residual dentition from the master models. At this point the denture teeth were chosen from the software library of denture teeth, and the design program advised a virtual tooth setup. The tooth setup could be modified according to the demands of the clinician and patient or finalized by adding the gingival portion of the dentures if no changes are requested. It was possible to evaluate in cross section views the position of the new CD teeth compared to the preparative condition.(Fig. 4)

In addition, to analyze the aesthetic parameters the teeth setup was customized according to the informations obtained by the superimposition of the IOS obtained with RPD to the patient face photo. (Fig 5)

Finally, the prostheses were designed, the output CAM file was processed for a single step milling procedure using disks with shell geometry technology (Ivotion Ivoclar Vivadent AG). Base shade preference and tooth shade A3 were select-



**FIG. 6**  
 A: intraoral photos arches after extraction sockets  
 B: Prostheses at delivery frontal view.

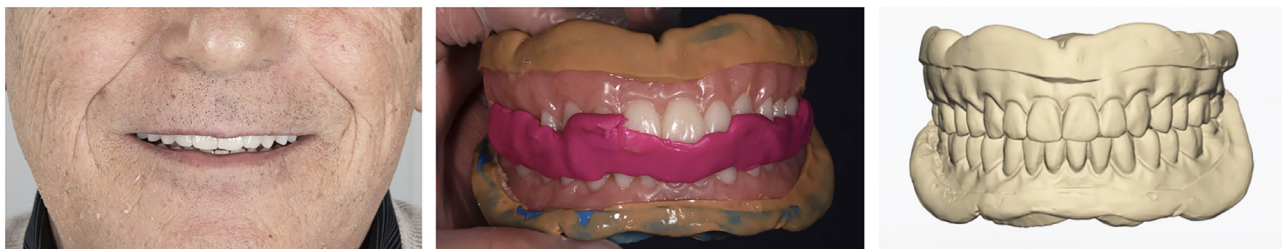

FIG. 7 Patient frontal view after 9 months, ID relined for definitive data acquisition, STL file obtained from IOS.

ed and positioned inside a milling unit (PrograMill 7; Ivoclar Vivadent AG, Liechtenstein). Finally the digital immediate complete dentures were textured and polished.

The remaining maxillary and mandibular teeth were extracted, and the digital immediate complete dentures were delivered. (Fig 6)

The patient was then followed through the healing phase. The prosthesis was maintained with soft material until the complete healing, during which the dentures were relined every 15 days during the first 2 months and then monthly to adapt to new tissue conformation. After the extraction sites healing, thanks to good patient adaption, the transition from the ID to DD was planned.

After 9 months from the extraction tissues were considered stable, the DD definitive complete dentures were produced with the reference denture technique 34 using scans of the digital immediate complete dentures as the references for the design. (Fig 7)

The the ID bases were relined with a high-precision material in a closed-mouth technique, then the extraoral scan of the cameo and intaglio surfaces of the maxillary and mandibular prosthesis using an IOS (TRIOS3; 3Shape A/S, Denmark) according to the manufacturer's indications.

The scanning workflow started from the most distal molar, progressively all occlusal surfaces were recorded since the contralateral molar. The digital scan continued with palatal and buccal surfaces of the teeth and then with the the intaglio surface to gather borders. Finally the scan was completed by capturing the missing surfaces and controlling all the impression, in particular in areas such as the denture posterior seal, lingual flange and retromolar area.

The digital definitive complete dentures were designed from an alignment of the copy denture scans and smile design for the appropriate tooth positioning. Some modifications respect the ID in accordance to clinical evaluation were per-

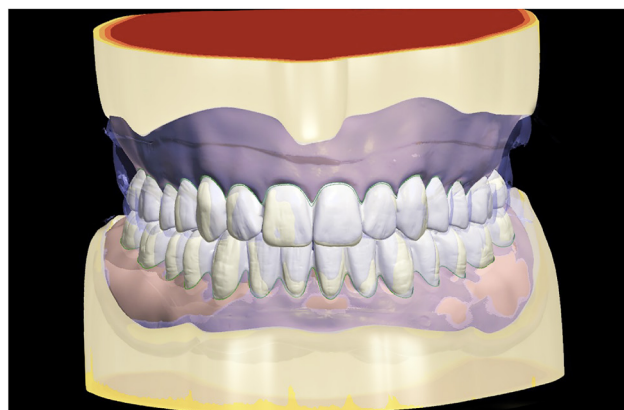


FIG. 8 Digital design for DD aligned with ID scan

fomed (Fig.8).

After the DD designs had been finalized, the prostheses were milled (PrograMill7; Ivoclar Vivadent AG, Liechtenstein), textured, polished, and delivered.

The definitive dentures were controlled at delivery for base adaption (Fig. 9).

The final esthetic transition of the patient from ID to DD was gradual according to patient needs where the position of the 21 was corrected form pre treatment to DD (Fig. 10).

## DISCUSSION

The purpose of this article was to describe a fully digital workflow from ID to the DD transferring all data using an IOS device.

The use of digital workflow for ID rehabilitations has a whole ranges of advantages, such as: no risk of extraction during impression of mobile teeth, time saving procedure ( no need for cast pouring, articulator mounting, and removing the

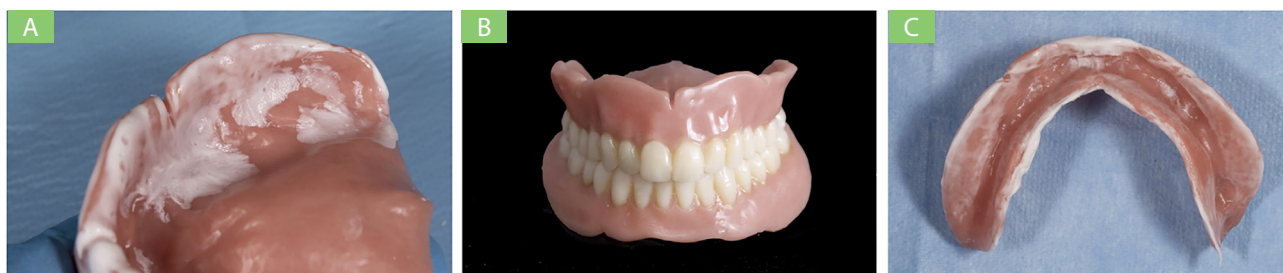

FIG. 9 DD at delivery. A/C: adaptation test, B: DD polished

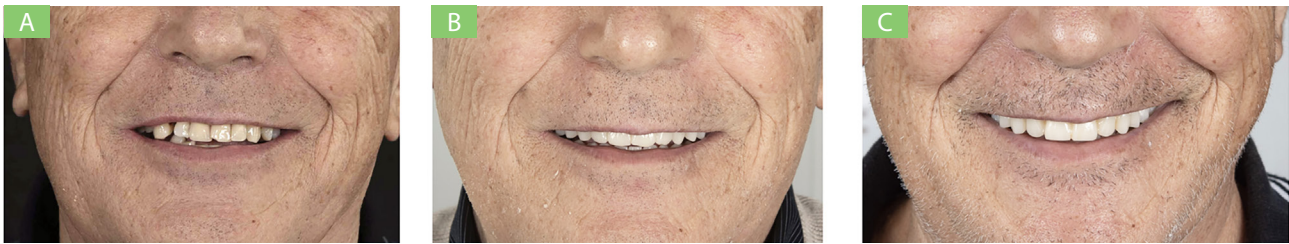

FIG. 10 Patient frontal view. A: pre treatment, B: after ID, C: after DD

teeth from the cast) and virtual occlusal registration is stored and can be reused for future replacement dentures. As reported by Silva et al. there are some disadvantages of the workflow when include positioning the shell geometry during the CAD process (43). The architecture of the gingival papilla cannot be modified; therefore, the height of the papilla peaks is not adjustable. Moreover, as the shell geometry has static papilla architecture, the positioning of the disk for the tooth and base design can lead to an undesirably thin milled base, with tooth color being visible through the base, particularly at the tuberosity and retromolar pad regions. However in the case presented the shell geometry allowed to obtain a good esthetic result for the ID thanks to the high amount of space in between the arches.

For patients for whom the monolithic disk could not be used based on these limitations, the alternative approach is to mill a pink base (Ivotion Base; Ivoclar Vivadent AG, Liechtenstein) and the teeth (Ivotion Dent; Ivoclar Vivadent AG, Liechtenstein) separately to then bond them together.

After healing there is also the possibility to use the immediate denture as a prototype for the border molding and the definitive impression, and to transfer all aesthetic and occlusal parameters to the laboratory.

The fabrication of new DD in this manner can be simplified, as shown in the recent papers (40–43), only two appointments are required to complete the treatment, as long as major corrections are needed.

the potential disadvantages due to the lack of border molding of the IOS performed for the ID can be overcome thanks to the chairside adjustments and a soft relining procedures that are always necessary to compensate the healing tissues modifications.

Concerning the definitive DD, even in this case of major modifications are required all the data obtained from ID can be used to prepare a denture prototype. It can be recommended it to test them with the patient before fabricating the definitive dentures.

In the case described in the present paper major corrections from ID to DD weren't required thus it was possible to take the final impression and to digitize it together with the occlusal and functional parameters and to finish the DD without any intermediate step

Anyway DD workflow is a flexible options, and it can improve communication between the dentist and the dental laboratory technician.

Although patient selection is important, fabricating milled complete dentures from prepolymerized PMMA disks result

in a digital removable complete denture that is highly dense, stable, and precise. The monolithic disk is homogenous with minimal porosity, which may improve resistance to bacterial and fungal infiltration into the resin. Patient satisfaction should be high, as the process requires fewer appointments and provides more accurately fitting prostheses.

In this way it will be very easy to give to the patient a definite treatment in short time and with high quality.

## CONCLUSION

This article describes a fully digital workflow that facilitates the fabrication of IDs and allows the delivery of the DD with just 2 appointment. The procedure here described improves the stability and retention of the prosthesis and allows dentists to acquire data easily for fabricating dentures. Digital workflow in CD is an innovative and predictable procedure.

## REFERENCES

1. Kattadiyil MT, AlHelal A, Goodacre BJ. Clinical complications and quality assessments with computer-engineered complete dentures: a systematic review. *J Prosthet Dent* 2017;117(6):721–8.
2. Cooper LF. The current and future treatment of edentulism. *Journal of Prosthodontics* 2009;18:116–22.
3. Owen PC. Appropriatech: prosthodontics for the many, not just for the few. *International Journal of Prosthodontics*
4. Gilboa I, Cardash HS. An alternative approach to the immediate overdenture. *J Prosthodont.* 2009 Jan;18(1):71-5.
5. Raczka TC, Esposito SJ. The “jiffy” denture: a simple solution to a sometimes difficult problem. *Compendium of Continuing Education in Dentistry* (Jamesburg, N.J. : 1995). 1995 Sep;16(9):914, 916, 918.
6. Cardash HS, Kaufman C. An interim denture technique. *Quintessence Dent Technol.* 1983 Feb;7(2):89-91.
7. Swoope CC, Depew TE, Wisman LJ, Wands DH. Interim dentures. *J Prosthet Dent.* 1974 Dec;32(6):604-12.
8. Neumeier TT, Neumeier H. Digital immediate dentures treatment: A clinical report of two patients. *J Prosthet Dent.* 2016 Sep;116(3):314-9.
9. (Fang JH, An X, Jeong SM, Choi BH. Digital immediate denture: A clinical report. *J Prosthet Dent.* 2018 May;119(5):698-701.
10. Wimmer T, Gallus K, Eichberger M, Stawarczyk B. Complete denture fabrication supported by CAD/CAM. *J Prosthet Dent.* 2016 May;115(5):541-6.
11. Schwindling FS, Stober T. A comparison of two digital techniques for the fabrication of complete removable dental prostheses: A pilot clinical study. *J Prosthet Dent.* 2016 Nov;116(5):756-763.
12. Fang JH, An X, Jeong SM, Choi BH. Digital immediate denture: a clinical report. *J Prosthet Dent* 2018;119:698-701.

13. Oh KC, Kim JH, Moon HS. Two-visit placement of immediate dentures with the aid of digital technologies. *J Am Dent Assoc* 2019;150:618-23.
14. Millet C, Virard F, Lienhart G, Ducret M. Digital prosthodontic management of young patients with Papillon-Lefèvre syndrome: a clinical report. *J Prosthet Dent* 2019.
15. Goodacre CJ, Garbacea A, Naylor WP, Daher T, Marchack CB, Lowry J. CAD/CAM fabricated complete dentures: concepts and clinical methods of obtaining required morphological data. *J Prosthet Dent*. 2012 Jan;107(1):34-46.
16. AlHelal A, AlRumaih HS, Kattadiyil MT, Baba NZ, Goodacre CJ. Comparison of retention between maxillary milled and conventional denture bases: A clinical study. *J Prosthet Dent*. 2017 Feb;117(2):233-238.
17. Steinmassl O, Dumfahrt H, Grunert I, Steinmassl PA. CAD/CAM produces dentures with improved fit. *Clin Oral Investig*. 2018 Nov;22(8):2829-2835.
18. Kattadiyil MT, AlHelal A. An update on computer-engineered complete dentures: A systematic review on clinical outcomes. *J Prosthet Dent*. 2017 Apr;117(4):478-485.
19. Kattadiyil MT, Jekki R, Goodacre CJ, Baba NZ. Comparison of treatment outcomes in digital and conventional complete removable dental prosthesis fabrications in a predoctoral setting. *J Prosthet Dent*. 2015 Dec;114(6):818-25.
20. Srinivasan M, Schimmel M, Naharro M, O' Neill C, McKenna G, Müller F. CAD/CAM milled removable complete dentures: time and cost estimation study. *J Dent*. 2019 Jan;80:75-79.
21. D'Arienzo LF, D'Arienzo A., Borracchini A. Comparison of the suitability of intra-oral scanning with conventional impression of edentulous maxilla in vivo. A preliminary study. *Journal of Osseointegration*, 2018;10(4)115-120.
22. Jung S, Park C, Yang HS, Lim HP, Yun KD, Ying Z, Park SW. Comparison of different impression techniques for edentulous jaws using three-dimensional analysis. *J Adv Prosthodont*. 2019 Jun;11(3):179-186.
23. Chebib N, Kalberer N, Srinivasan M, Maniewicz S, Perneger T, Müller F. Edentulous jaw impression techniques: An in vivo comparison of trueness. *J Prosthet Dent*. 2019 Apr;121(4) 623-630.
24. Lo Russo L, Caradonna G, Troiano G, Salamini A, Guida L, Ciavarella D. Three-dimensional differences between intraoral scans and conventional impressions of edentulous jaws: A clinical study. *J Prosthet Dent*. 2019 May 29. *J Prosthet Dent*. 2020 Feb;123(2):264-268.
25. D'Arienzo L. F., Casucci, A., Manneh, P., D'Arienzo, A., Borracchini, A., Ferrari, M. (2021). Digital workflow in complete dentures: a narrative review. *Journal of Osseointegration*, 12(4), 743–750.
26. Lo Russo L, Salamini A, Troiano G, Guida L. Digital dentures: A protocol based on intraoral scans. *J Prosthet Dent*. 2021 Apr;125(4):597-602.
27. Lo Russo L, Salamini A. Removable complete digital dentures: A workflow that integrates open technologies. *J Prosthet Dent*. 2018 May;119(5):727-732.
28. Fang JH, An X, Jeong SM, Choi BH. Digital immediate denture: A clinical report. *J Prosthet Dent*. 2018 May;119(5):698-701.
29. Patzelt, S.B., Vonau, S., Stampf, S., and Att, W. Assessing the feasibility and accuracy of digitizing edentulous jaws. *J Am Dent Assoc*. 2013; 144: 914–920
30. da Silva Marques DN, Aparício Aguiar Alves RV, Marques Pinto RJ, Bártolo Caramês JR, de Oliveira Francisco HC, Mendez Caramês JM. Facial scanner accuracy with different superimposition methods - In vivo study. *Int J Prosthodont*. 2021 September/October;34(5):578–584.
31. Mao B, Li J, Tian Y, Zhou Y. The accuracy of a three-dimensional face model reconstructing method based on conventional clinical two-dimensional photos. *BMC Oral Health*. 2022 Sep 19;22(1):413.
32. Neumeier TT, Neumeier H. Digital immediate dentures treatment: a clinical report of two patients. *J Prosthet Dent* 2016;116:314-9.
33. Boucher CO. The relining of complete dentures. *J Prosthet Dent* 2004;91:303-5.
34. Fang JH, An X, Jeong SM, Choi BH. Development of complete dentures based on digital intraoral impressions-case report. *J Prosthodont Res* 2018;62: 116-20.
35. Unkovskiy A, Wahl E, Zander AT, Huettig F, Spitzzyk S. Intraoral scanning to fabricate complete dentures with functional borders: a proof-of-concept case report. *BMC Oral Health* 2019;19:46.
36. Goodacre BJ, Goodacre CJ, Baba NZ. Using intraoral scanning to capture complete denture impressions, tooth positions, and centric relation records *Int J Prosthodont* 2018;31:377-81.
37. Millet C, Virard F, Dougnac-Galant T, Ducret M. CAD-CAM immediate to definitive complete denture transition: A digital dental technique. *J Prosthet Dent*. 2020 Dec;124(6):642-646.
38. Kurahashi K, Matsuda T, Goto T, Ishida Y, Ito T, Ichikawa T. Duplication of complete dentures using general-purpose handheld optical scanner and 3- dimensional printer: introduction and clinical considerations. *J Prosthodont Res* 2017;61:81-6.
39. Clark WA, Duqum I, Kowalski BJ. The digitally replicated denture technique: a case report. *J Esthet Restor Dent* 2019;31:20-5
40. Maragliano-Muniz P, Kukucka ED. Incorporating digital dentures into clinical practice: flexible workflows and improved clinical outcomes. *J Prosthodont* 2021;30:125-32.
41. R, Bencharit S. Creating a digital duplicate denture file using a desktop scanner and an open-source software program: a dental technique. *J Prosthet Dent* 2021;125:402-6.
42. Kurahashi K, Matsuda T, Goto T, Ishida Y, Ito T, Ichikawa T. Duplication of complete dentures using general-purpose handheld optical scanner and 3- dimensional printer: introduction and clinical considerations. *J Prosthodont Res* 2017;61:81-6.
43. Silva NRFA, Kukucka ED. Innovative subtractive production of a digital removable complete denture from start to finish: a JPD Digital video presentation. *J Prosthet Dent*. 2022 Jan;127(1):1-5.