

> FEDERICA DEMAROSI MD DDS PHD<sup>1</sup>, ANTONIO CARRASSI MD<sup>1</sup>, GIULIO CESARE LEGHISSA MD<sup>2</sup>

<sup>1</sup> Unit of Oral Pathology and Medicine, Department of Medicine, Surgery and Dentistry, University of Milan (Italy)

<sup>2</sup> General Dental Practitioner, Milan (Italy)

## Dental implant treatment in oral bisphosphonates patients using a drug holiday protocol: a prospective study

### ABSTRACT

**Aim** Bisphosphonates are the most important class of antiresorptive agents commonly used in the management of osteoporosis, Paget's disease, and tumor-associated osteolysis. Oral bisphosphonate-induced osteonecrosis is a rare but real entity caused by the antiosteoclastic effects of bisphosphonates which inhibit bone turnover. The aim of this work is to determine the extent to which bisphosphonate-associated osteonecrosis occurs after dental implant surgery. We also wanted to determine whether there was any indication that bisphosphonates affected the overall success of the implants.

**Materials and methods** We described 21 patients undergoing dental implants surgery who were taking or had taken oral bisphosphonates. All patients were informed about the risk of osteonecrosis and a written informed consent was obtained from each individual.

**Results** A total of 38 implants were placed in 21 patients who reported having received oral bisphosphonates. None had received intravenous bisphosphonates. There is no evidence of osteonecrosis in any of the patients evaluated. Of the 38 implants, all but 2 fully integrated and met implant success criteria.

**Conclusion** Implant surgery on patients receiving oral bisphosphonates did not result in osteonecrosis. Moreover, oral bisphosphonates did not appear to significantly affect implant success. Nevertheless, sufficient evidence exists to suggest that all patients undergoing implant placement should be questioned about bisphosphonate therapy including the drug taken, the dosage, and length of treatment prior to surgery.

**KEYWORDS** Bisphosphonates; Dental implants; Oral surgery; Osteonecrosis.

### INTRODUCTION

Since 2003, several authors have reported and alerted for the potentially serious side effect of bisphosphonate-related osteonecrosis of the jaw (BRONJ) after chronic administration of

bisphosphonates (BPs) (1, 2). BPs are a class of drugs used for the treatment of metabolic bone diseases, including osteoporosis, Paget's disease and other conditions like tumor-associated osteolysis and hypercalcemia (3). These compounds are analogues of naturally-occurring inorganic pyrophosphate in which the oxygen atom is substituted by a carbon atom. They have specificity to bone due to their high binding affinity for calcium phosphates and are not well metabolized. Their mechanism of action remains unclear but they are known to inhibit the osteoclastic function and differentiation from precursors, to induce apoptosis of osteoclasts, and to alter angiogenesis (4). When bone resorption occurs, BPs are released from the hydroxyapatite crystal and are taken up by osteoclasts. Metabolites of non-nitrogen containing BPs (such as etidronate and clodronate) are cytotoxic to the osteoclasts and lead to their death. Nitrogen-containing BPs, however, act by way of the mevalonate pathway (for cholesterol synthesis), inhibiting protein prenylation, a process essential for normal functioning of vital intracellular proteins, ultimately leading to osteoclast apoptosis (programmed cell death). BPs also inhibit differentiation of osteoclasts and stimulates osteoblasts to produce osteoclast-inhibiting factor. Therefore, the net result is reduced number of osteoclasts and reduced bone resorption. Because bone resorption is coupled to osteoblastic bone formation for remodeling, bone turnover (ie, resorption and deposition) becomes severely suppressed. However, the bone continues to mineralize and could become brittle and less elastic. In one case report, BPs taken at high doses led to an osteopetrotic-like state. Many studies have shown that nitrogen-containing BPs also reduce the activity of cancer cells and control metastases. This process may be related to inhibition of protein prenylation leading to disruption of intracellular activity within the cancer cells. However, the alteration of the microenvironment itself, caused by reduced bone resorption alone, could also account for control of metastases. BPs also reduce adhesion, invasion, and viability of cancer cells and may activate gamma delta

T cells, which have tumoricidal activity. In vitro, zoledronic acid inhibits angiogenesis mediated through basic fibroblast growth factor and may induce apoptosis of endothelial cells. Antiangiogenic activity may also occur through lowering circulating levels of vascular endothelial growth factor and platelet-derived growth factor, both of which are proangiogenic (4).

Incidence of BRONJ is estimated to range from 0.8% to 12% for patients receiving intravenous formulations. For patients taking oral BPs, the incidence is estimated to be 0.7 per 100.000 persons per years of exposure (5). Patients usually complain of pain, accompanied by soft tissue ulceration and/ or exposed bone of the maxilla or mandible. BRONJ generally occurs after a dental extraction or after other dental events, such as trauma, or it can simply occur spontaneously.

A conclusive cause and effect relationship between BPs therapy and BRONJ has not been established. But evidence suggests that such a link may in fact exist. Unfortunately there is limited data to aid in the identification of other risk factors for the development of the disease. Some evidence suggests that they may include the potency of the drug used, the duration of therapy, being Caucasian, being older than 65, having chronic periodontitis, ongoing corticosteroid therapy, having diabetes, smoking, and alcohol intake (6, 7, 8).

It appears important to make a distinction between BRONJ induced by oral BPs versus that induced by intravenous BPs. Oral bisphosphonate-induced necrosis appears to be less frequent, less severe, more responsive to discontinuation of the drug, and curable with surgical debridement. Marx states that BRONJ from oral BPs differs significantly from intravenous bisphosphonate-associated osteonecrosis in 3 major ways: patients taking oral BPs require a longer period of drug therapy before bone is exposed, manifest less bone exposure and symptoms are less severe, and have a chance of symptoms improving or exposed bone healing after a drug holiday (9).

The management of patients who are receiving BPs therapy is based on published recommendations by expert panels, on literature and on the practical experience of dentists, maxillofacial surgeons and oncologists as there are not established definitive guidelines. The collaboration between the dentist and the oncologist plays a fundamental role on BRONJ management cases as they must share knowledge about this emerging problem and be able to deal with it, and inform the patient not only about the possibility of developing BRONJ, but also about the possible strategies for its prevention (5, 10).

The American Dental Association Expert Panel recommends that patients taking oral BPs be informed about the risks and benefits. They further recommend that nonsurgical and less invasive treatment alternatives be used when possible. The panel cautions that patients may be at increased risk when extensive

implant placement or guided bone regeneration is necessary. When the treatment plan involves the medullary bone and/or periosteum in multiple sextants, the panel recommends treating one sextant or tooth at a time. They recommend treatment with an antimicrobial mouth rinse and a 2-month disease-free follow-up before other sextants are treated (5).

The Task Force appointed by the American Association of Oral and Maxillofacial Surgeons also recommends that patients taking oral BPs be informed of the small risk of compromised bone healing. The Task Force states that elective dentoalveolar surgery does not appear to be contraindicated in patients without known risk factors who have been taking oral BPs for less than 3 years. A drug holiday of at least 3 months prior to surgery is suggested for patients who have taken oral BPs for more than 3 years and those that have taken corticosteroids concomitantly. If dental implants are to be placed, the panel suggests contacting the physician who prescribed the oral BPs prior to surgery to suggest an alternate dosing schedule, a drug holiday, or an alternative to BPs therapy (10).

The aim of this work is to determine the extent to which BRONJ occurs after dental implant surgery. We also wanted to determine whether there was any indication that the BPs therapy affected the overall implants success as defined by Albrektsson (11).

## MATERIALS AND METHODS

### Patients

Patients were considered for the study if they were taking or had taken oral BPs therapy and were undergoing implant therapy as an elective treatment to restore partial edentulism. Patients who had undertaken the BPs therapy for neoplastic pathology have been excluded, as well as those who were undergoing the intravenous BPs therapy. Other exclusion criteria were osteonecrosis of the jaws, extremely atrophic ridges needing expansion or other invasive procedures, tobacco use, history of radiotherapy in the head and neck region, steroid therapy, active periodontal disease involving residual dentition, poor oral hygiene, and non-compliant patients. All patients were informed about the risk of BRONJ and a written informed consent was obtained from each individual. For every single patient a single form has been completed containing anagraphic data, base pathology, type, frequency and duration of the BPs therapy, characteristics of the intervention, the BRONJ preventive protocol (antibiotics e antibacterics), possible notes, and follow-ups every three months.

### Surgical technique

Under local infiltration anesthesia, full-thickness flaps were elevated, following a mid-crestal incision. When

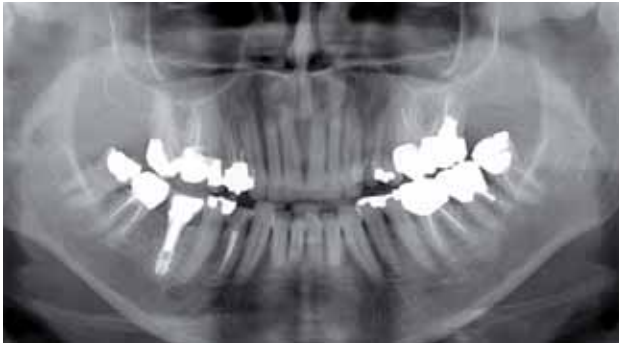

Fig. 1 Pre-operative panoramic x-ray taken in January 2007.

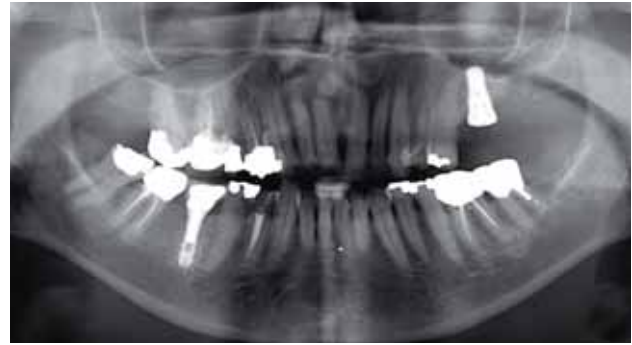

Fig. 2 Post-operative panoramic x-ray after one dental implant was placed in the upper left quadrant taken in October 2008.

relevant, mesial and distal soft tissue discharges were prepared to facilitate visual access to the bone crest. Implants were inserted following the Bone System method (Milan, Italy). After implant placement, the soft tissue was sutured and the implant was left to heal in a submerged way. Sutures were removed 7-10 days post-operatively.

**BRONJ preventive protocol**

The followed protocol used for the surgical procedures are based on the expert panels referred to in literature as there are no definitive protocols concerning the prevention and treatment of BRONJ.

Pre-operative phase:

- > Professional oral hygiene performed at least 2 weeks before the intervention;
- > Oral rinses with chlorhexidine mouthwashes 0.2% every 12 hours for 2 weeks before the intervention;
- > Antibiotic therapy with amoxicillin, 2 gr per day, 1 week before the intervention.

Intra-operative phase:

- > The intervention was performed minimizing the soft tissues and bone trauma.

Post-operative phase:

- > Oral rinses with chlorhexidine mouthwashes 0.2% every 12 hours for 2 weeks after the intervention;
- > Antibiotic therapy with amoxicillin, 2 gr per day, at least for 2 weeks after the intervention.

**Follow-up and success criteria**

Clinical monitoring was carried out one, three, six, nine and twelve months after surgery and then annually, with clinical examinations. Three to four months after implant placement, abutments were connected and prosthetic rehabilitation was initiated.

Panoramic radiographs were obtained prior to, immediately after, and 6 months following implant placement surgery.

Success criteria included effective placement and primary stability of the planned implant, implant stability at each control (absence of mobility), absence of pain or any subjective sensation at each control, absence of peri-implant infection with suppuration,

and absence of continuous radiolucency around the implant (11).

**RESULTS**

Between January 2007 and December 2008, 38 implants were placed in 21 consecutive, non-smoking adults (19 females, 2 males, aged 56-86 years; mean: 67,3) who reported that they had received oral BPs therapy. None had received intravenous BPs. Anagraphic data, clinical features of patients, the type, and duration of oral BPs therapy, and follow-up are reported in Table 1. All patients started oral BPs therapy before implant placement and stopped oral BPs 4 to 11 months before the intervention. All patients suffered from osteoporosis and had taken oral BPs (18

Pts	Age	Sex	N° impl	Type of BPs	Therapy	Follow-up
1	59	F	3	alendronate	60 months	6 months
2	60	F	1	clodronate	48 months	6 months
3	69	F	1	alendronate	60 months	18 months
4	59	M	1	alendronate	12 months	15 months
5	74	F	2	alendronate	48 months	21 months
6	72	F	1	risendronate	120 months	24 months
7	86	F	1	alendronate	120 months	24 months
8	67	F	2	alendronate	144 months	6 months
9	60	M	1	alendronate	60 months	6 months
10	61	F	1	alendronate	60 months	12 months
11	68	F	2	alendronate	12 months	15 months
12	81	F	3	alendronate	48 months	12 months
13	59	F	1	clodronate	6 months	12 months
14	69	F	3	alendronate	120 months	6 months
15	73	F	4	alendronate	48 months	9 months
16	56	F	2	alendronate	24 months	9 months
17	70	F	1	alendronate	72 months	9 months
18	72	F	1	alendronate	120 months	6 months
19	65	F	2	alendronate	6 months	12 months
20	79	F	3	alendronate	120 months	12 months
21	56	F	2	alendronate	6 months	15 months

Table 1 Characteristics of patients

alendronate, 2 clodronate, 1 risendronate) for 6 to 144 months prior to inclusion in the study. The mean duration of BPs therapy prior to the study was 62.5 months (Table 1). No infection was noted during the post-operative period and healing was uneventful in all patients. There is no evidence of BRONJ in any of the patients evaluated.

Of the 38 implants, 36 are in function and are successful according to success criteria (11). Two implants failed to integrate and were removed during the follow-up; they were not replaced and the areas healed uneventfully. All implants underwent loading after 89-147 days (average: 96). Follow-up ranged from 6 to 24 months (average: 12.1), calculated from the day of the intervention.

Thirty-six out of 38 implants fulfilled the pre-defined success criteria, based on clinical and radiographic examination, and were classified as successful implants (implant success rate = 94.7%). Moreover, all patients had acceptable function of the implant-supported prostheses, with no pathologic signs or symptoms and a satisfactory esthetic result.

## DISCUSSION

BPs are widely used for the treatment of diseases such as multiple myeloma, bone metastases and malignant hypercalcemia, as well as for the prevention and treatment of osteoporosis and other skeletal diseases such as Paget's disease (7, 9, 12, 13, 14).

The present work focuses on the implant surgery and its close relationship with osteonecrosis related to oral BPs. Despite the widespread use of oral BPs, a review of the literature found only one case report of dental implant failure associated specifically with oral BPs use. This case report suggested that failure of 5 implants was caused by BPs therapy (15). In 2006, Jeffcoat reported the results of a single-blind controlled study of 50 postmenopausal female dental implant patients. After 3 years, there was a 100% success rate with no clinical evidence of infection, pain, or necrosis in the patients who received oral BPs. There was a 99.2% success rate in the group who did not receive oral BPs (16). Grant et al. found similar results. In fact, of the 115 patients taking oral BPs, none showed evidence or had symptoms of BRONJ. All have had successful implant restorations (17). A study by Bell et al. (18) involved the examination of 42 patients (101 implants) who had taken BPs prior to surgeries involving oral bone grafting or endosseous implant placement. Patients had been taking BPs from 6 months to 11 years prior to implant surgery (only six patients for 3 years or fewer), and most continue to take these medications after the intervention. The results of this retrospective analysis showed no causal relationship between BPs and implant failure. Furthermore, there was no evidence of

BRONJ or any other related complication in any of the patients. According to the literature, in our study there is no evidence of BRONJ in any of the 21 patients after dental implant surgery (follow-up: 6-24 months).

Management of patients receiving oral BPs should be separated and distinguished from the management of patients receiving intravenous BPs. The differences in the treatment and prevention of oral to intravenous BRONJ are based on the slow accumulation of oral BPs into the bone which leads to the reestablishment of osteoclasts. In explaining the long duration of action of intravenous BPs, and to a lesser extent oral BPs, it has been proposed that there is continual recycling of BP off and back onto the bone surface. This notion is supported by observations that BPs can be found in plasma and urine many months after dosing. The speed of reversal of effect after discontinuing administration of BPs reveals potential clinical differences in BPs that may be important for practical and clinical reasons. Because no head-to-head studies have been conducted, it is hard to assess the resolution of effect on bone turnover markers after treatment with a BP is discontinued. Studies differ with regard to factors such as baseline turnover status of participants, inclusion of an appropriate control group, and duration of BP treatment. Data from both animal and human studies suggest that duration of suppression of turnover is not only dependent on which BP is given, but also on the dose. In general, the higher the dose or higher the bone affinity of the drug, the longer time bone turnover is reduced (4, 21).

The slow accumulation of oral BPs into the bone which leads to the reestablishment of osteoclasts allows the interruption of the therapy for a period of time, the so-called "drug holiday", which can only be done under medical surveillance and after the dentist's requirement. During this period, the bone can heal up spontaneously or can be treated with minimal cleaning up procedures made in the dentist's office, procedures which are not allowed in the cases of intravenous BRONJ cases (20).

All the articles consulted in the literature agree that in patients treated with intravenous BPs, it is necessary to avoid any kind of invasive oral procedure (such as dental implant placement), unless such techniques are considered absolutely necessary (21). In patients treated with oral BPs it is recommended that patients be adequately informed both of the small risk of compromised bone healing and about the implications of oral BPs therapy. The dentist should inform the patients who are taking oral BPs that: there is a very small risk of developing BRONJ (estimated at 0.7 cases per 100.000 person-years exposure); there are ways to minimize but not to eliminate the low risk; a good oral hygiene, along with regular dental care, is the best way to lower the risk; 4) there is a new diagnostic technique (morning fasting serum C-terminal telopeptide, CTX,

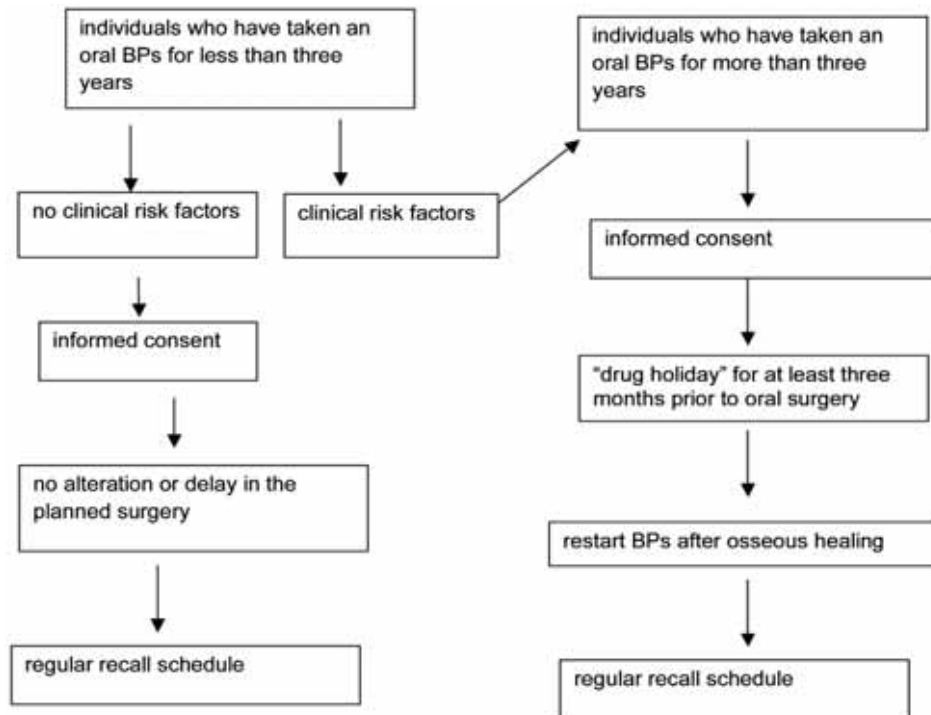


Fig. 3 Decision tree for the treatment of patients who are taking oral BPs.

bone turnover marker) to identify those at an increased risk of developing BRONJ (22). The patient should also be informed of the dental treatment needed, of alternative treatments, of how any treatment relates to the risk of BRONJ, of any other risks associated with various treatment options and of the risk of foregoing treatment, even if temporary (5).

For individuals who have taken an oral BPs for less than three years and have presented no clinical risk factors, no alteration or delay in the planned surgery is necessary. However, when the treatment plan dictates that the medullary bone and/or periosteum is going to be involved in multiple sextants, the dentist should treat one sextant or tooth first, if possible. If dental implants are placed, informed consent about the possibility of a future implant failure and possible BRONJ should be provided, in case the patient continues to take an oral BPs. Such patients should then be placed on a regular recall schedule (Fig. 3). It is also advisable to contact the operator who originally prescribed the oral BPs so that he/she can monitor those patients and can consider either an alternate dosing of the BPs, e.g. "drug holidays", or an alternative to the BPs therapy (10). Different authors consider that in patients receiving treatment with BPs who must undergo surgery, prior withdrawal of these drugs (drug holidays) may be advisable. Marx suggests that drug holidays on the order of 4 to 6 months are reasonable, safe, and could be expected to minimize the risk of osteonecrosis when performing invasive oral surgical procedures in patients taking oral bisphosphonates while also maintaining BMD values and fracture prevention related to the

osteoporosis (21). He has demonstrated the clinical bone recovery and response to the "drug holiday" proving that at least part of the functioning osteoclast population can recover and be re-established from the osteoclast precursors in the bone marrow. This is a clear distinction between the oral BPs cases and the intravenous BPs cases in which we mostly observe no improvement or response to local debridement surgery with discontinuation of the intravenous BP (22).

For patients who have taken an oral BP for less than three years and have also taken corticosteroids concomitantly, the prescribing care provider should be contacted so as to consider discontinuation of the oral BPs ("drug holiday") for at least three months prior to oral surgery, if systemic conditions allow it. The BPs should not be restarted until osseous healing has occurred. This strategy is based on the hypothesis that concomitant treatment with corticosteroids may increase the risk of developing BRONJ and that a "drug holiday" may mitigate the risk. The same strategies are indicated for those patients who have taken an oral BPs for more than three years with or without any concomitant steroid medication (5) (Fig. 3). In our study the mean duration of BPs therapy prior to the study was 62.5 months, all patients have taken oral BPs for six months or more and only 6 patients have taken oral BPs for less than three years (Table 1). We did not consider patients who have taken concomitant steroid medication (exclusion criterion). Prednisone does not induce osteonecrosis by themselves but along with BPs will cause the BRONJ to occur sooner, be more severe, and respond more slowly to a drug holiday (22).

In this limited study of 21 patients, implant placement and oral bone grafting appear to be safe and successful procedures in patients taking oral BPs for osteoporosis. Considering the number of patients taking oral BPs, further retrospective studies as well as prospective studies of this nature will be helpful in clarifying this issue.

The BRONJ preventive protocol used in our study for the implant surgical procedures is based on the expert panels referred to in literature and on our experience, as there are no definitive protocols concerning the prevention and treatment of BRONJ. The discussion of the results obtained in a follow-up average period of 12.1 months, together with their confrontation with data from literature, leads to the conclusion that the protocol applied may have been successful. Definitive guidelines are, nevertheless, difficult to establish. In fact, it is not possible to devise randomized, controlled trials to evaluate medium and long term strategies for the prevention or management of BRONJ in individuals undergoing oral BPs (5; 10).

The results of this study show that the oral therapy with BPs did not seem to influence significantly the success of the implant therapy and that the implant surgery on patients receiving oral BPs had not resulted in BRONJ. Furthermore, we suggest that the guidelines should be differentiated according to the type of administration (oral or intravenous) and we also highlight the need to monitor all patients who have started the implant therapy and those who have undergone the BPs therapy. Patients who have taken BPs for more than three years or those treated contemporaneously with corticosteroids afterwards should be targeted for new tests and for alternative therapeutical options. Furthermore, for years dentists have routinely performed surgical procedures and placed implants in patients receiving BPs therapy. Prior to widespread awareness of the risk of BRONJ and publication of treatment recommendations, these patients were treated without modification of standard treatment procedures. Additional research is required to determine if additional diagnostic testing or treatment modifications are actually necessary.

## REFERENCES

- Migliorati CA. Bisphosphonates and oral cavity avascular bone necrosis. *J Clin Oncol* 2003; 21(22):4253.
- Marx RE. Pamidronate (aredia) and zoledronate (zometa) induced avascular necrosis of the jaws: a growing epidemic. *J Oral Maxillofac Surg* 2003; 61(9):1115-7.
- Rogers MJ, Gordon S, Benford HL, Coxon FP, Luckman SP, Monkkonen J, Frith JC. Cellular and molecular mechanisms of action of bisphosphonates. *Cancer Suppl* 2000; 88(12 Suppl):2961-78.
- Russell RGG, Watts NB, Ebetino FH, Rogers MJ. Mechanism of action of bisphosphonates: similarities and differences and their potential influence on clinical efficacy. *Osteoporos Int* 2008; 19 (6):733-59.
- American Dental Association Council on Scientific Affairs: Dental management of patients receiving oral bisphosphonate therapy: Expert panel recommendations. *J Am Dent Assoc* 2006; 137(8):1144-50.
- Marx RE, Sawatari Y, Fortin M, Broumand V. Bisphosphonate-induced exposed bone (osteonecrosis/osteopetrosis) of the jaws. Risk factors, recognition, prevention, and treatment. *J Oral Maxillofac Surg* 2005; 63(11):1567-75.
- Ruggiero SL, Mehrotra B. Ten years of alendronate treatment for osteoporosis in postmenopausal women. *N Engl J Med* 2004; 82004 Jul 8;351(2):190-2.
- Schwartz HC. Osteonecrosis and bisphosphonates: correlation versus causation. *J Oral Maxillofac Surg* 2004; 62(6):763-4.
- Marx RE. *Oral and Intravenous Bisphosphonate-Induced Osteonecrosis of the Jaws*. Hanover Park, IL, Quintessence, 2007.
- Advisory Task Force on Bisphosphonate-Related Osteonecrosis of the Jaws, American Association of Oral and Maxillofacial Surgeons: American Association of Oral and Maxillofacial Surgeons position paper on bisphosphonate-related osteonecrosis of the jaws. *J Oral Maxillofac Surg* 2007; 65(3):369-76.
- Albrektsson T, Zarb G, Worthington P, Eriksson AR. The long-term efficacy of currently used dental implants: A review and proposed criteria of success. *Int J Oral Maxillofac Implants* 1986; 1(1):11-25.
- Scully C, Madrid C, Bagan J. Dental endosseous implants in patients on bisphosphonates therapy. *Implant Dent* 2006;15(4):353-60.
- Hillner BE, Ingle JN, Berenson JR, et al. American Society of Clinical Oncology guideline on the role of bisphosphonates in breast cancer. *J Clin Oncol* 2000; 18(6):1378-91.
- Berenson JR, Hillner BE, Kyle RA, et al. American Society of Clinical Oncology clinical practice guidelines: The role of bisphosphonates in multiple myeloma. *J Clin Oncol* 2002; 20(17):3719-36.
- Stark WJ, Epker BN. Failure of osteointegrated dental implants after diphosphonate therapy for osteoporosis: A case report. *Int J Oral Maxillofac Implants* 1995; 10(1):74-8.
- Jeffcoat MK. Safety of oral bisphosphonates: Controlled studies on alveolar bone. *Int J Oral Maxillofac Implants* 2006; 21(3):349-53.
- Grant B, Amenedo C, Freeman K, Kraut RA. Outcomes of placing dental implants in patients taking oral bisphosphonates: a review of 115 cases. *J Oral Maxillofac Surg* 2008; 66(2):223-30.
- Bell BM, Bell RE. Oral bisphosphonates and dental implants: a retrospective study. *J Oral Maxillofac Surg* 2008; 66(5):1022-4.
- Lin JH. Bisphosphonates: a review of their pharmacokinetic properties. *Bone* 1996; 18(2):75-85.
- Marx RE. Bisphosphonate-induced osteonecrosis of the jaws: a challenge, a responsibility, and an opportunity. *Int J Periodontics Restorative Dent* 2008 Feb;28(1):5-6
- Serra MP, Llorca CS, Donat FJ. Oral implants in patients receiving bisphosphonates: a review and update. *Med Oral Patol Oral Cir Bucal* 2008; 13(12):E755-60.
- Marx RE, Cillo JE, Ulloa JJ. Oral bisphosphonate-induced osteonecrosis: risk factors, prediction of risk using serum CTX testing, prevention, and treatment. *J Oral Maxillofac Surg* 2007; 65(12):2397-410.