

Postoperative pain and one year follow up success rate of warm vertical compaction, single cone, coneless and bioconeless obturation methods

► **C. BUGEA¹, F. CERUTTI², F. ONGARO³, F. SFORZA⁴, A. SCARANO⁵, M. RAMPINO⁶, R. LUONGO⁷, E. PEDULLÀ⁸**

¹DDS, MSc private practice Gallipoli (LE), Italy

²DDS, PhD private practice Milano, Italy

³MD, DDS Private practice, Trieste, Italy

⁴DDS, MSc private practice Carovigno (BR), Italy

⁵MD, DDS, PhD, MSc, Department of Medical, Oral and Biotechnological Sciences, University of Chieti-Pescara, Chieti, Italy

⁶DDS private practice, Brindisi, Italy

⁷DDS private practice, Bari, Italy

⁸DDS, MSc, PhD Department of General Surgery and Surgical-Medical Specialties, University of Catania, Catania, Italy

TO CITE THIS ARTICLE

Bugea C, Cerutti F, Ongaro F, Sforza F, Scarano A, Rampino M, Luongo R, Pedullà E. Postoperative pain and one year follow up success rate of warm vertical compaction, single cone, coneless and bioconeless obturation methods. *J Osseointegr* 2022;14(4):209-216.

DOI 10.23805/JO.2022.14.04.3

ABSTRACT

Aim The aim of this study is to evaluate the post-operative pain after one week and the success rate of different endodontic obturation methods after one year follow-up.

Materials and methods Forty teeth were selected and randomly assigned to 4 groups. In group A teeth were treated using warm vertical compaction with gutta-percha and zinc oxide eugenol sealer, in group B the single cone technique was performed in association with a bioceramic sealer, in group C obturation was performed with thermoplastic guttapercha injection with bioceramic sealer (bioconeless technique), in group D teeth were treated with thermoplasticized gutta-percha injection with zinc-oxide-eugenol sealer (coneless technique). At the end of each procedure, a periapical radiograph was taken to assess the filling and a form was given to each patient to record analgesic intake.

Results After 1 week, in group A the analgesic intake was 3.1 ± 1.9 and 10/10 patients referred pain to percussion; in group B the analgesic intake was 1 ± 1.5 ; with 2/10 patients referring pain to percussion; in group C analgesic intake was 0.8 ± 0.9 with 1/10 patients having pain to percussion; in group D the analgesic intake was 3 ± 1.2 with 9/10 patients with pain to percussion. The data reported a significantly higher value of analgesic intake for the warm vertical compaction technique versus the single cone ($p < 0.05$) and bioconeless ($p < 0.05$); moreover, the coneless technique was associated with significantly higher analgesic intake versus single cone ($p < 0.05$) and bioconeless ($p < 0.05$) techniques. At the 1 year follow up the success rate was 100% for all groups.

Conclusion The results of this study show less post-operative pain and less analgesic intake associated with bioceramic sealer compared to the zinc oxide eugenol-based sealer.

KEYWORDS 3D obturation, Bioceramic sealer, Bioconeless, Coneless, Endodontic filling techniques, Postoperative pain, Root canal obturation, Thermoplastic gutta-percha injection, Warm obturation techniques.

INTRODUCTION

Endodontic post-operative pain is an unpleasant sensation which may occur in a range of time that goes from a few hours to different days after root canal treatment. In the literature, the reported prevalence varies widely, from 1.9% to 82.9% (1, 2). Many factors can be involved in the occurrence of post-operative pain, such as the status of the pulp, the presence of pre-operative pain, the number of appointments necessary to perform the root canal treatment, the number of root canals and the occurrence of mechanical, microbiological or chemical injuries to the peri-radicular tissues (i.e working length determination method, foramen enlargement, type of root canal sealer and obturation technique used) (3-5).

The obturation technique and root canal sealer chosen can affect post-operative pain because the filling materials can come in contact with the peridontium through the apex or lateral canals, thus stimulating an inflammatory response. According to Ruparel et al. (6) "sealers can directly activate trigeminal nociceptors, leading to a robust release of CGRP (calcitonine gene related peptide), and may therefore lead to pain and neurogenic inflammation".

Cold techniques, like lateral compaction or single cone, are associated with minimal material extrusion beyond the apex but poor adaptation to the canal walls (7).

Warm techniques, like warm vertical compaction or carrier-based obturation, are associated with better

adaptation to the canal walls; these technique can cause apical extrusion of sealer or filling material, that may be responsible for post-operative pain, especially when overfilling is preceded by overinstrumentation (8, 9).

Another warm technique exists, consisting in the obturation with an injection of thermoplasticized gutta-percha into the root canal system by means of a dedicated gutta-percha injector; it was described for the first time by Yee et al. in 1977 (10). Studies confirmed the effectiveness of this technique in filling the endodontic space (11, 12). Whereas result from laboratory studies have been encouraging, to date there is only limited data on clinical treatment outcomes in teeth filled with the thermoplastic injection of gutta-percha. These studies have reported complete healing rates ranging from 93,1% to 100% after observation periods from 6 months to 3 years (13-15). Literature shows different advantages of the injection of thermoplasticized gutta-percha compared to the other techniques: the procedure is time saving, it guarantees a good filling and it allows to fill complex anatomies. The disadvantages of this technique are mainly the risk of overfilling or incomplete filling (13-18).

The sealers most commonly used in endodontics are: resin-based, zinc oxide eugenol and, more recently, calcium silicate-based. Zinc oxide eugenol sealer is used as standard sealer for warm vertical compaction procedure, while root canal sealers based on epoxy resin are frequently used as a comparison for other sealers because of their favorable physicochemical properties and high adaptability to root canal walls (19). On the other hand, calcium silicate-based sealers demonstrated excellent physical properties and a kind of bioactivity: when they are in contact with tissue fluids, they release calcium ions and produce calcium hydroxide and apatite on their surfaces, with the potential to create an interfacial layer between the sealer and the dentin walls (20-22).

In vitro studies show excellent results and emphasize the fact that new calcium silicate sealers are indicated as the future of root canal obturation, compared to the resin-based and zinc-oxide sealer, but *in vivo* studies do not show any advantages in term of success rate between the sealers (23, 24). Calcium silicate-based sealers were firstly introduced as materials to be used in a single cone filling technique. With the increasing request by the clinicians to use them in warm compaction techniques as well, some *in vitro* studies were led to show the possibility to use bioceramic sealers in association with thermoplasticized techniques in order to increase the sealer penetration in the dental tubules or decrease the micro-leakage. Surprisingly, at the moment, none of the study present in literature take into consideration the idea to utilize thermoplasticized guttapercha injection with bioceramic sealer.

The aims of this study are: 1) to assess the post-operative

pain after one week and 30 days after the endodontic treatment of teeth filled with different techniques; and 2) to compare the one-year success rate between three different obturation techniques and two different sealers (considering as success the absence of swelling, pain to percussion, sinus tract and absence of lesions of endodontic origin in periapical X-rays).

The null hypothesis was that there was no significant difference between the techniques used for root canal filling and that the sealers did not have a role.

MATERIALS AND METHODS

Patients

Forty Caucasian subjects aged between 23 and 82 years who required an endodontic treatment of one permanent single canal, in the maxilla or the mandible, due to irreversible pulpitis or deep decay, were enrolled in the study. Teeth that presented alterations of the anatomy or that were not restorable were excluded. Only one tooth for patient was considered for the study. Medical history was recorded before treatment: patients with a history of systemic diseases or with an overall poor prognosis for their treatment were not included. Sensitivity tests, palpation, and percussion were performed for each tooth. One periapical Xray with phosphor plates (Dürr Dental SE, Bietigheim-Bissingen, Germany) was taken in order to obtain information about anatomy. The presence of periapical lesion excluded the tooth from the study.

Informed consent to undergo the treatment and follow-up and a second consent to participate in the study were obtained from all patients before starting the treatment. Endodontic therapy was performed using a standardized protocol that varied only in terms of the technique and sealer used for the obturation of the root canal. Two experienced endodontists performed the therapies.

Dental treatment

Local anesthesia was administered, the teeth were isolated under a rubber dam, and the root canals were subjected to preflaring using K-file 10 (Dentsply Sirona, Ballaigues, Switzerland). The working length was assessed with the apex locator (DentalPort ZX, J. Morita MFG. CORP®, Kyoto, Japan). Protaper Gold rotary files (Dentsply Sirona, Ballaigues, Switzerland) from S1 to F2, and F3 when necessary, were used to shape the canal in a crown down approach

During the shaping a 10% EDTA solution (Tubuliclean, Oгна lab, Muggiò, Italy) was used to rinse the root canal system. At the end of the shaping, the root canals were continuously irrigated with 5% sodium hypochlorite (Niolor 5-Dentale, Oгна lab, Muggiò, Italy) for 15 minutes. Activation of irrigants was performed with an ultrasonic tip IrriSafe 25 (Acteon Group, Merignac,

France) at 3 mm from the working length, with cycles of 30 seconds activation followed by 30 seconds of continuous irrigation.

Canals were dried with sterile paper points and a randomization table was followed to assign the cases to one obturation group.

- *Group A: Warm vertical compaction*

A dedicated gutta-percha point comfort fit series (Dentsply Sirona, Ballaigues, Switzerland) was selected and shortened 0.5 mm from the working length. The zinc-oxide-eugenol-based sealer Pulp Canal Sealer™ EWT (Kerr® Corporation, Orange, CA) was mixed according to the manufacturer's instructions. A System B (Sybrondental, Orange, CA, USA) tip plugger Fine was selected and tried into the canal in order to penetrate into the root canal until 5 mm from the working length. The master cone was then coated with sealer and inserted into the canal. Afterwards, the plugger was activated at the temperature of 200° C and inserted into the canal until the rubber stopper reached the coronal reference point at 5 mm from working length. The heat source was deactivated and the plugger was pushed in apical direction for 10 s. The power of the heat source was activated again for 1 s to separate the plugger from the compacted gutta-percha; then the plugger was extracted and a manual plugger was immediately inserted to pack the apical gutta-percha. Back-filling was achieved by using SuperEndo beta (B&L Biotech, Gyeonggido, Korea). Then a Machtou plugger 2 (Dentsply Sirona, Ballaigues, Switzerland) was used to pack the gutta-percha at the orifice level (Fig. 1).

- *Group B: Single cone technique with bioceramic sealer*
A gutta-percha point (Brasseler, Savannah, GA, USA) was fit into the root canal and shortened by 0,5 mm from the working length. The BC Sealer (Brasseler, Savannah, GA, USA) was first placed into the canal and injected with a dedicated tip; then the tip of the gutta-percha point was covered by the sealer. The cone was slowly inserted into the canal at working length. The excess of gutta-percha was removed from the canal

with a heat source Downpack (Kerr® Corporation, Orange, CA, USA) then a Machtou plugger 2 (Dentsply Sirona, Ballaigues, Switzerland) was used to pack the gutta-percha at the orifice level (Fig. 2).

- *Group C: Thermoplastic injection with bioceramic sealer (bioconeless technique)*

A small amount (2 mm) of bioceramic sealer (Brasseler, Savannah, GA, USA) was extruded from the syringe without the needle on a glass plate. A plastic Thermafil carrier #20 (Dentsply Sirona, Ballaigues, Switzerland) was used to carry the bioceramic sealer into the canal, 1 mm short to the working length, with an up and down and rotation movement of the carrier. The placement was considered ideal when the tip of the carrier was completely covered by the sealer. The second step was to inject the gutta-percha with a dedicated injector (SuperEndo beta, B&L Biotech, Gyeonggido, Korea) containing a new gutta-percha cylinder (Brasseler, Savannah, GA, USA) and equipped with a gauge 23 needle. The needle was inserted from 5 to 7 mm from the apex, in contact to the canal walls then, a soft erogation was performed in order to fill the entire canal. When the gutta-percha reached the pulp chamber, a gentle pressure of a Machtou plugger #2 was done in order to pack the gutta-percha inside the canal and to avoid surplus in the pulp chamber (Fig. 3).

- *Group D: Thermoplasticized gutta-percha injection (coneless technique)*

The sealer (Pulp Canal Sealer™ EWT; Kerr® Corporation, Orange, CA) was mixed according to the manufacturer's instructions and inserted in the canal with a paper point at working length, then a second paper point was utilized to eliminate the sealer excess. Then the obturation was carried out as described in group C (Fig. 4).

At the end of the obturation, a periapical radiograph was taken to assess the quality of the root canal filling (Fig. 5), and subsequently, the access cavity of each tooth was temporarily filled with cotton pellet and IRM (Dentsply Sirona, Ballaigues, Switzerland).

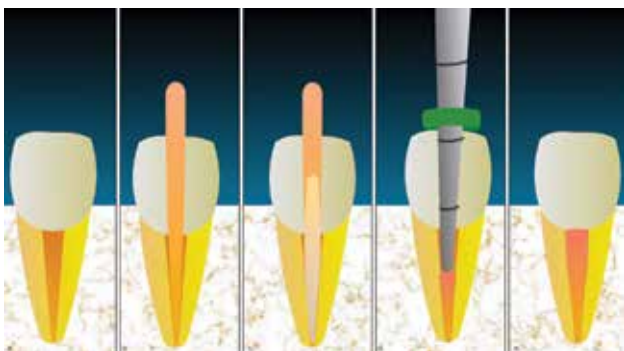


FIG. 1 Main steps of CWC technique. A) Starting point, canal irrigated and shaped. B) Cone fit. C) Cone placement with sealer. D) Last plugger pack the gutta-percha 5 mm close to the apex. E) Backfilling.

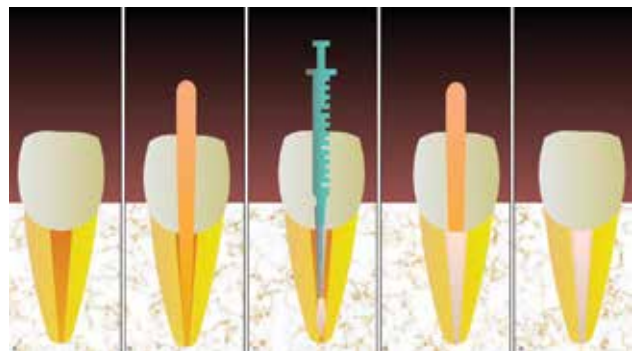


FIG. 2 Main steps of single cone and bioceramic technique. A) Starting point, canal irrigated and shaped. B) Cone fit. C) Injection of bioceramic sealer. D) Cone insertion in the endodontic space. E) Elimination of the gutta-percha in excess.

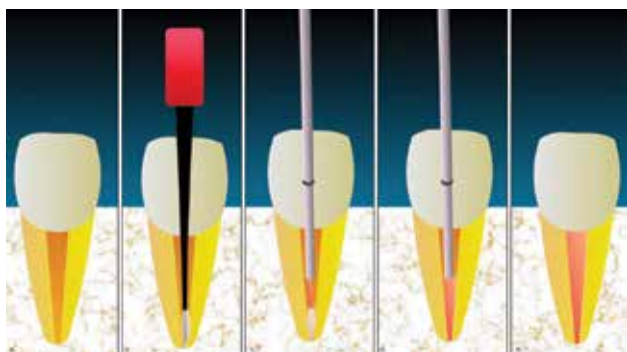


FIG. 3 Main steps of bioconeless technique. A) Starting point, canal irrigated and shaped. B) Bioceramic sealer placement with plastic carrier. C) Injection of guttapercha. D) Pushback sensation due to due apical complete filling. E) Total filling of the root canal system.

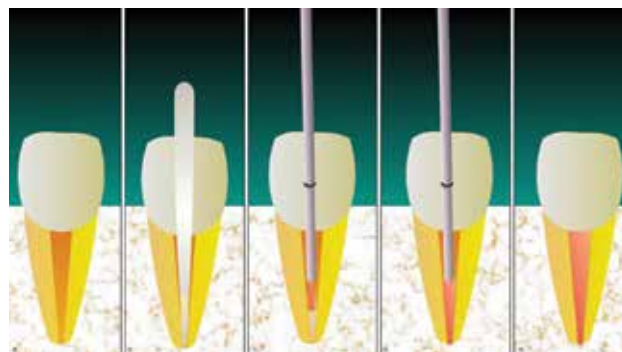


FIG. 4 Main steps of the coneless technique. A) Starting point, canal irrigated and shaped. B) ZOE sealer placement with paper point carrier. C) Injection of guttapercha. D) Pushback sensation due to due apical complete filling. E) Total filling of the root canal system.

Follow-up

A form was prepared for each patient to record the analgesic intake after endodontic treatment. Patient were scheduled 1 week later.

During the second appointment, patients brought back the form and a percussion test was done to evaluate the patient sensation after one week. In the same visit the coronal filling of the tooth was done. Another clinical control was done 30 days after the endodontic treatment, with a percussion test.

A clinical follow up with percussion test and a radiographic follow-up were performed for each tooth at 12 months from the baseline. Data were recorded in a dedicated chart and updated at every follow-up.

Two trained and calibrated examiners assigned a PAI score to each radiograph; in the case of disagreement, the highest score was retained. Following the assignment of a PAI score, the radiographs of each tooth were divided into two groups: absence of AP (score 1) or presence of AP (score 2–5).

Treatment success was defined according to strict criteria as the absence of pain or clinical evidence of inflammation or swelling and by conventional radiographic measures of complete healing/continuous presence of a normal periodontal ligament space (PAI score < 2).

The percussion test with a mirror handle was performed at time 0, after one week and one year later.

RESULTS

The collected data can be summarized as follows (Table 1, 2, 3).

For group A (warm vertical compaction) the analgesic intake was 3.1 ± 1.9 ; after 1 week 10/10 patients referred pain to percussion.

For group B (single cone and bioceramic sealer), the analgesic intake was 1 ± 1.5 ; after 1 week 2/10 patients felt pain to percussion.

For group C (bioconeless) 0.8 ± 0.9 after 1 week 1/10

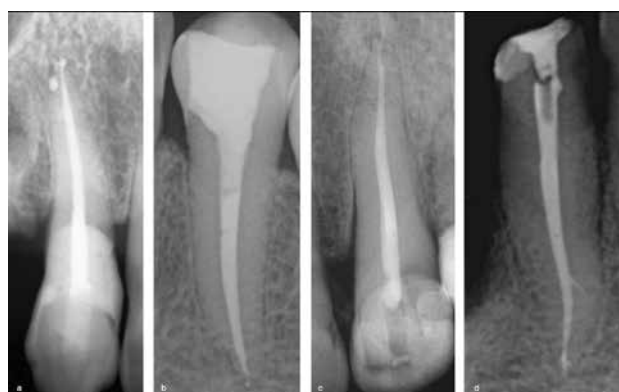

FIG. 5 Postoperative xrays. A) Obturation with warm vertical compaction (group A), notice the very lateral canal in the apical third. B) Obturation with single cone and bioceramic (group B). C) Bioconeless obturation (group C), note in the apical third the presence of a lateral canal and a spit of the canal at the apex. D) Coneless obturation (group D), notice the presence of a lateral canal at the end of the medium third.

patients had pain on percussion.

For group D (coneless) the analgesic intake was 3 ± 1.2 ; after 1 week 9/10 patients had pain to percussion.

At 30 days no tooth was positive to percussion test.

The data were analyzed with the software JMP to test the null hypothesis that the technique of filling did not influence the post-operative pain. The data were analyzed with Wilcoxon nonparametric test, with a p-value of 0.05.

The data reported a significantly higher value of analgesic intake for group A (warm vertical compaction technique) versus group B (single cone with bioceramic sealer) ($p < 0.05$) and versus group C (bioconeless) ($p < 0.05$). There was no significant difference between group A (warm vertical compaction) and group D (coneless) ($p > 0.05$). Moreover, group D (coneless) was associated with a significantly higher amount of analgesic intake if compared with group B (single cone with bioceramic sealer) ($p > 0.05$) and group C (bioconeless) ($p < 0.05$). No significant difference was found among group A (warm



Level	-Level	Z	p-value
Group D: coneless	Group C: bioconeless	3.24520	0.0012*
Group D: coneless	Group B: single cone and bioceramic	3.03494	0.0024*
Group D: coneless	Group A : warm vertical compaction	-0.15576	0.8762
Group C: bioconeless	Group B: single cone and bioceramic	-0.38212	0.7024
Group B: single cone and bioceramic	Group A : warm vertical Compaction	-3.03494	0.0024*
Group C: bioconeless	Group A: warm vertical compaction	-3.28771	0.0010*

TABLE 1 Analgesic intake after the therapy, split by technique and post-operative pain analysis. The warm vertical compaction and coneless techniques were associated to a significantly higher analgesic intake than the single cone (p=0.002) and bioconeless (p=0.001) techniques.

vertical compaction) and group D (coneless) (p>0.05). A similar situation was found while analyzing the pain to percussion after one week: the number of patients feeling pain was significantly higher in teeth belonging to group A (warm vertical compaction technique) with respect to group B (single cone with bioceramic sealer) (p<0.05) and to group C (bioconeless) (p<0.05). Similarly, teeth belonging to group D (coneless) were associated to a significantly higher pain to percussion 1 week after the procedure than teeth belonging to group B (single cone with bioceramic sealer) (p<0.05) or group C (bioconeless) (p<0.05). No significant difference was recorded between group A and group D and between group B and group C, showing the correlation between pain perception and type of sealer used in the root canal filling.

Two independent evaluators observed the X-rays to determine the success rate. The inter observer agreement was 100%, considering the fact that the sample consisted of teeth with a PAI index score = 1 at baseline. After 1 year of follow up the cumulative

Level	-Level	Z	p-value
Group D: coneless	Group C bioconeless	3.44353	0.0006*
Group D: coneless	Group B single cone and bioceramic	3.02279	0.0025*
Group D: coneless	Group A warm vertical Compaction	-0.5828	0.5828
Group C: bioconeless	Group B single cone and bioceramic	-0.9000	0.3681
Group B: single cone and bioceramic	Group A warm vertical compaction	-3.51454	0.0004*
Group C: bioconeless	Group A warm vertical compaction	-3.89896	<.0001*

TABLE 2 Results after the percussion test 1 week after the procedure. Group D (coneless) and group A (warm vertical compaction) showed significantly higher values of pain to percussion 1 week after treatment.

success rate was 100%, the PAI index was invariate for all teeth, since it was 1 at baseline and 1 at the 1 year follow up.

According to these findings, the null hypothesis was rejected, since there was a significant difference in the tested groups in terms of post-operative pain; moreover, the type of sealer significantly affected post-operative pain. The obturation technique seemed to have no effect on the outcome of the therapy.

DISCUSSION

Post-operative pain in endodontics can be associated with sealer composition and root canal obturation methods, in fact the extrusion or the direct contact of gutta-percha or sealer can activate the local inflammatory response in the periapical tissues (25).

In this study the pain level was measured by analgesic intake during the first week after the treatment and percussion test at the first follow up. Some studies used the Huskisson VAS (26), with an evaluation period that

	Group A warm vertical compaction	Group B single cone and bioceramic	Group C bioconeless	Group D coneless
Mean of analgesic intake + SD	3.1 ± 1.9	1 ± 1.5	0.8 ± 0.9	3 ± 1.2
Patients with pain on percussion after one week	10/10	2/10	1/10	9/10

TABLE 3. Mean of analgesic intake and number of patients with pain on percussion after one week.

did not exceed 72 h (27-30). These studies had similar findings, since they stated that the pain spontaneously subsides after some days. Moreover, there was no correlation between the filling technique selected and the post-operative pain. The authors' opinion is that post-operative pain may last longer than 72 h and patients may continue to have low degree pain on chewing: for this reason the number of FANS taken and the percussion test may play an interesting role in the evaluation of this parameter. In addition, a period of observation of the patient longer than 72 h could help in understanding the evolution of post-operative pain over time.

The results of this study showed that the use of zinc oxide eugenol sealer or bioceramic sealer significantly affected pain levels after root canal treatment.

At the moment there is no *in vivo* study comparing the outcomes of warm gutta-percha obturation with zinc oxide eugenol and bioceramic sealer, as all articles found in the literature use a resin-based sealer (AH-plus, Dentsply Sirona, Baillagues, Switzerland) as a control group (27-29). The obturation techniques used in this study were warm vertical compaction with zinc oxide eugenol, warm gutta-percha injection with both zinc oxide eugenol and bioceramic sealer and single cone + bioceramic sealer. The sealer utilized as a control in this study was a traditional zinc oxide eugenol sealer because it is used by the majority of dentists performing warm gutta-percha filling techniques. The changes in post-operative pain obtained using the same technique with different sealers suggest that the nature of the sealer affects post-operative pain (7).

In 1992 Markowitz et al. underlined the cytotoxic effect of eugenol in contact with the pulp tissue or in the periapical area (31): this finding is confirmed by the clinical results of this study, where patients treated with zinc oxide eugenol sealers showed higher FANS intake than those treated with bioceramic sealers.

The results of this study show just a little amount of post-operative pain associated with bioceramic sealer: the pain referred to the first hours after treatment could also be referred to the injection of local anesthetics, the pressure from a rubber dam clamp, or discomfort due to prolonged mouth opening. The absence of pain to percussion in both group with bioceramic sealer after one week underlines the low degree of irritation for periapical tissues compared to the zinc oxide eugenol-based sealer.

Despite the difference in post-operative pain, the use of different filling techniques had no effect on the outcome. In the present study the percentage of success after one year was 100% regardless of the technique selected for root canal filling. This result is probably due to the initial pulp status: the present study considered initial treatments on vital teeth, but the literature suggests that the presence of a lesion or a case of retreatment lower the percentage of success.

Another favorable condition for the high success rate of the present study is the fact that only teeth with one root canal were treated. In case of multi-rooted teeth the difficulty of the treatment increases and, thus, the possibly to have more pain due to the presence of potential periapical pain foci is higher (32-34). A last favorable condition was that, during the endodontic therapy, 15 minutes were dedicated to irrigation. Studies suggest that activation of irrigants can increase the power to dissolve organic tissues compared to the simple extrusion of irrigant into the root canal system with a syringe (32).

In vitro studies showed that after heat application, bioceramic-based root canal sealer may exhibit a reduction in setting time and flow into the root canal system due to the loss of water (35), but the material's chemical and physical properties were not affected by the heat (36-38). Even if some bioceramic sealers are dedicated and designated to be used with warm techniques, bioceramic sealers have identical chemistries except for modifications to the organic component and were resistant to heat (13). In general the most used devices for warm techniques work at an effective temperature lower than the temperature showed in the display, around 60°C, and it is safe for the physical and chemical properties of the bioceramic (39).

Bioceramic sealers compared to traditional sealers show "bioactivity", the potential to stimulate osteoblastic differentiation and to promote overexpression of osteo/cementogenic genes (40,41). The excellent biocompatibility with human gingival fibroblasts *in vitro*, enhanced cell viability, attachment, and mineralization gene expression on human periodontal ligament stem cells (40,42).

The basic PH induced by the calcium ions release, stimulate the formation of hydroxylapatite and the release of bone morphogenic protein 2 and alkaline phosphatase, and thus contributing to the mineralization process (43).

Santos et al. show *in vivo* biocompatibility of two different bioceramic sealers, with potential bioactivity when implanted in the subcutaneous tissue (44).

Several *in vivo* studies analyzed the behavior of the complex gutta-percha/sealer into the root canal system. De Angelis et al. showed that in terms of micro-leakage, the warm continuous wave of condensation technique seems promising even when combined to a bioceramic sealer (16-18, 40). Abdellatif et al. used the confocal microscope to show that the "hot modified technique" fills better the lateral anatomies such as lateral canals, dentinal tubules, etc. when compared to the single cone technique (16). Pontoriero et al. showed that bioceramic sealers can be used in combination with warm vertical condensation or carrier-based obturation, with better results in terms of micro-leakage than warm vertical compaction (18).

De-Deus in a micro-CT study in oval canals filled with

single cone technique with two different sealers, showed the presence of voids along the interface guttapercha sealer in all the specimens (45).

A study by Singh et al. concluded that Endosequence BC Sealer was found to be a better endodontic sealer if compared to resin-based and zinc oxide-eugenol-based sealer in terms of antibacterial activity (46).

The present study tried to investigate a topic that had not been considered by the literature but that could be clinically useful, since clinicians could benefit from knowing that a particular sealer, associated with the filling technique they perform, could lead to a significantly lower post-operative pain for the patient.

The weakness of this study is the small sample considered, but the authors will focus on increasing the number of treated teeth. No literature is available about the use of thermoplastic injection associated with bioceramic sealer. One of the main advantages of the gutta-percha injection technique is time saving, while there is no need for a cone fit x-ray. Another advantage comes after obturation, as it is easy to place a fiber post into the root canal. When filling only the apical third with gutta-percha and leaving the rest of the canal empty, it automatically grants more versatility for the restorative phase.

The thermoplastic injection with bioceramic sealer allows the clinician to have a clean pulp chamber, reducing the time required to remove the debris before doing the post-endo restoration. It also allows to fill a high number of lateral canals, thanks to the pressure developed by the gutta-percha, but at the same time permits to have a good apical control of the sealer, because introducing it with a plastic carrier helps minimizing the extrusion (47, 48).

CONCLUSIONS

Within the limits of the present study, it can be concluded that the thermoplastic gutta-percha injection, called "Coneless" technique, is promising when used in association with a tricalcium-silicate root canal sealer in terms of success rate and post-operative pain.

REFERENCES

- Glassman G, Krasner P, Morse DR, Rankow H, Lang J, Furst ML. A prospective randomized double-blind trial on efficacy of dexamethasone for endodontic interappointment pain in teeth with asymptomatic inflamed pulps. *Oral Surg Oral Med Oral Pathol* 1989;67(1):96-100.
- El Mubarak AH, Abu-bakr NH, Ibrahim YE. Postoperative pain in multiple-visit and single-visit root canal treatment. *J Endod* 2010;36(1):36-9.
- Alonso-Ezpeleta LO, Gasco-Garcia C, Castellanos-Cosano L, Martín-González J, López-Frías FJ, Segura-Egea JJ. Postoperative pain after one-visit root-canal treatment on teeth with vital pulps: comparison of three different obturation techniques. *Med Oral Patol Oral Cir Bucal* 2012;17(4):e721-7.
- Thakur S, Emil J, Paulaiian B. Evaluation of mineral trioxide aggregate as root canal sealer: A clinical study. *J Conserv Dent* 2013;16(6):494-8.
- Fonseca DA, Paula AB, Marto CM, Coelho A, Paulo S, Martinho JP, et al. Biocompatibility of root canal sealers: a systematic review of in vitro and in vivo studies. *Materials (Basel)* 2019 Dec 9;12(24):4113.
- Ruparel NB, Ruparel SB, Chen PB, Ishikawa B, Diogenes A. Direct effect of endodontic sealers on trigeminal neuronal activity. *J Endod* 2014;40(5):683-7.
- Atav Ates A, Dumani A, Yoldas O, Unal I. Post-obturation pain following the use of carrier-based system with AH Plus or iRoot SP sealers: a randomized controlled clinical trial. *Clin Oral Investig* 2019;23(7):3053-61.
- De-Deus G, Gurgel-Filho ED, Magalhães KM, Coutinho-Filho T. A laboratory analysis of gutta-percha-filled area obtained using Thermafil, System B and lateral condensation. *Int Endod J* 2006;39(5):378-83.
- Tennert C, Jungbäck IL, Wrbas KT. Comparison between two thermoplastic root canal obturation techniques regarding extrusion of root canal filling—a retrospective in vivo study. *Clin Oral Investig* 2013;17(2):449-54.
- Yee FS, Marlin J, Krakow AA, Gron P. Three-dimensional obturation of the root canal using injection-molded, thermoplasticized dental gutta-percha. *J Endod* 1977;3(5):168-74.
- Torabinejad M, Skobe Z, Trombly PL, Krakow AA, Grøn P, Marlin J. Scanning electron microscopic study of root canal obturation using thermoplasticized gutta-percha. *J Endod* 1978;4(8):245-50.
- Michanowicz AE, Michanowicz JP, Michanowicz AM, Czonstkowsky M, Zullo TP. Clinical evaluation of low-temperature thermoplasticized injectable gutta-percha: a preliminary report. *J Endod*. 1989;15(12):602-7.
- Marlin J, Krakow AA, Desilets RP, Jr., Gron P. Clinical use of injection-molded thermoplasticized gutta-percha for obturation of the root canal system: a preliminary report. *J Endod* 1981;7(6):277-81.
- Sobarzo-Navarro V. Clinical experience in root canal obturation by an injection thermoplasticized gutta-percha technique. *J Endod* 1991;17(8):389-91.
- Castellucci A, Gambarini G. Obturation of iatrogenically damaged root canals with injectable thermoplasticized gutta-percha: a case report. *Int Endod J* 1995;28(2):108-10.
- Abdellatif D, Amato A, Calapaj M, Pisano M, Iandolo A. A novel modified obturation technique using biosealers: an ex vivo study. *J Conserv Dent* 2021;24(4):369-73.
- De Angelis F, D'Arcangelo C, Buonvivere M, Argentino R, Vadini M. In vitro microleakage evaluation of bioceramic and zinc-eugenol sealers with two obturation techniques. *Coatings* 2021;11(6):727.
- Pontoriero DIK, Madaro G, Vanagolli V, Benedicenti S, Verniani G, Ferrari Cagidiaco E, et al. Sealing ability of a bioceramic sealer used in combination with cold and warm obturation techniques. *J Osseointegr* 2021;13(4):248-55.
- Marin-Bauza GA, Rached-Junior FJ, Souza-Gabriel AE, Sousa-Neto MD, Miranda CE, Silva-Sousa YT. Physicochemical properties of methacrylate resin-based root canal sealers. *J Endod* 2010;36(9):1531-6.
- Zhang W, Li Z, Peng B. Assessment of a new root canal sealer's apical sealing ability. *Oral Surg Oral Med Oral Pathol Oral Radiol Endod* 2009;107(6):e79-82.
- Parirokh M, Torabinejad M. Mineral trioxide aggregate: a comprehensive literature review—part III: clinical applications, drawbacks, and mechanism of action. *J Endod* 2010;36:400-3.
- Torabinejad M, Parirokh M. Mineral trioxide aggregate: a comprehensive literature review—part II: leakage and biocompatibility investigations. *J Endod* 2010;36(2):190-202.
- Chybowski EA, Glickman GN, Patel Y, Fleury A, Solomon E, He J. Clinical outcome of non-surgical root canal treatment using a single-cone technique with endosequence bioceramic sealer: A retrospective analysis. *J Endod* 2018;44(6):941-5.
- Bardini G, Casula L, Ambu E, Musu D, Mercadè M, Cotti E. A 12-month follow-up of primary and secondary root canal treatment in teeth obturated with a hydraulic sealer. *Clin Oral Investig* 2021;25(5):2757-64.
- Omoigui S. The biochemical origin of pain: the origin of all pain is inflammation and the inflammatory response. Part 2 of 3 - inflammatory

- profile of pain syndromes. *Med Hypotheses* 2007;69(6):1169-78.
26. Huskisson EC. Measurement of pain. *Lancet* 1974;2(7889):1127-31.
 27. Graunaite I, Skucaite N, Lodiene G, Agentiene I, Machiulskiene V. Effect of resin-based and bioceramic root canal sealers on postoperative pain: a split-mouth randomized controlled trial. *J Endod* 2018 May;44(5):689-693.
 28. Mekhdieva E, Del Fabbro M, Alovisi M, Comba A, Scotti N, Tumedei M, et al. Postoperative pain following root canal filling with bioceramic vs. traditional filling techniques: a systematic review and meta-analysis of randomized controlled trials. *J Clin Med* 2021;10(19)
 29. Tan HSG, Lim KC, Lui JN, Lai WMC, Yu VSH. Postobturation pain associated with tricalcium silicate and resin-based sealer techniques: a randomized clinical trial. *J Endod* 2021 Feb;47(2):169-177.
 30. Yu YH, Kushnir L, Kohli M, Karabucak B. Comparing the incidence of postoperative pain after root canal filling with warm vertical obturation with resin-based sealer and sealer-based obturation with calcium silicate-based sealer: a prospective clinical trial. *Clin Oral Investig* 2021 Aug;25(8):5033-5042.
 31. Markowitz K, Moynihan M, Liu M, Kim S. Biologic properties of eugenol and zinc oxide-eugenol. A clinically oriented review. *Oral Surg Oral Med Oral Pathol* 1992;73(6):729-37.
 32. Iandolo A, Simeone M, Orefice S, Rengo S. 3D cleaning, a perfected technique: thermal profile assessment of heated NaOCl. *G Ital Endod* 2017; 31(1):58-61.
 33. Ince B, Ercan E, Dalli M, Dulgergil CT, Zorba YO, Colak H. Incidence of postoperative pain after single- and multi-visit endodontic treatment in teeth with vital and non-vital pulp. *Eur J Dent* 2009;3(4):273-9.
 34. Arias A, de la Macorra JC, Hidalgo JJ, Azabal M. Predictive models of pain following root canal treatment: a prospective clinical study. *Int Endod J* 2013;46(8):784-93.
 35. Qu W, Bai W, Liang YH, Gao XJ. Influence of warm vertical compaction technique on physical properties of root canal sealers. *J Endod* 2016;42(12):1829-33.
 36. Camilleri J. Sealers and warm gutta-percha obturation techniques. *J Endod* 2015;41(1):72-8.
 37. McMichael GE, Primus CM, Opperman LA. Dentinal tubule penetration of tricalcium silicate sealers. *J Endod* 2016;42(4):632-6.
 38. Reynolds JZ, Augsburg RA, Svoboda KKH, Jalali P. Comparing dentinal tubule penetration of conventional and 'HiFlow' bioceramic sealers with resin-based sealer: An in vitro study. *Aust Endod J* 2020;46(3):387-93.
 39. Atmeh AR, Hadis M, Camilleri J. Real-time chemical analysis of root filling materials with heating: guidelines for safe temperature levels. *Int Endod J* 2020 May;53(5):698-708.
 40. Zhou HM, Du TF, Shen Y, Wang Z, Zheng YF, Haapasalo M. In vitro cytotoxicity of calcium silicate-containing endodontic sealers. *J Endod* 2015;41:56-61.
 41. Rodriguez-Lozano FJ, Lopez-Garcia S, Garcia-Bernal D, Tomas-Catala CJ, Santos JM, Llana C, Lozano A, Murcia L, Forner L. Chemical composition and bioactivity potential of the new Endosequence BC Sealer formulation HiFlow. *Int Endod J* 2020 Sep;53(9):1216-1228.
 42. Lopez-Garcia S, Myong-Hyun B, Lozano A, Garcia-Bernal D, Forner L, Llana C, Guerrero-Girones J, Murcia L, Rodriguez-Lozano FJ. Cytocompatibility, bioactivity potential, and ion release of three premixed calcium silicate-based sealers. *Clin Oral Investig* 2020;24:1749-1759.
 43. Pinheiro LS, Iglesias JE, Boijink D, Mestieri LB, Poli Kopper PM, Figueiredo JAP, Grecca FS. Cell Viability and tissue reaction of NeoMTA Plus: An in vitro and in vivo study. *J Endod* 2018;44:1140-1145.
 44. Santos JM, Coelho CM, Sequeira DB, Marques JA, Pereira JF, Sousa V, Palma PJ, Santos AC. Subcutaneous implantation assessment of new calcium-silicate based sealer for warm obturation. *Biomedicines* 2021;9:24.
 45. De-Deus G, Santos GO, Monteiro IZ, Cavalcante DM, Simões-Carvalho M, Belladonna FG, Silva EJNL, Souza EM, Licha R, Zogheib C, Versiani MA. Micro-CT assessment of gap-containing areas along the gutta-percha-sealer interface in oval-shaped canals. *Int Endod J* 2022 Jul;55(7):795-807.
 46. Singh G, Gupta I, Elshamy FMM, Boreak N, Homeida HE. In vitro comparison of antibacterial properties of bioceramic-based sealer, resin-based sealer and zinc oxide eugenol based sealer and two mineral trioxide aggregates. *Eur J Dent* 2016;10(3):366-9.
 47. Endodonzia Sld. Trattamento canalare primario. In: Berutti E, Gagliani M, editors. *Manuale di Endodonzia*. 1. Milano: Edra; 2020. p. 444.
 48. Bugea C, Pontoriero DIK, Rosenberg G, Suardi GMG, Calabria G, Pedullà E, La Rosa GRM, Sforza F, Scarano A, Luongo R et al. Maxillary premolars with four canals: case series. *Bioengineering* 2022, 9, 757.