

Histological and histomorphometrical evaluation of two types of bone substitutes in combination with i-PRF for bone regeneration in critical bone defects: An *in vivo* study

➤ **J. RIBEIRO DE ALBUQUERQUE BOIA, L. F. FERREIRA SOARES, G. P. PASSOS, J. DOS SANTOS NEVES, R. CÉLIO MARIANO, N. VITAL RIBEIRO JUNIOR¹**

Federal University of Alfenas, Alfenas, Minas Gerais, Brazil

¹Dental School

TO CITE THIS ARTICLE

Ribeiro de Albuquerque Boia J, Ferreira Soares LF, Passos GP, dos Santos Neves J, Célio Mariano R, Vital Ribeiro N Jr. Histological and histomorphometrical evaluation of two types of bone substitutes in combination with i-PRF for bone regeneration in critical bone defects: An *in vivo* study. *J Osseointegr* 2022;14(4):217-225.

DOI 10.23805/JO.2022.14.33

KEYWORDS Bone regeneration; Bone substitutes; Platelet-rich fibrin.

ABSTRACT

Aim This study aimed to evaluate the bone regeneration performance of two types of xenografts (Bio-Oss, Geistlich Pharma AG, Wolhusen, CH; Cerabone, Institut Straumann, Basel CH) isolated and associated with i-PRF, in critical bone defects in rat calvaria.

Materials and methods Surgical defects were performed and filled with different materials, according to the referred groups: clot (CG), autogenous bone (AG), Bio-Oss® (BO), Cerabone (CB), i-PRF homogenous (i-PRF), Bio-Oss associated with i-PRF (BOPRF) and Cerabone associated with i-PRF (CBPRF). The animals were euthanized for histological and histomorphometric analysis after 4 and 8 weeks. Statistical analysis for bone neoformation assessment was performed by ANOVA and complemented by Tukey's test.

Results The AG group exhibited the highest mean values for bone neoformation (37.83 ± 7.96) in this study. Among the bone substitutes, CBPRF group (18.79 ± 5.98) exhibited highest means ($p < 0.05$) compared to BO group (10.20 ± 2.82) and CG group (6.96 ± 3.29). i-PRF group (17.07 ± 4.95), BOPRF group (16.86 ± 6.14), BO group (10.20 ± 2.82), and CB group (16.15 ± 4.72) were not significant among them ($p > 0.05$).

Conclusions According to the results obtained in this study, it was observed that Cerabone® and Bio-Oss®, associated with i-PRF, exhibited a satisfactory applicability to fill critical defects, favoring the bone regeneration process.

dentistry. Currently, autogenous bone is still considered the gold standard for these procedures (1-4), due to its osteogenic, osteoinductive, and osteoconductive properties. However, its practical use is limited by its availability and invasiveness, with increased surgical morbidity associated with patient treatment (5). Thus, many commercial bone grafting materials, of allogeneic, xenogeneic, and alloplastic origins are extensively studied and developed. Although they do not have the same capabilities as autogenous grafts, they are effective, with certain limitations, for bone augmentation and treatment of periodontal and peri-implant defects (6, 7).

Deproteinized bovine bone mineral (DBBM) is a safe and biocompatible material with osteoconductive properties (8) and is considered the most widely used and documented biomaterial in bone reconstruction (7, 9, 10). As it is a natural biomaterial, the material may maintain its original surface characteristics, mimicking human bone. Thus, its receptor surface acts as a scaffold and becomes attractive to bone-forming cells (11, 12). Bio-Oss® (Geistlich Pharma AG, Wolhusen, Switzerland) is a DBBM with an open porous structure comparable to natural bone (13, 14). The material is deproteinized to completely remove immunogenic or potential pathogenic components by extraction with organic solvents followed by heat and alkaline treatment (15, 16). Histological studies confirmed the osteoconductive properties of Bio-Oss in implant installation procedures, alveolar ridge augmentation, and maxillary sinus lifting (9, 15, 17, 18).

Cerabone® (Botiss, Zossen, Germany) is a sintered DBBM with a trabecular bone-like structure (19). Sintered at a high temperature, results in a highly crystalline hydroxyapatite mineral with low bioresorbability (16,

INTRODUCTION

Bone substitutes are often used as part of grafting procedures for bone gain and filling defects in

20). Histological studies have reported osteoconductive properties for Cerabone, together with low immunogenic potential and the ability to support angiogenesis, which can be applied in several surgical and periodontal procedures, as well as Bio-Oss, in addition to being compared with it (21-23).

Faced with these different characteristics and limitations, the literature explores alternatives and associations with different products that can aggregate osteogenic cells and growth factors, such as the case of Platelet-Rich Fibrin (PRF) (24-26). As one of the production protocols, injectable Platelet-Rich Fibrin (i-PRF) is liquid and can be combined with bone substitute grafts (27). Thus, i-PRF works by enriching bone substitutes with growth factors, promotes fibroblast migration, and has the potential to release a higher concentration of cytokines and selective growth factors over time compared to other platelet concentrates described in the literature (28-33). Clinically, it also allows the bone graft particles to unite for better handling and compaction in the surgical bed (34, 35).

Therefore, this study aimed to evaluate the bone regeneration performance, through histologic and histomorphometric analysis, of Bio-Oss, and Cerabone, isolated and associated with i-PRF, in critical bone defects made in calvaria of systemically healthy rats.

MATERIALS AND METHODS

Animals

This study was conducted according to the ARRIVE guidelines for experimental studies with animals (36), and was approved by the Ethics Committee on the Use of Animals at the Federal University of Alfenas, Brazil (registration number: 60/2018).

For this study, it was calculated a sample size of 64 male Wistar/ST rats, seven-week-old (body weight 200-300 g) to be used after acclimatization (2 weeks). The rats were kept in cages at a constant temperature, with a 24-h light-dark cycle, and provided ad libitum access to food and water during the experiment period. These rats were randomly allocated into 7 groups of 8 animals each. Further 8 animals were used as donor rats to obtain the homogenous blood derivatives. In each experimental group, four rats were euthanized after 4 weeks and four were euthanized after 8 weeks postoperatively.

Two surgical defects, 6 mm in diameter each one, were performed in each rat, which received the same type of graft. Thus, sixteen bone defects were obtained per group, with eight bone defects evaluated within a period of 4 weeks and eight bone defects evaluated within a period of 8 weeks. The sample size was calculated (software GPower v3.1.9.2) according to an effect size of 0.4, significance level of 5% and power of 80%, demonstrating the need for at least 14 surgical defects per group.

Description of the groups

AG: Autogenous bone (positive control).

CG: Clot (negative control).

BO: Bio-Oss DBBM, Geistlich.

CB: Cerabone DBBM, Straumann.

i-PRF: Homogenous injectable platelet-rich fibrin.

BOPRF: Bio-Oss associated with i-PRF.

CBPRF: Cerabone associated with i-PRF.

i-PRF preparation

An intracardiac puncture was performed with a BD Vacutainer® Safety-Lok™ Blood Collection Set scalp (0.8 x 19 mm x 178 mm) directly in the animal's left ventricle and a 9 ml white Vacuette® tube (Z, without additives) was used. The blood volume taken from the donor rats to obtain the homogenous i-PRF was approximately 7 ml and centrifuged immediately (Centrifuge FibrinFuge25®, Montserrat). The collected blood was centrifuged once at 2700 rpm, for 6 minutes, without the addition of any anticoagulant, as recommended by Dohan, Choukroun (37). At the end of this process, it was possible to observe an orange-colored area at the top (i-PRF) and red blood cells at the bottom of the tube. Then, the tubes were opened carefully so as not to homogenize the material, and a syringe coupled to a hypodermic needle was used to collect the i-PRF.

Surgical procedures

General anesthesia was given by intramuscular injection of xylazine (10 mg/kg Xilazin®, Syntec, Brazil) and ketamine (90mg/kg Dopalen®, Ceva, Brazil). After shaving and painting with povidone-iodine (Riodeine®, Rioquímica Ltda, São José do Rio Preto, SP, Brazil) subcutaneous local anesthesia with 1% lidocaine and epinephrine (1:100,000) was performed and then an incision was performed in the rats' calvaria with a 15c scalpel blade and a full-thickness flap was detached in the posterior direction.

Two critically sized craniocaudal defects were performed on the calvaria of each rat to reduce the sample size, one more anterior and the other more posterior, with a 6 mm diameter trephine drill (Neodent, Curitiba, Brazil) attached to an NSK electric motor, rotation 1200 rpm, under abundant refrigeration with sterile saline solution (Physiological 0.9% Equiplax®, Aparecida de Goiânia, GO, Brazil). With the two critical defects created, the groups received the respective grafts. The positive control group received an autogenous bone graft (AG group) and the negative control group had wound closure with a clot (CG group). The group that received the autogenous bone had the bone circumference ostectomized and particulated in a bone grinder, then the crushed bone was placed again in the region of the defects. The clot group had defects made with a trephine, bone circumference exeresis, and wound closure only with the filling blood clot in the region of the defect.

The defects of the experimental groups were filled with

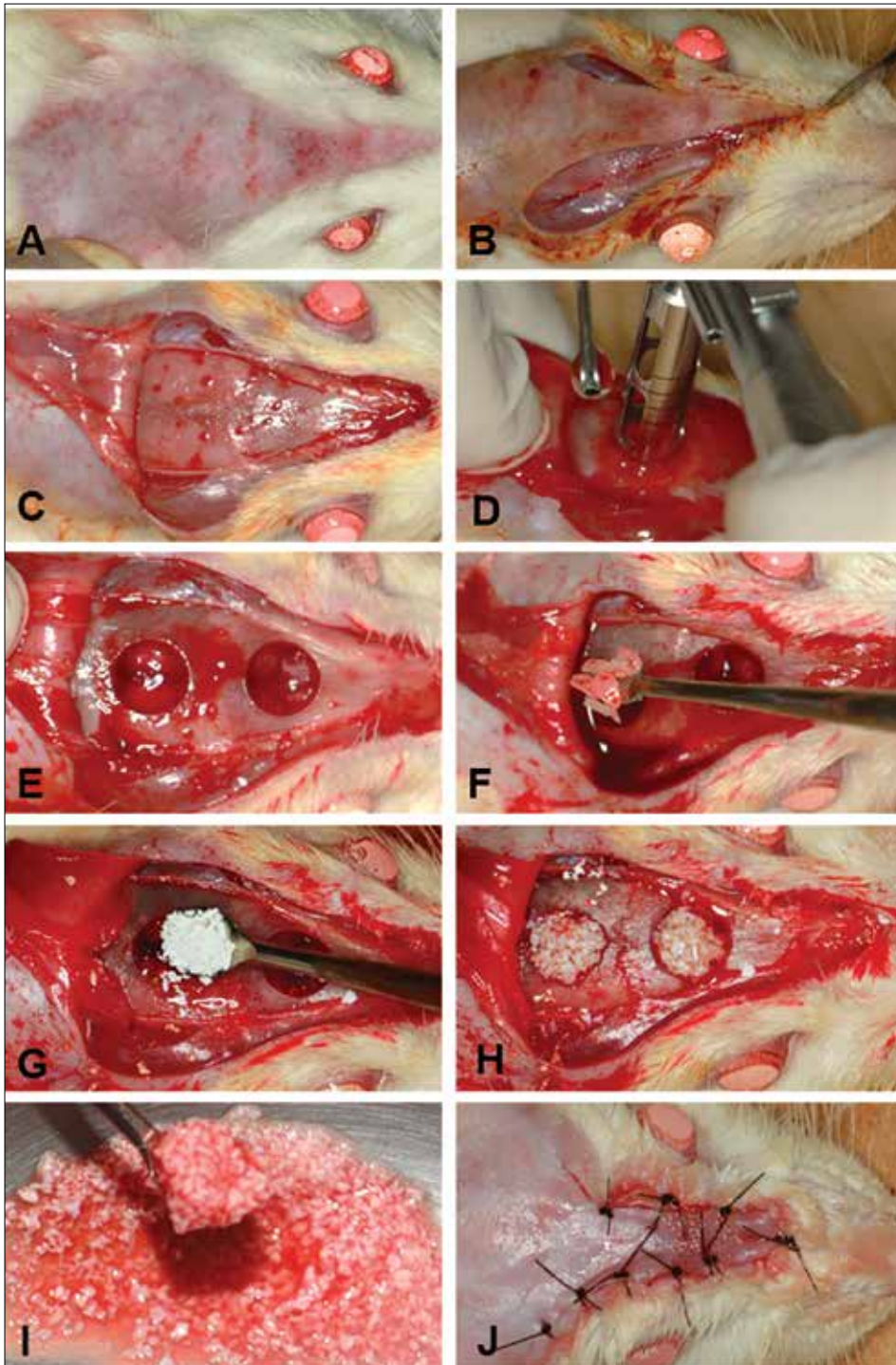


FIG. 1 Creation of critical defects and filling with the respective grafts: (A) Frontoparietal trichotomy; (B) Incision with a caudal base; (C) Full-thickness flap; (D) Creation of defects with a 6 mm trephine drill and irrigation with saline solution; (E) Defects created; (F) Filling the bone defect with particulated autogenous bone; (G) Aspect of the CB particles; (H) Bone defect filled with BO; (I) Aspect of the BOPRF; (J) Repositioning of the flap and suture.

Bio-Oss in the form of granules of 0.25-1.0 mm (group BO), Cerabone in the form of granules of 0.5 - 1.0 mm (group CB), Homogenous i-PRF (i-PRF group), Bio-Oss associated with i-PRF (BOPRF group) and Cerabone associated with i-PRF (CBPRF group). The grafts were deposited in a small metal tub and moistened with saline solution (BO and CB groups) or associated with i-PRF (BOPRF and CBPRF groups), then inserted into the defects with a Molt peeler. The flaps were repositioned and sutured with nylon 3.0 thread (Ethicon, Johnson & Johnson, Brazil) (Fig. 1).

After surgery, the animals received a single dose of Pentabiotic® (0.03 ml, 1.200.000 IU, Zoetis, Brazil) intramuscularly and a dose of Meloxicam 0.2% (0.2 ml Elo-xicam, Chemitec®, Brazil). An analgesic dose of 0.06 ml of tramadol hydrochloride 50 mg/ml was also applied intraperitoneally. Analgesic doses were administered at the end of the procedure and for another 3 days. Follow-up was carried out every day in the first week after surgery and then every 15 days for clinical evaluation. The animals were euthanized between 4 and 8 weeks after surgery through the CO₂ inhalation.

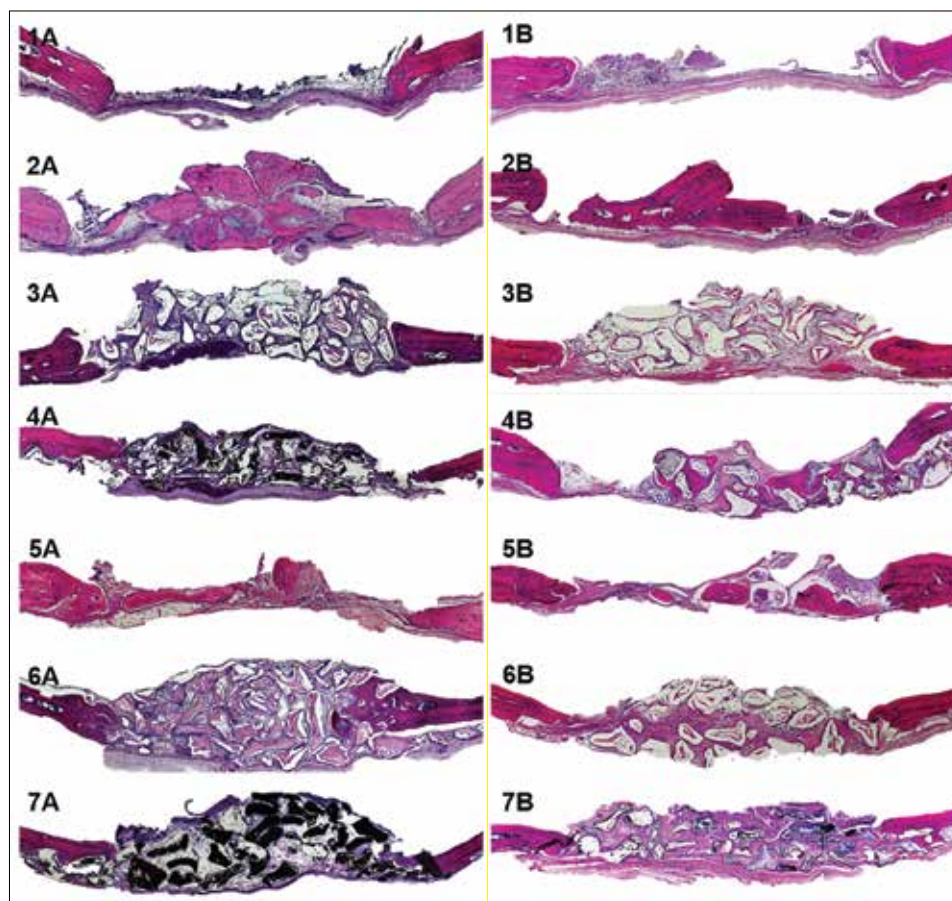


FIG. 2 Panoramic histological evaluation of bone repair according to the material used by each group. (1) CG group; (2) AG group; (3) BO group; (4) CB group; (5) i-PRF group; (6) BOPRF group; (7) CBPRF group. (A) 4 weeks; (B) 8 weeks. 25x magnification.

Histological analysis

The bone specimens were immediately fixed in 10% neutral buffered formalin solution for 24 hours, decalcified in an EDTA-based solution (Dinâmica Química Contemporânea Ltda®, Brazil) for 30 days, and embedded in paraffin. Serial cuts of transverse 5- μm -thick tissue sections were prepared from each specimen utilizing the standard histological technique and stained with hematoxylin-eosin solution for histological and histomorphometric analysis.

Histomorphometric analysis

The histological sections were selected so that the original surgical defect could be evaluated histomorphometrically in its entirety. The images of the histological sections were captured using a digital camera (AxioCam MRc 1.4 Mb, Carl Zeiss, Göttingen, Germany) coupled to a binocular optical microscope (Axio Lab, Carl Zeiss, Göttingen, Germany) with an original magnification of 2x, 5x, 25x, and 40x (N objective lens - Achroplan) and saved on a computer. The images were captured by the "AxioVision Rel. 4.8" software and their respective scale bars were used. The program allowed the calculation of bone formation area in square micrometers. The following criteria were used to standardize the histometric analysis of the digitized images (38).

a) The total area (TA) analyzed corresponded to the total area of the surgical defect. This area was determined

by identifying the internal and external surfaces of the original calvaria on the right and left margins of the surgical defect. These surfaces were connected with lines drawn following their curvatures and were measured at 2 mm at the ends of the specimens to establish the boundaries of the original surgical defect. The height of the total area was determined according to the thickness of the skullcap. The area of bone neoformation (ABN) was delineated within the limits of TA. The ABN was represented by a region of intense cellular activity, osteoid matrix, and bone mineralized with osteocytes, formed from the edge of the surgical defect towards the center.

b) TA was measured in μm^2 and considered 100% of the analyzed area. The ABN was also measured in μm^2 and was calculated as a percentage of TA.

c) Only the particles from the autogenous bone graft were measured in μm^2 and calculated as a percentage of TA.

Statistical analysis

The ABN was represented by the percentage of the area of new bone in relation to the TA of the surgical defect. The results were estimated as a mean \pm standard deviation (SD) and a median. The Shapiro-Wilk normality test was applied, and homogeneity of the results was observed ($p > 0.05$). Comparisons of individual interactions (bone substitutes, periods) were performed by 2-factor variance

analysis, ANOVA and complemented by the Tukey test. All data were analyzed using the software IBM SPSS 25.0 (Chicago, IL, USA) and the significance level was set to $p < 0.05$.

RESULTS

Descriptive histology

It was observed that no one of the specimens presented complete closure of the surgical defect, even in the 8-week experimental period, due to the critical size defect created. Regardless of the material used in the defect, there was no presence of inflammatory infiltrate after 4 weeks of repair.

CG group exhibited a smaller thickness than the original calvaria in the region of the defect, although it presented bone neoformation at the margins of the defect in most specimens. AG, BO, and CB groups presented bone neoformation from the edges of the defect towards the center and the graft particles filled most of the defect, maintaining the thickness of the calvaria. The i-PRF group maintained the original thickness of the calvaria and showed bone neoformation at the margins of the defects. Lastly, BOPRF and CBPRF groups showed bone neoformation in all specimens, progressing from the defect margins and approaching the central region. The thickness of the calvaria in the region of the defect was maintained and, in some specimens, the volume was greater (Fig. 2).

Histometric analysis

The evaluation between groups exhibited a statistically significant difference ($p < 0.01$) at the mean of the periods' assessment, but no significant difference was proved between the evaluation periods ($p > 0.05$) (Fig. 3). Conversely, the interaction between groups and evaluation periods was also not significant ($p > 0.05$) (Table 1).

The highest bone neoformation means corresponded to the AG groups at 8 and 4 weeks (42.12% and 33.53%, respectively), followed by the CBPRF group at 8 weeks (21.85%), while the lower means were expressed in

Groups	Evaluation periods		
	4 weeks	8 weeks	Mean of periods
	Mean \pm SD (Median)	Mean \pm SD (Median)	Mean \pm SD (Median)
AG	33.53 \pm 8.75 (33.71)	42.12 \pm 10.80 (42.07)ns	37.83 \pm 7.96 (40.14)(a)
CG	8.01 \pm 4.26 (7.76)	5.90 \pm 4.93 (4.20)ns	6.96 \pm 3.29 (5.97)(b)
BO	10.75 \pm 4.37 (10.09)	9.65 \pm 5.90 (7.10)ns	10.20 \pm 2.82 (10.39)(bc)
CB	16.84 \pm 7.67 (16.51)	15.45 \pm 5.48 (15.93)ns	16.15 \pm 4.72 (17.07)(cd)
i-PRF	15.43 \pm 5.42 (16.15)	18.72 \pm 7.99 (17.68)ns	17.07 \pm 4.95 (16.35)(cd)
BOPRF	16.47 \pm 5.52 (15.40)	17.24 \pm 11.31 (15.52)ns	16.86 \pm 6.14 (15.96)(cd)
CBPRF	15.72 \pm 9.30 (12.62)	21.85 \pm 6.09 (20.49)ns	18.79 \pm 5.98 (17.00)(d)

Obs.: Letters in parentheses indicate significant differences ($p < 0.05$) between the corresponding groups. ns-Indicates a non-significant value of p ($p > 0.05$) between periods.

TABLE 1 Statistics of the percentage of bone neoformation area in relation to the total area of the defect according to the group and period.

the CG groups at 8 and 4 weeks (5.90% and 8.01%, respectively), followed by BO at 8 and 4 weeks (9.65% and 10.75%, respectively). Considering the mean of the periods' assessment for bone neoformation, the AG group represented the highest results (37.83 \pm 7.96), followed by the CBPRF group (18.79 \pm 5.98), i-PRF group (17.07 \pm 4.95), BOPRF group (16.86 \pm 6.14), CB group (16.15 \pm 4.72), BO group (10.20 \pm 2.82), and then the CG group (6.96 \pm 3.29). A statistical difference between the reported outcomes was observed by the AG group from all other groups; between the CG group and the CB, i-PRF, BOPRF, and CBPRF groups; and between the BO group and CBPRF group.

All the described outcomes are better illustrated in Table 1 and Figure 3.

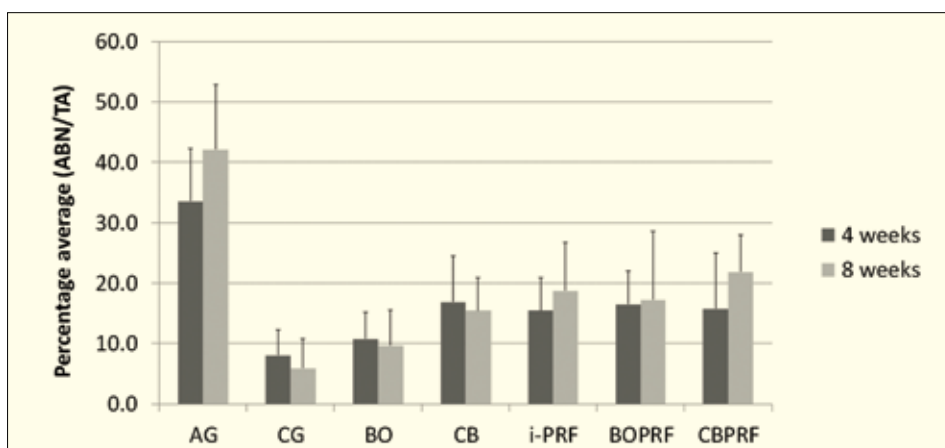


FIG. 3 Bone neoformation area (%) in relation to the total area of the defect according to the group and evaluation period.

DISCUSSION

This study aimed to evaluate the use of Bio-Oss, Cerabone, and i-PRF, alone or in combination, in critical size bone defects in rat calvaria. To the authors' best knowledge, no study in the literature has been found so far, in animals or humans, that compares and associates the materials cited in this study.

The application of BO and CB isolated in the critical defects created for this study did not show a statistical difference between them (Table 1). Even more, the BO group presented a lower result during the mean of periods if we consider that there was no difference ($p > 0.05$) with our control group, CG, differently from CB ($p < 0.05$). This result contradicts many studies that represent Bio-Oss as the most commonly used bone substitute with good clinical and histological outcomes that favor its use (8, 39, 40). However, a similar study of Grossi-Oliveira, Faverani (6) also reported other graft substitute materials, xenogeneic and alloplastic origin, with better results than the Bio-Oss itself. This could be justified by the slow and incomplete resorption rate of its particles, even exhibiting a superior rate of calcium release as compared to Cerabone as described by the literature (41, 42).

Mahesh and Mascarenhas (9) also investigated new bone formation with Bio-Oss or Cerabone in sinus augmentation procedures by histologic and histomorphometric analysis. Compared to our results, the use of the xenografts isolated also did not show a statistical difference between the groups but allowed new bone formation in the grafted sinuses, which have been considered both as predictable materials to apply in different clinical procedures. Furthermore, according to the authors, both materials show a similar healing process involving minimal inflammation and resulting in long-term success. Tawil and Barbeck (43) demonstrated that the use of Cerabone in patients submitted to maxillary sinus lift procedures, followed by the installation of implants, proved to be an adequate osteoconductive material with slow and effective resorption. Further, other human studies, where Cerabone and Bio-Oss were compared to assess the bone regeneration process did not observe any statistical difference between the analyzed groups and both xenografts proved to be effective in sinus enlargement of atrophic maxillae (44). Riachi and Naaman (45) also reported, through radiographic analysis of maxillary grafted sinuses, that Bio-Oss presented a significantly greater volumetric loss ($33.4 \pm 3.1\%$) than the initial graft size compared to Cerabone ($23.4 \pm 3.6\%$), being the largest amount of vertical loss of volume observed after one year of surgery.

The use of i-PRF has been proposed to agglutinate the particulated bone graft material in defects and to enhance its osteoconductive capacity (32). As explored by many studies in the last decade, the advantages of i-PRF carrying cytokines and growth factors, accelerate

cell migration, neovascularization, and the inflammatory response, favoring tissue repair (38, 46). Furthermore, its capacities can be extrapolated to many periodontal and surgical procedures, proving it to be a versatile, effective, and of low-cost obtention material.

Similar *in vivo* studies filling and associating i-PRF to DBBM grafts in calvarial defects are still scarce in the literature. Mu and He (47) investigated the angiogenic and osteogenic capacity of DBBM particles soaked in i-PRF for sinus grafting, in rabbits. In their study, i-PRF+DBBM accelerated vascular formation, bone remodeling, and substitution of bone graft materials at the early healing period, even though it failed to increase the bone volume in a long-term period, but demonstrating great potential in the application for sinus augmentations. Using L-PRF in calvarial defects, do Lago, Ferreira (11), and also exhibited that the association between Bio-Oss and L-PRF showed improvement in bone repair compared to the isolated application of the materials. Also confirming the potential of the platelet concentrates as described by recent studies.

Thus, these studies also suggest that the i-PRF used alone is already capable of promoting bone regeneration (48-50), a situation also observed in the present study, in which the i-PRF was superior to the CG group and statistically similar to the other groups.

In this study, only the AG particles were measured and included in the percentage calculation of new bone formation within the total area of the defect. DBBMs were not counted in the surgical defects. Thus, autogenous bone showed statistically significant differences from all groups, presenting numerical results considerably higher. Following the ARRIVE and the Ethics Committee for studies with animals' guidelines from the Federal University of Alfenas, the required blood volume and collection for the i-PRF preparation in rats is considered a terminal procedure (51). Therefore, homogenous i-PRF was chosen, since by using donor rats, it was possible to obtain a greater volume of i-PRF (52). Furthermore, as a possible concern due to this choice, there are reports of the use of donor rats to obtain platelet concentrates without interfering with their results (53). The risk of antigenicity seems to be insignificant when the donor animals are healthy, of the same age and species as the recipient animals (54). Thus, it can be suggested that the use of donor animals to obtain blood derivatives in experimental research with small models is feasible (52). In the present study, no antigenicity reaction was noted in the recipient rats.

Even though the scientific literature suggests an 8-week period for histological analysis of new bone formation in experimental models (55, 56), there was no statistically significant differences between groups during the 4-week and 8-week periods in this study. Conversely, some studies also suggest that it is important to evaluate the effects of grafting on bone regeneration after 60 days postoperatively. According to Sohn and Heo

(57), it would be a period long enough to observe the action of the material, evaluating the incorporation, remodeling, and resorption of the graft. Therefore, to confirm the capacity of new bone regeneration with the materials used in our study, a period longer than 8 weeks could confirm the study of Sohn and Heo (57). Finally, the scarcity of studies in the literature with the same study model for the comparison of different substitute materials, as performed by this study, is highlighted. This justifies its importance and highlights the need for further investigations into different bone substitutes and platelet concentrates with more homogeneous methodologies. Furthermore, the structural and financial limitations in the period and location of the same study limited the performance of more refined analyzes that could provide even more understanding about the proposed investigation.

CONCLUSION

According to the results obtained and within the limits of this study, it was observed that Cerabone® and Bio-Oss®, associated with i-PRF, exhibited a satisfactory applicability to fill critical defects, favoring the bone regeneration process.

Acknowledgments

This study was supported by the Dental School of the Federal University of Alfnas, Brazil, and by its Dentistry Science Master Degree Program, Unifal-MG, Brazil.

Funding

The authors did not receive any financial support in specific for this study.

Conflict of interest

The authors declare no conflict of interest.

REFERENCES

- Lu J, Hao Y, Zhao W, Lyu C, Zou D. Molecular, Cellular and Pharmaceutical Aspects of Autologous Grafts for Peri-implant Hard and Soft Tissue Defects. *Curr Pharm Biotechnol* 2017;18(1):85-94.
- Garcia-Gareta E, Coathup MJ, Blunn GW. Osteoinduction of bone grafting materials for bone repair and regeneration. *Bone* 2015;81:112-21.
- Artas G, Gul M, Acikan I, Kirtay M, Bozoglan A, Simsek S, et al. A comparison of different bone graft materials in peri-implant guided bone regeneration. *Braz Oral Res* 2018;32:e59.
- Shamsoddin E, Houshmand B, Golabgiran M. Biomaterial selection for bone augmentation in implant dentistry: A systematic review. *J Adv Pharm Technol Res* 2019;10(2):46-50.
- Dayashankara Rao JK, Bhatnagar A, Pandey R, Arya V, Arora G, Kumar J, et al. A comparative evaluation of iliac crest bone graft with and without injectable and advanced platelet rich fibrin in secondary alveolar bone grafting for cleft alveolus in unilateral cleft lip and palate patients: A randomized prospective study. *J Stomatol Oral Maxillofac Surg* 2020.
- Grossi-Oliveira G, Faverani LP, Mendes BC, Braga Polo TO, Batista Mendes GC, de Lima VN, et al. Comparative Evaluation of Bone Repair with Four Different Bone Substitutes in Critical Size Defects. *Int J Biomater* 2020;2020:5182845.
- Pichotano EC, de Molon RS, de Souza RV, Austin RS, Marcantonio E, Zandim-Barcelos DL. Evaluation of L-PRF combined with deproteinized bovine bone mineral for early implant placement after maxillary sinus augmentation: A randomized clinical trial. *Clin Implant Dent Relat Res* 2019;21(2):253-62.
- Kim YJ, Saiki CET, Silva K, Massuda CKM, de Souza Faloni AP, Braz-Silva PH, et al. Bone Formation in Grafts with Bio-Oss and Autogenous Bone at Different Proportions in Rabbit Calvaria. *Int J Dent* 2020;2020:2494128.
- Mahesh L, Mascarenhas G, Bhasin MT, Guirado C, Juneja S. Histological evaluation of two different anorganic bovine bone matrixes in lateral wall sinus elevation procedure: A retrospective study. *Natl J Maxillofac Surg* 2020;11(2):258-62.
- Brouwers J, van der Vorm LN, Buis S, Haumann R, Karanzai A, Konings J, et al. Implant stability in patients treated with platelet-rich fibrin and bovine bone substitute for alveolar ridge preservation is associated with peripheral blood cells and coagulation factors. *Clin Exp Dent Res* 2019;6(2):236-43.
- do Lago ES, Ferreira S, Garcia IR, Jr., Okamoto R, Mariano RC. Improvement of bone repair with I-PRF and bovine bone in calvaria of rats. histometric and immunohistochemical study. *Clin Oral Investig* 2019;24(5):1637-50.
- Lee DZ, Chen ST, Darby IB. Maxillary sinus floor elevation and grafting with deproteinized bovine bone mineral: a clinical and histomorphometric study. *Clin Oral Implants Res* 2012;23(8):918-24.
- Wang TY, Xu SL, Wang ZP, Guo JY. Mega-oss and Mega-TCP versus Bio-Oss granules fixed by alginate gel for bone regeneration. *BDJ Open*.2020;6:14.
- Jensen T, Schou S, Stavropoulos A, Terheyden H, Holmstrup P. Maxillary sinus floor augmentation with Bio-Oss or Bio-Oss mixed with autogenous bone as graft in animals: a systematic review. *Int J Oral Maxillofac Surg* 2012;41(1):114-20.
- Tapety FI, Amizuka N, Uoshima K, Nomura S, Maeda T. A histological evaluation of the involvement of Bio-Oss in osteoblastic differentiation and matrix synthesis. *Clin Oral Implants Res* 2004;15(3):315-24.
- Tadic D, Eppele M. A thorough physicochemical characterisation of 14 calcium phosphate-based bone substitution materials in comparison to natural bone. *Biomaterials*. 2004;25(6):987-94.
- Schwartz Z, Weesner T, van Dijk S, Cochran DL, Mellonig JT, Lohmann CH, et al. Ability of deproteinized cancellous bovine bone to induce new bone formation. *J Periodontol* 2000;71(8):1258-69.
- Zhao H, Hu J, Zhao L. Histological analysis of socket preservation using DBBM. A systematic review and meta-analysis. *J Stomatol Oral Maxillofac Surg*. 2020.
- Hing KA, Best SM, Bonfield W. Characterization of porous hydroxyapatite. *J Mater Sci Mater Med* 1999;10(3):135-45.
- Trajkovski B, Jaunich M, Muller WD, Beuer F, Zafiroopoulos GG, Houshmand A. Hydrophilicity, viscoelastic, and physicochemical properties variations in dental bone grafting substitutes. *Materials (Basel)*.2018;11(2).
- Sargolzaie N, Rafiee M, Salari Sedigh H, Zare Mahmoudabadi R, Keshavarz H. Comparison of the effect of hemihydrate calcium sulfate granules and Cerabone on dental socket preservation: An animal experiment. *J Dent Res Dent Clin Dent Prospects* 2018;12(4):238-44.
- Chernenko V, Lyubchenko A. [Comparative Morphological Study of Guided Bone Tissue Regeneration Using Xenogenic Osteoplastic Material Bioplast-Dent and Cerabone]. *Georgian Med News* 2018(278):151-8.
- El Chaar E, Zhang L, Zhou Y, Sandgren R, Fricain JC, Dard M, et al. Osseointegration of Superhydrophilic Implants Placed in Defect Grafted Bones. *Int J Oral Maxillofac Implants* 2019;34(2):443-50.
- Miron RJ, Xu H, Chai J, Wang J, Zheng S, Feng M, et al. Comparison of platelet-rich fibrin (PRF) produced using 3 commercially available centrifuges at both high (~ 700 g) and low (~ 200 g) relative centrifugation forces. *Clin Oral Investig* 2020;24(3):1171-82.
- Faot F, Deprez S, Vandamme K, Camargos GV, Pinto N, Wouters J, et al. The effect of L-PRF membranes on bone healing in rabbit tibiae bone defects: micro-CT and biomarker results. *Sci Rep* 2017;7:46452.
- Zumaran CC, Parra MV, Olate SA, Fernandez EG, Munoz FT, Haidar ZS. The 3 R's for Platelet-Rich Fibrin: A "Super" Tri-Dimensional Biomaterial for Contemporary Naturally-Guided Oro-Maxillo-Facial Soft and Hard Tissue

		AG		CG		B0		CB		i-PRF		BOPRF		CBPRF	
		30 Days	60 Days	30 Days	60 Days	30 Days	60 Days	30 Days	60 Days	30 Days	60 Days	30 Days	60 Days	30 Days	60 Days
D1	TA	1578601.12	1138553.14	1795097.84	1609644.40	1308532.85	2006780.28	2132922.72	9691252.24	1124107.04	917261.98	2215217.98	4185261.80	852191.70	1562314.54
	ABN	624916.73	455443.38	264431.24	123337.35	90527.71	438214.12	608375.56	168249.78	245669.80	102451.08	233212.84	1647517.52	116365.49	229670.70
	%	39.59%	40.00%	14.73%	7.66%	6.92%	21.84%	28.52%	17.36%	21.85%	11.17%	10.53%	39.36%	13.65%	14.70%
D2	TA	1321812.57	1621129.92	1194629.29	1583540.94	1236120.56	1370021.35	1161246.62	1156343.13	789246.04	1860931.40	1227242.09	1235760.40	959106.80	1176951.64
	ABN	528677.37	840498.02	103763.67	60216.36	124819.60	136528.47	101458.06	171475.64	133043.04	262785.74	222027.23	149237.20	79942.64	233144.01
	%	40.00%	51.85%	8.69%	3.80%	10.10%	9.97%	8.74%	14.83%	16.86%	14.12%	18.09%	12.08%	8.34%	19.81%
D1	TA	1105276.20	1421507.92	1540830.42	1486951.58	838548.52	2373609.74	952812.23	1774981.66	904633.19	1889919.44	2178002.39	1791172.40	1347764.03	732241.21
	ABN	294908.90	627274.48	119136.35	14479.16	55996.01	350982.34	199947.55	303076.75	175673.57	670710.44	608936.27	450538.92	121494.12	154930.16
	%	26.68%	44.13%	7.73%	0.97%	6.68%	14.79%	20.98%	17.07%	19.42%	35.49%	27.96%	25.15%	9.01%	21.16%
D2	TA	1740065.82	2216817.23	1216652.02	1160532.91	996745.33	1039056.04	1366314.00	1298563.98	624981.74	904124.35	1373847.65	1145419.34	644649.46	1469382.97
	ABN	686816.14	1134065.63	28143.57	105409.13	100343.17	60968.07	208642.54	221331.55	96434.68	179849.85	265896.01	88464.34	74688.79	511342.60
	%	39.47%	51.16%	2.31%	9.08%	10.07%	5.87%	15.27%	17.04%	15.43%	19.89%	19.35%	7.72%	11.59%	34.80%
D1	TA	1670316.74	1933839.32	1253827.96	1536158.24	1805357.49	1376345.64	1011716.82	2070542.10	1426761.66	1167855.09	271020.42	1758643.95	1332277.08	2250840.93
	ABN	774908.98	721188.21	34365.33	33518.14	328946.55	111583.98	102570.04	534785.56	307254.12	180631.93	438492.86	333345.95	487114.77	571529.34
	%	46.39%	37.29%	2.74%	2.18%	18.22%	8.11%	10.14%	25.83%	21.54%	15.47%	16.18%	18.95%	36.56%	25.39%
D2	TA	1080068.20	875836.80	1171536.01	1095413.06	1356662.33	1086944.31	939337.56	1542766.70	660635.34	1360029.34	1280797.12	1251108.57	1141827.64	1545198.62
	ABN	254733.24	176761.71	88372.74	176135.50	90707.84	50146.16	76741.77	137600.90	69316.22	297589.34	154462.16	100700.10	231502.93	302476.70
	%	23.58%	20.18%	7.54%	16.08%	6.69%	4.61%	8.17%	8.92%	10.49%	21.88%	12.06%	8.05%	20.27%	19.58%
D1	TA	1716311.69	1784934.01	1126406.78	1412897.08	3584796.56	1457828.06	3343686.60	2774172.12	1323709.20	2263829.87	1985570.41	2087591.94	2897502.66	3289497.16
	ABN	422156.48	702164.77	141472.55	65033.92	578924.01	88619.56	841390.14	390545.05	114611.96	246509.65	258404.19	431083.74	463920.06	718234.72
	%	24.60%	39.34%	12.56%	4.60%	16.15%	6.08%	25.16%	14.08%	8.66%	10.89%	13.01%	20.65%	16.01%	21.83%
D2	TA	1393170.80	1494227.50	1311737.96	1259719.40	1067644.28	121181.32	1129311.20	1124959.52	905921.84	1380049.69	853434.09	1145307.00	931232.29	2436053.16
	ABN	389414.60	792447.84	102038.33	35897.20	119620.24	72129.47	200412.89	95399.26	83160.96	287627.24	124711.97	68497.35	95909.20	427977.62
	%	27.95%	53.03%	7.78%	2.85%	11.20%	5.95%	17.75%	8.48%	9.18%	20.84%	14.61%	5.98%	10.30%	17.57%
Mean (%)		33.53%	42.12%	8.01%	5.90%	10.75%	9.65%	16.84%	15.45%	15.43%	18.72%	16.47%	17.24%	15.72%	21.85%

SUPPLEMENTARY TABLE 1 Distribution of total area and bone neoformation and their respective percentages according to groups and experimental periods Obs.: D1: Anterior surgical defect; D2: Posterior surgical defect; TA: Total area; ABN: Area of bone neoformation.

- Repair, Reconstruction and Regeneration. *Materials* (Basel) 2018;11(8).
27. Karimi K, Rockwell H. The Benefits of Platelet-Rich Fibrin. *Facial Plast Surg Clin North Am* 2019;27(3):331-40.
 28. Ghanaati S, Herrera-Vizcaino C, Al-Maawi S, Lorenz J, Miron RJ, Nelson K, et al. Fifteen Years of Platelet Rich Fibrin in Dentistry and Oromaxillofacial Surgery: How High is the Level of Scientific Evidence? *J Oral Implantol* 2018;44(6):471-92.
 29. Miron RJ, Zucchelli G, Pikos MA, Salama M, Lee S, Guillemette V, et al. Use of platelet-rich fibrin in regenerative dentistry: a systematic review. *Clin Oral Investig* 2017;21(6):1913-27.
 30. Kobayashi E, Fluckiger L, Fujioka-Kobayashi M, Sawada K, Sculean A, Schaller B, et al. Comparative release of growth factors from PRP, PRF, and advanced-PRF. *Clin Oral Investig* 2016;20(9):2353-60.
 31. Kyyak S, Blatt S, Schiegnitz E, Heimes D, Staedt H, Thiem DGE, et al. Activation of Human Osteoblasts via Different Bovine Bone Substitute Materials With and Without Injectable Platelet Rich Fibrin in vitro. *Front Bioeng Biotechnol* 2021;9:599224.
 32. Mourao CF, Valiense H, Melo ER, Mourao NB, Maia MD. Obtention of injectable platelets rich-fibrin (i-PRF) and its polymerization with bone graft: technical note. *Rev Col Bras Cir* 2015;42(6):421-3.
 33. Ozsagir ZB, Saglam E, Sen Yilmaz B, Choukroun J, Tunali M. Injectable platelet-rich fibrin and microneedling for gingival augmentation in thin periodontal phenotype: A randomized controlled clinical trial. *J Clin Periodontol* 2020;47(4):489-99.
 34. Wang X, Zhang Y, Choukroun J, Ghanaati S, Miron RJ. Behavior of Gingival Fibroblasts on Titanium Implant Surfaces in Combination with either Injectable-PRF or PRP. *Int J Mol Sci* 2017;18(2).
 35. Thanasrisuebwong P, Kiattavorncharoen S, Surarit R, Phruksaniyom C, Ruangsawasdi N. Red and Yellow injectable platelet-rich fibrin demonstrated differential effects on periodontal ligament stem cell proliferation, migration, and osteogenic differentiation. *Int J Mol Sci* 2020;21(14).
 36. Percie du Sert N, Ahluwalia A, Alam S, Avey MT, Baker M, Browne WJ, et al. Reporting animal research: Explanation and elaboration for the ARRIVE guidelines 2.0. *PLoS Biol* 2020;18(7):e3000411.
 37. Dohan DM, Choukroun J, Diss A, Dohan SL, Dohan AJ, Mouhyi J, et al. Platelet-rich fibrin (PRF): a second-generation platelet concentrate. Part II: platelet-related biologic features. *Oral Surg Oral Med Oral Pathol Oral Radiol Endod* 2006;101(3):e45-50.
 38. Messori MR, Nagata MJ, Mariano RC, Dornelles RC, Bomfim SR, Fucini SE, et al. Bone healing in critical-size defects treated with platelet-rich plasma: a histologic and histometric study in rat calvaria. *J Periodontol Res* 2008;43(2):217-23.
 39. Al-Askar M, Javed F, Al-Hezaimi K, Al-Hamdan KS, Ramalingam S, Aldahmash A, et al. Guided Bone Regeneration in standardized calvarial defects in rats using bio-oss and beta-tricalcium phosphate with adjunct platelet-derived growth factor therapy: a real-time in vivo microcomputed tomographic, biomechanical, and histologic analysis. *Int J Periodontics Restorative Dent* 2016;36 Suppl:s61-73.
 40. Cha JK, Song YW, Park SH, Jung RE, Jung UW, Thoma DS. Alveolar ridge preservation in the posterior maxilla reduces vertical dimensional change: A randomized controlled clinical trial. *Clin Oral Implants Res*. 2019;30(6):515-23.
 41. Zhao H, Hu J, Zhao L. Histological analysis of socket preservation using DBBM. A systematic review and meta-analysis. *J Stomatol Oral Maxillofac Surg* 2020;121(6):729-35.
 42. Berberi A, Samarani A, Nader N, Noujeim Z, Dagher M, Kanj W, et al. Physicochemical characteristics of bone substitutes used in oral surgery in comparison to autogenous bone. *Biomed Res Int* 2014;2014:320790.
 43. Tawil G, Barbeck M, Unger R, Tawil P, Witte F. Sinus Floor Elevation Using the Lateral Approach and Window Repositioning and a Xenogeneic Bone Substitute as a Grafting Material: A Histologic, Histomorphometric, and Radiographic Analysis. *Int J Oral Maxillofac Implants* 2018;33(5):1089-96.
 44. Panagiotou D, Ozkan Karaca E, Dirikan Ipci S, Cakar G, Olgac V, Yilmaz S. Comparison of two different xenografts in bilateral sinus augmentation: radiographic and histologic findings. *Quintessence Int* 2015;46(7):611-9.
 45. Riachi F, Naaman N, Tabarani C, Aboelsaad N, Aboushelib MN, Berberi A, et al. Influence of material properties on rate of resorption of two bone graft materials after sinus lift using radiographic assessment. *Int J Dent* 2012;2012:737262.
 46. Bansal C, Bharti V. Evaluation of efficacy of autologous platelet-rich fibrin with demineralized-freeze dried bone allograft in the treatment of periodontal intrabony defects. *J Indian Soc Periodontol* 2013;17(3):361-6.
 47. Mu Z, He Q, Xin L, Li Y, Yuan S, Zou H, et al. Effects of injectable platelet rich fibrin on bone remodeling in combination with DBBM in maxillary sinus elevation: a randomized preclinical study. *Am J Transl Res* 2020;12(11):7312-25.
 48. Tambella AM, Bartocetti F, Rossi G, Galosi L, Catone G, Falcone A, et al. Effects of Autologous platelet-rich fibrin in post-extraction alveolar sockets: a randomized, controlled split-mouth trial in dogs with spontaneous periodontal disease. *Animals* (Basel) 2020;10(8).
 49. You J-S, Kim S-G, Oh J-S, Kim J-S. Effects of Platelet-Derived Material (Platelet-Rich Fibrin) on Bone Regeneration. *Implant Dentistry* 2019;28(3):244-55.
 50. Du J, Mei S, Guo L, Su Y, Wang H, Liu Y, et al. Platelet-rich fibrin/aspirin complex promotes alveolar bone regeneration in periodontal defect in rats. *J Periodontol Res* 2018;53(1):47-56.
 51. Parasuraman S, Raveendran R, Kesavan R. Blood sample collection in small laboratory animals. *J Pharmacol Pharmacother* 2010;1(2):87-93.
 52. Ghanaati S, Al-Maawi S, Herrera-Vizcaino C, Alves GG, Calasans-Maia MD, Sader R, et al. A Proof of the low speed centrifugation concept in rodents: new perspectives for in vivo research. *Tissue Eng Part C Methods* 2018;24(11):659-70.
 53. Oliveira MR, de CSA, Ferreira S, Avelino CC, Garcia IR, Jr., Mariano RC. Influence of the association between platelet-rich fibrin and bovine bone on bone regeneration. A histomorphometric study in the calvaria of rats. *Int J Oral Maxillofac Surg* 2015;44(5):649-55.
 54. Aspenberg P, Virchenko O. Platelet concentrate injection improves Achilles tendon repair in rats. *Acta Orthop Scand* 2004;75(1):93-9.
 55. Cardaropoli G, Araujo M, Lindhe J. Dynamics of bone tissue formation in tooth extraction sites. An experimental study in dogs. *J Clin Periodontol* 2003;30(9):809-18.
 56. Choukroun J, Diss A, Simonpieri A, Girard MO, Schoeffler C, Dohan SL, et al. Platelet-rich fibrin (PRF): a second-generation platelet concentrate. Part IV: clinical effects on tissue healing. *Oral Surg Oral Med Oral Pathol Oral Radiol Endod* 2006;101(3):e56-60.
 57. Sohn DS, Heo JU, Kwak DH, Kim DE, Kim JM, Moon JW, et al. Bone regeneration in the maxillary sinus using an autologous fibrin-rich block with concentrated growth factors alone. *Implant Dent* 2011;20(5):389-95.