

> FRANCESCO GRECCHI¹, ILARIA ZOLLINO², VITTORIA PERROTTI³, FRANCESCO CARINCI²

¹ Maxillofacial Surgery, Galeazzi Hospital, Milan, Italy

² Maxillofacial Surgery, University of Ferrara, Ferrara, Italy

³ Dental School, University of Chieti-Pescara, Chieti, Italy

Williams-Beuren Syndrome treated with orthognathic surgery and combined partial glossectomy: case report

ABSTRACT

Background Williams syndrome, also known as Williams-Beuren syndrome (WBS), is a multi-systems, congenital and rare disorder involving the cardiovascular system, connective tissue, and the central nervous system. It is a genetic disorder caused by a hemizygous microdeletion of chromosome 7q11.23. Here we report a case of WBS treated with bimaxillary osteotomies and glossectomy.

Case report Orthognathic surgery was undertaken one year after the first diagnosis and the beginning of the orthodontic treatment. The maxilla was advanced at a Le Fort I of about 4 mm and was fixed with two angled plates, one on each side, applied laterally to the pyriform aperture. The lateral part of the maxilla was stabilized with wires. In addition, bilateral mandibular sagittal osteotomies were carried out together with a midline osteotomy. A partial glossectomy was performed. Intermaxillary adaptation was supported by applying soft elastics according to the concept of semi-rigid bone fixation. Two months post-surgery the occlusion was Angle class I with a well defined overbite and overjet. The healing was uneventful. Functional limitations or nerve disturbances did not occur. The mini-plates remained in situ.

In the case reported the "keyhole" partial glossectomy was performed in combination with the orthognathic surgery. No complication was recorded in the postoperative period and the patient had a successful outcome.

KEY WORDS Glossectomy; Orthognathic surgery; Williams syndrome.

INTRODUCTION

Williams syndrome, also known as Williams-Beuren syndrome (WBS), is a multi-system, congenital and rare disorder involving the cardiovascular system, connective tissue, and the central nervous system (1). It is a genetic disorder caused by a hemizygous microdeletion of chromosome 7 (7q11.23). It was first reported independently by Williams et al. and Beuren et al., who described children with a number of developmental and physical abnormalities (2, 3). In addition, children with WBS have a distinct cognitive profile associated with mental retardation, with relatively preserved language abilities but generally poor visuo-spatial skills (4).

Physical features include characteristic facial features with full prominent cheeks, wide mouth, long philtrum, small nose with depressed nasal bridge, heavy orbital ridges, medial eyebrow flare, dental abnormalities, hoarse voice, growth retardation, and cardiovascular abnormalities (most commonly supravalvular aortic stenosis and/or peripheral pulmonary artery stenosis) (1). Facial features are summarized in the term "elfin face". Furthermore, cephalometric measurements often show an anterior inclination of the maxilla, a high mandibular plane angle, and a deficient bony chin (1), although the mandible could not be classified as retrognathic (5). Patients demonstrated a high prevalence of Class II and III occlusions, open and deep bites, and anterior cross-bites. Folding and thickening of the buccal mucous membranes, and prominent accessory labial frenula are observed. The soft tissue analysis indicated that the lips exceeded the line of harmony (Holdaway angle) and thus caused a disharmonious extra-oral appearance (6). Hypoplasia of teeth, including bud-shaped maxillary primary second molars and mandibular permanent first molars, have been reported. Findings also included microdontia (95%), small roots,

malocclusion (85%), delayed mineralization, and absence of some teeth, as well as invagination of the incisors (7). Macroglossia with signs of *lingua plicata* could be combined with a severe tongue thrusting in 67.7% of cases, while more than 50% of the patients had excessive interdental spacing (8).

The diagnosis of WBS is usually made during mid-childhood when the characteristic facial features, cognitive profile, cardiac findings become more apparent and are supported by the fluorescent in situ hybridization test to demonstrate the characteristic submicroscopic deletion on the long arm of chromosome 7. This last laboratory technique is particularly helpful, since there is a variable expression of the WBS features, which makes clinical diagnosis particularly difficult during the early years of life (9).

Due to these facial dysmorphologies, early determination of treatment objectives and the timing of interdisciplinary strategies are important for adequate management of WBS. A delay in diagnosing WBS can influence morbidity and prognosis. At each period, evaluation comprises a growth and developmental estimation using WBS growth charts, cardiac evaluation, feeding habits, and laboratory examinations (3). Given optimal medical, educational, and community support, the quality of life of affected individuals can be improved (10, 11).

As no general agreement is reached on treatment protocol, a case of WBS treated with bimaxillary osteotomies and glossectomy is analyzed with special attention to the treatment modalities and the discussion of the pertinent literature.

CASE REPORT

A 21 years old woman was admitted at Maxillofacial Surgery, Galeazzi Hospital, Milan, Italy in December 2003. She had no previous history of congenital malformations. She presented with difficulties in eating, some mild speech problems and impairment of psychomotor development. In the craniofacial complex we found thick eyebrows, bitemporal narrowing, periorbital sinking, short nose, wide nasal tip, malar hypoplasia, large philtrum, thick lips and prominent ear lobes (Fig. 1, 2). She had a skeletal III Class (Fig. 3), diastema of the incisors (Fig 4), severe periodontal disease, inclusion of the right central upper incisor and absence of the lower left second molar (Fig 5). She also had macroglossia.

The patient had deficit of cardiac electric conduction but no morphological defects. No additional anomalies were detected.

The final diagnosis of WBS was established, based on

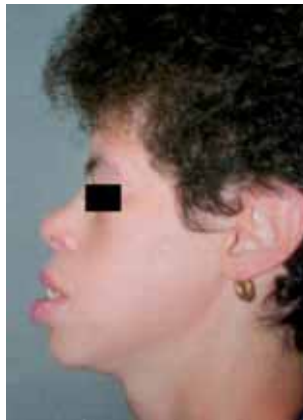
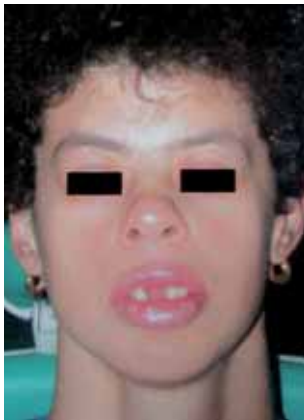
Fig. 1, 2 Patient's frontal and lateral views.

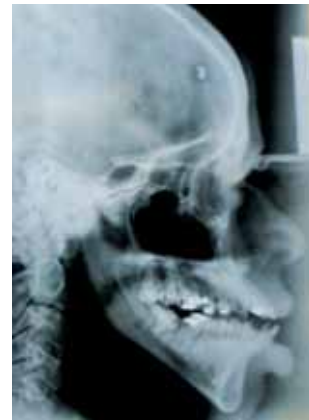

Fig. 3 Pre-treatment teleroadiography.

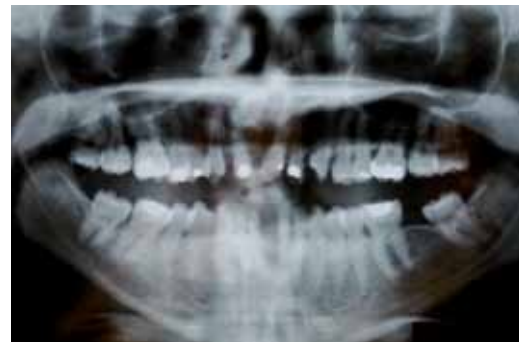
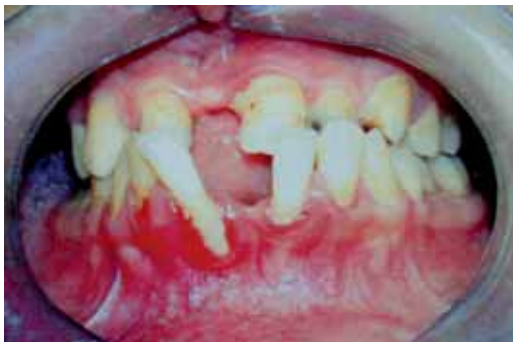
Fig. 4 The severe periodontal disease and the spaces between both upper and lower central incisors. Fig. 5 Pre-treatment orthopantomogram.

the clinical features described above and supported by the fluorescent *in situ* hybridization test.

Pre-surgical orthodontic treatment

Pre-surgical orthodontic treatment was carried out with a straightwire edgewise technique using a 0.018-inch high-torque system.

Dentoalveolar decompensation and harmonization of the upper and lower arches were the main treatment objectives. We maintained a space in the mandible midline as a sagittal osteotomy was planned to reduce the transverse dimension of the mandible. Standard 0.016 x 0.022-inch steel arches were used for stabilization during and after surgery. A stereolithographic model was performed in order to have a detailed model for surgical planning (Fig. 6).

Surgery

Orthognathic surgery was undertaken one year after. The maxilla was advanced at a Le Fort I of about 4 mm. The maxilla was fixed with two angled plates applied laterally to the pyriform aperture, one on each side. The lateral part of the maxilla was stabilized with wires. In addition, bilateral mandibular sagittal osteotomies were carried out together with a midline osteotomy (Fig. 7,d 8) and a partial glossectomy was performed (Fig. 9). Intermaxillary adaptation was supported by

applying soft elastics according to the concept of semi-rigid bone-fixation. Two-months post-surgery, the occlusion was Angle Class I with a well defined overbite and overjet.

Outcome

The healing was uneventful. Functional limitations or nerve disturbances did not occur. The miniplates remained *in situ*.

DISCUSSION

The syndromal, skeletal, and dental malformations with the additional tongue dysfunction and macroglossia in WBS patients require individualized and complex treatment planning (6).

The following surgical interventions were taken into considerations: a partial glossectomy, an advancement of the maxilla at a Le Fort I level and the bilateral mandibular sagittal osteotomies with a midline osteotomy. An enlarged tongue (macroglossia) can cause dentomusculoskeletal deformities, instability of orthodontic and orthognathic surgical treatment, and create masticatory, speech, and airway management problems. Understanding the signs and symptoms of macroglossia will help identifying those patients who could bene-

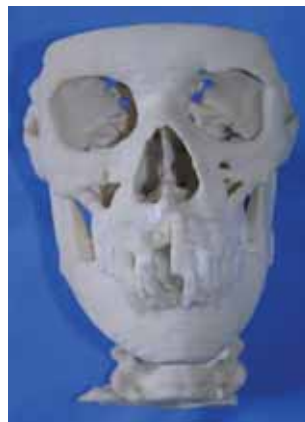

Fig. 6 Stereolithography.

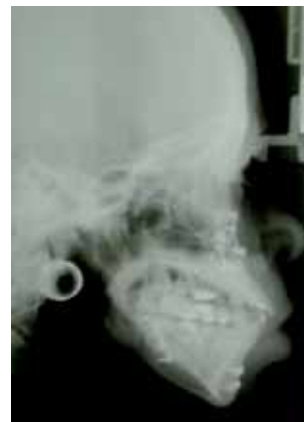

Fig. 7 Final teleroadiograph.

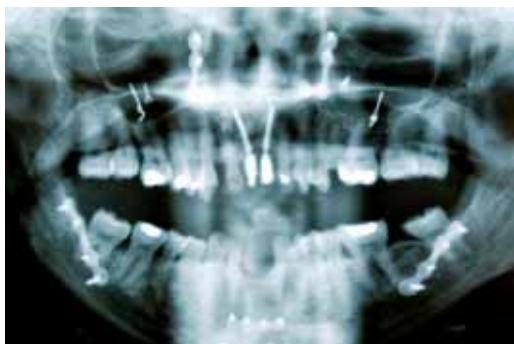


Fig. 8 Final orthopantomograph.

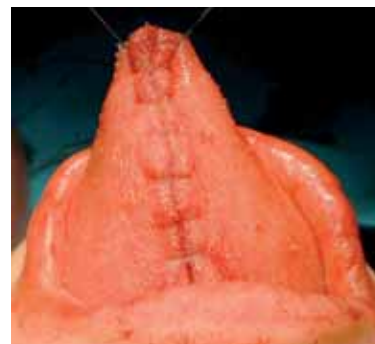


Fig. 9 The "keyhole" partial glossectomy.

fit from a glossectomy (reduction of tongue size) to improve function, aesthetics, and treatment stability (12).

Several articles have appeared describing various methods for reducing the tongue size, including the midline wedge resection with the base in the anterior tongue, the midline elliptical excision, the marginal excision, and the "keyhole" or midline elliptical excision combined with an anterior wedge resection, have all been described (13).

The option of performing the reduction glossectomy first, as an isolated procedure, and secondly the orthognathic surgery has the absolute indication when extensive orthodontics are necessary before orthognathic surgery, and the size of the tongue prevents the required orthodontic movements. Instead, in performing the orthognathic surgery and glossectomy in one surgical stage, it is usually helpful to complete the orthognathic surgery first. Once the orthognathic surgery is rigidly stabilized, a glossectomy can then be performed. Since a glossectomy generally causes a transient but significant increase in the size of the tongue, secondary to edema, performing the tongue procedure last may allow the occlusion to be better established before the onset of edema. However, if the tongue is extremely large, the reduction glossectomy may need to be sequenced first, to allow the proper occlusion to be established when the orthognathic surgery is performed (12).

Harvold (14) demonstrated that reducing the tongue to a size much smaller than normal causes the dental arches to collapse lingually. There are potential risks and complications that can occur in reduction glossectomy including excessive bleeding, airway obstruction secondary to tongue edema, anesthesia of the tongue and loss of taste. These can develop secondary to lingual nerve injury, motor dysfunction secondary to hypoglossal nerve injury, decrease of tongue mobility secondary to scarring, salivary duct injury, and residual speech and masticatory problems (12).

In the case reported the "keyhole" partial glossectomy was performed in combination with the orthognathic surgery. No complication was recorded in the post-operative

period and the patient had a successful outcome.

REFERENCES

1. Axelsson S. Variability of the cranial and dental phenotype in Williams syndrome. *Swed Dent J Suppl* 2005;170:3-67.
2. Kaplan P, Wang PP, Francke U. Williams (Williams Beuren) syndrome: a distinct neurobehavioral disorder. *J Child Neurol* 2001;16:177-90.
3. American Academy of Pediatrics: Health care supervision for children with Williams syndrome. *Pediatrics* 2001;107:1192-204.
4. Lashkari A, Smith AK, Graham JM Jr. Williams-Beuren syndrome: an update and review for the primary physician. *Clin Pediatr (Phila)* 1999;38:189-208.
5. Mass E, Belostoky L. Craniofacial morphology of children with Williams syndrome. *Cleft-Palate Craniofac J* 1993;30:343-9.
6. Habersack K, Grimaldi B, Paulus GW. Orthodontic orthognathic surgical treatment of a subject with Williams Beuren syndrome a follow-up from 8 to 25 years of age. *Eur J Orthod* 2007;29(4):332-7.
7. Oncag A, Gunbay S, Parlar A. Williams Syndrome. *J Clin Ped Dent* 1995;19:301-4.
8. Herzberg J, Nakisbendi LA, Needleman HL, Pober B. Williams syndrome: oral presentation of 45 cases. *Pediatr Dent* 1994;16: 262-7.
9. Lowery MC, Morris CA, Ewart A, Brothman LJ, Zhu XL, Leonard CO, Carey JC, Keating M, Brothman AR. Strong correlation of elastin deletions, detected by FISH, with Williams syndrome: evaluation of 235 patients. *Am J Hum Genet* 1995;57:49-53.
10. Huang L, Sadler L, O'Riordan MA, Robin NH. Delay in diagnosis of Williams syndrome. *Clin Pediatr* 2002;41:257-61.
11. Kaplan P. Williams syndrome—does early diagnosis matter? *Clin Pediatr* 2002;41:277-8.
12. Wolford LM, Cottrell DA. Diagnosis of macroglossia and indications for reduction glossectomy. *Am J Orthod Dentofacial Orthop* 1996;110:170-7.
13. Egerton M. The management of macroglossia when associated with prognathism. *Br J Plast Surg* 1960;3:117-22.
14. Harvold EP. The role of function in the etiology and treatment of malocclusion. *Am J Orthod* 1968;54:883-98.