

> **CELSO EDUARDO SAKAKURA, DDS, MSC, PHD², BEATRIZ MARIA VALÉRIO LOPES, DDS, MSC, PHD¹, ROGÉRIO MARGONAR DDS, MSC, PHD³, THALLITA PEREIRA QUEIROZ, DDS, MSC, PHD⁴, FRANCISCO HUMBERTO NOCITI JÚNIOR, DDS, MSC, PHD⁵, ELCIO MARCANTONIO JÚNIOR, DDS, MS, PHD¹**

¹ Department of Periodontology, Araraquara Dental School, São Paulo State University (UNESP) Araraquara, São Paulo, Brazil

² Department of Periodontology, Barretos Dental School, Education Foundation of Barretos, FEB, Barretos, SP, Brazil

³ Department of Health Sciences, Disciplines of Periodontology, Integrated Clinic, and Implantology Post Graduation Course, Dental School, University Center of Araraquara, UNIARA, Araraquara, São Paulo, Brazil

⁴ Department of Health Sciences, Disciplines of Oral and Maxillofacial Surgery, Integrated Clinic and Implantology Post Graduation Course, Dental School, University Center of Araraquara, UNIARA, Araraquara, São Paulo, Brazil

⁵ Department of Prosthodontics and Periodontics, Division of Periodontics, Piracicaba Dental School, UNICAMP, São Paulo, Brazil

Cyclosporine-a and bone density around titanium implants: a histometric study in rabbits

ABSTRACT

Aim Cyclosporine A (CsA) is an immunosuppressive agent commonly used to prevent organ transplantation rejection. It has been demonstrated that CsA may negatively affect osseointegration around dental implants. Therefore, the aim of this study was to evaluate the effect of CsA administration on bone density around titanium dental implants.

Materials and Methods Fourteen New Zealand rabbits were randomly divided into 2 groups with seven animals each. The test group (CsA) received daily subcutaneous injection of CsA (10mg/kg body weight) and the control group (CTL) received saline solution by the same route of administration. Three days after the beginning of immunosuppressive therapy, one machined dental implant (7.00 mm in length and 3.75 mm in diameter) was inserted bilaterally at the region of the tibial metaphysis. After 4 and 8 weeks the animals were sacrificed and the histometrical procedures were performed to analyse the bone density around the first four threads of the coronal part of the implant.

Results A significant increase in the bone density was observed from the 4- to the 8 week-period in the control group (37.41% + 14.85 versus 58.23% + 16.38 – p < 0.01). In contrast, bone density consistently decreased in the test group overtime (46.31% + 17.38 versus 16.28 + 5.08 – p < 0.05). In the 8-week period, there was a significant difference in bone density between the control and the test groups (58.23 + 16.38 eand 16.28 + 5.08 – p= 0.001).

Conclusion Within the limits of this study, long-term CsA administration may reduce bone density around titanium dental implants during the osseointegration process.

KEY WORDS Bone Density; Cyclosporine; Dental Implants.

INTRODUCTION

The principle of osseointegration is based on intimate bone-implant contact and the bone volume and quality are fundamental factors to achieve osseointegration during the healing and maintained along the years under load conditions (1).

Systemic diseases such as diabetes mellitus (2,3) and osteoporosis (4, 5, 6), radiotherapy (6), smoking habits (7) and some drugs therapy (8, 9) can induce alterations on bone metabolism leading to a poor bone quality and impairing the healing of bone tissue. Cyclosporine A (CsA) is an immunosuppressive agent commonly used to prevent organ transplantation rejection and treat other immunologic diseases (10). CsA acts on immune system inducing T-helper lymphocytes suppression. This mechanism may affect bone tissue, since immune system, particularly T-lymphocytes, play a critical role on bone remodeling (11-14). Some animal studies have demonstrated that this drug leads to a high bone turnover, resulting in unbalance of resorption and formation, leading to osteopenia (11-13). Studies in transplanted patients receiving CsA therapy showed high incidence of osteoporosis confirming this deleterious effect on bone metabolism in human (15-17).

The influence of CsA in osseointegration has been studied by Duarte et al. (2001) (8) and Sakakura et al. (2003) (9) and it has been shown that CsA may negatively affect osseointegration, reducing the bone-to-implant contact and bone formation around dental implants. On the other hand, there are no studies reporting the influence of CsA on the preexisting bone density, which may be considered an important indicator of the quality of bone tissue formed around dental implants. Therefore, the aim of

this study was to evaluate the influence of CsA administration on bone density around titanium dental implants.

MATERIALS AND METHODS

Animals

Fourteen New Zealand white rabbits, 9 to 12 months old (3500–4500 g), were used in the study. The animals were housed in individual cages, fed by a standard laboratory diet and given tap water ad libitum. The experiment was approved by the Institutional Experimentation Committee of the Araraquara Dental School, São Paulo, Brazil.

Experimental protocol

After a 2-week acclimatization period, the animals were randomly divided into two groups, test (CsA) and control (CTL) groups, with seven animals each. CsA was daily administered by a subcutaneous (10 mg/kg bodyweight), whereas the same route was used to administer saline solution (NaCl 0.9%) to the CTL group. The administration of the drugs began three days before the implants placement and lasted for 4 and 8 weeks postoperatively.

Implant surgery

The animals were anesthetized by intramuscular injections of a combination of ketamine (Francotar®; Virbac do Brasil Ltda, Brazil) (0.35 mg/kg bodyweight) and xylazine (Rumpum® Bayer S.A. São Paulo, Brazil) (0.5mg/kg bodyweight). The region of the tibial metaphysis was cleansed with iodine surgical soap. Incisions of approximately 3 cm in length were performed bilaterally at the internal side of the hind-leg, just below the knee. After gentle dissection, the bone surface of the tibial metaphysis was exposed. Unicortical implant beds were prepared by using a progressive sequence of spiral drills under generous saline cooling.

One machine surface titanium implants, (7 mm length and 3.75 mm in diameter), was placed in each leg (Fig. 1). The soft tissues were sutured in separate layers and the animals received a single intramuscular injection of antibiotic (Pentabiótico®, Wyeth-Whitehall Ltda, São Paulo, Brazil) (0.1 ml/kg bodyweight of an association of Penicillin with Streptomycin) postoperatively.

Histometric procedure

After 4 and 8 weeks, the animals were sacrificed and the histometrical procedures were performed to obtain the bone density around the first four threads apical to the implant platform, according to methods published by Feitosa et al. 2008 (18) and Correa et al. 2010 (19).

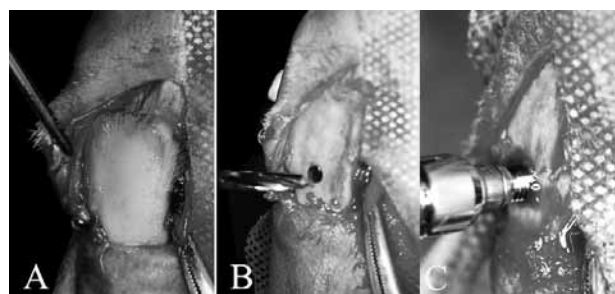
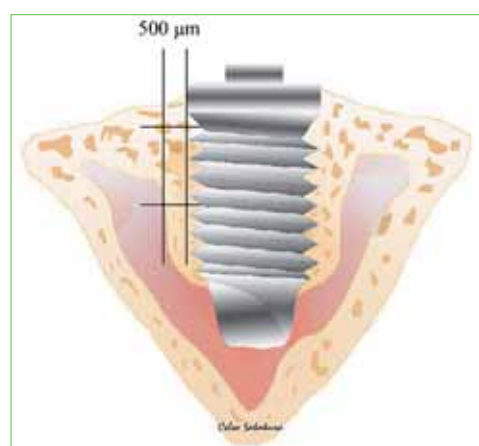


Fig. 1 Machined surface titanium implant placed in each tibial metaphysis. A. Receptor site; B. Preparation of receptor site; C. Implant placement.

Fig. 2 Schematic illustration demonstrating the region of bone density analysis.



The conventional implants with surrounding tissue in each tibia were removed and fixed in 4% neutral formalin for 48 hours. Non decalcified sections were prepared by a technique previously described by Donath and Breuner (1992) (20) Subsequently, the sections were stained as follows:

- > the slide-containing specimen was placed in a vessel containing Stevenel's blue preheated to, and maintained at, 60 °C for 15 minutes;
- > the specimen was rinsed in distilled water at 60 °C and air dried;
- > a small amount of alizarin red was placed onto the specimen surface at room temperature for 5 minutes.

Then, it was washed thoroughly in running distilled water to remove excess stain and air dried.

The bone density (i.e, proportion of mineralized bone in a 500 µm-wide zone lateral to the implant and not inside the threads) was measured at both sides of the implant, at the first four threads (Fig. 2). The analysis was performed by a single examiner, trained and calibrated. Therefore, this area lateral to the implant was enclosed by a rectangle whose total area corresponded to 100%.

Then, the area of bone fill within the rectangle was calculated and the percentage value was obtained by simple rule of three. The mean of data obtained for both sides of the implant was considered for statistical analysis.

Statistical analysis

Since data were normally distributed, as demonstrated by Kolmogorov and Smirnov test, unpaired t test was used to access difference in bone density between the groups in each experimental period (4-week and 8-week period). Paired t test was used to compare differences in bone density between the 4-week and the 8-week period in each experimental group separately. P value was set at 0.05.

RESULTS

Table 1 shows the mean and standard deviation of each group at different periods of analysis. A statistically significant increase in bone density between the 4 and 8-week period was observed for the control group (37.41% + 14.85 versus 58.23% + 16.38 – p < 0.01). In contrast, bone density consistently decreased in the test group overtime (46.31% + 17.38 versus 16.28 + 5.08 – p < 0.05) (Fig. 3). In the 8-week period, there was a statistically significant difference in bone density between the control and the test group (58.23 + 16.38 versus

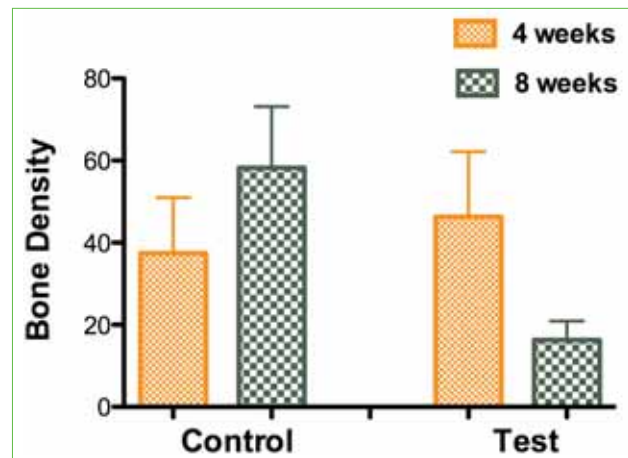
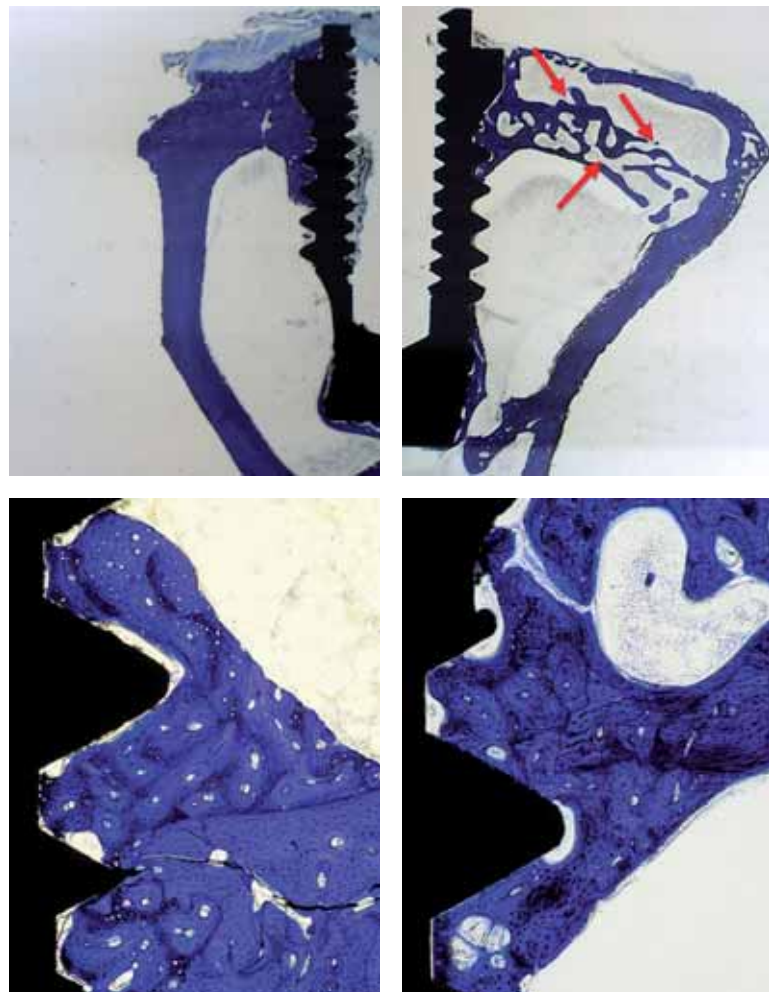


Fig. 3 Mean (%) and standard deviation for bone density around implants for control and test groups at 4 and 8 weeks post-surgery.

16.28 + 5.08 – p= 0.001) (Fig. 4 A, B, C and D). No statistically significant difference could be found between test and control groups in the 4-week period (46.31% + 17.38 versus 37.41% + 14.85).

Fig. 4 Non-decalcified histological sections (Stevenel's blue and alizarin red). General aspect of bone from control (A, C) and CSA (B, D) groups at 8 weeks: the CSA specimen shows lower density and more spaces in cortical bone than control group (arrows) (C and D 100X magnification).



PERIODS	CONTROL	TEST
4 weeks	33,11	73,06
	50,94	60,74
	33,77	28,96
	57,88	37,25
	32,46	32,05
	16,30	45,81
	37,41	46,31
Mean Standard Deviation	37,41 13,56	46,31 15,86
8 weeks	60,60	24,16
	78,01	19,83
	52,55	15,57
	76,14	10,22
	40,16	12,16
	41,95	15,76
	58,24	16,28
Mean Standard Deviation	58,23 14,95	16,28 4,64

Table 1 Bone density values from each animal, and mean and standard deviation from both groups and periods.

DISCUSSION AND CONCLUSION

The increasing of bone density around dental implants along the time may occur due to the bone remodeling processes (Davies et al., 2003) (21). In our study, it was also found a statistically significant increase in bone density from the 4-week to the 8-week period in the control group (37.41% + 14.85 versus 58.23% + 16.38 – $p < 0.01$).

However, in the CsA group, a statistically significant decrease in bone density was observed around the implants from the 4-week to the 8-week period (46.31% + 17.38 and 16.28 + 5.08 – $p < 0.05$). This suggests that CsA administration during 8-week period may have negatively affected the bone mineralization around dental implant. The possible reasons for explain these results are related with the mechanism of immunosuppression caused by CsA. It is known that the immune system actively participates in bone mineral metabolism (13, 14, 17) and that the T lymphocytes play a critical role in the development of CsA-induced osteopenia (22). This is not surprising as the T cell is the traditional target of CsA, and naturally occurring T lymphocyte perturbations are implicated in the development of primary osteoporosis in humans (8). Besides, an *in vitro* study (23) corroborates with this result, by describing the necessity of thymus-derived lymphocytes presence for the production of the osteoclast-activating factor.

The lymphocytes suppression results in a high bone metabolism state, where the bone formation is supplanted by the bone resorption, leading to a decrease in the trabecular bone volume (12, 13, 15, 16). Under these conditions, a decrease in bone density around dental implant was observed despite of the osteoinduction proprieties of titanium oxide on the implant surface. The precise mechanism of action of CsA on bone tissue is still not well understood. It is known that these bone alterations correlate with immunosuppressive mechanisms and are mediated by cytokines (14, 22). Moreover, possible CsA effects on osteoblasts and osteoclasts should not be disregarded, which may result in a secondary phenomenon, leading to a high bone remodeling state with exceeding bone resorption (14). The side effects of CsA on bone tissue seem to be time and dose-dependent. Higher doses and long time administration lead to severe alterations in bone metabolism (13).

The percentage of bone tissue formed at the first four threads was used to access bone density due to the close proximity to the cortical bone of the tibial metaphysis. Despite the fact that CsA exerts its effect mainly on trabecular bone, bone density was dramatically reduced in the cortical bone, as demonstrated in this study. This suggests that in

areas where trabecular bone predominates, such as in the maxilla, bone density around dental implants may be severely damaged. Fu et al. (1999) (28) found an increased alveolar bone resorption in rats receiving CsA, with greater bone loss in sites affected by periodontitis.

Although it could be demonstrated a negative side effect of CsA on cortical bone healing around dental implants, further studies should be developed in order to investigate the effects of this drug on trabecular bone and around osseointegrated functionally loaded dental implants. Within the limits of this study, long-term CsA immunosuppression may reduce bone density around titanium dental implants during the osseointegration process.

REFERENCES

1. Albrektsson T. Bone tissue response. In: Brånemark P-I, Zarb G, Albrektsson T, eds. *Tissue integrated prosthesis osseointegration in clinical dentistry*. Chicago: Quintessence, 1985: 129-144.
2. Margonar R, Sakakura CE, Holzhausen M, Pepato MT, Alba Jr RC, Marcantonio Jr E. *The Influence of Diabetes Mellitus and Insulin Therapy on Biomechanical Retention Around Dental Implants: A Study in Rabbits*. *Implant Dent* (in press)
3. Takeshita F, Murai K, Iyama S, et al. Uncontrolled diabetes hinders bone formation around titanium implants in rat tibiae. A light and fluorescence microscopy, and image processing study. *J Periodontol*. 1998;69:314-320.
4. Dao TT, Anderson JD, Zarb GA. Is osteoporosis a risk factor for osseointegration of dental implants? *Int J Oral Maxillofac Implants*. 1993; 8: 137-144.
5. Duarte PM, Cesar-Neto JB, Sallum AW, Sallum EA, Nociti FH Jr. Effect of estrogen and calcitonin therapies on bone density in a lateral area adjacent to implants placed in the tibiae of ovariectomized rats. *J Periodontol*. 2003;74(11):1618-24.
6. Granström G. Radiotherapy, osseointegration and hyperbaric oxygen therapy. *Periodontol 2000* 2003; 33: 145-162.
7. Cesar-Neto JB, Duarte PM, Sallum EA, Barbieri D, Moreno H Jr, Nociti FH Jr. A comparative study on the effect of nicotine administration and cigarette smoke inhalation on bone healing around titanium implants. *J Periodontol*. 2003 Oct;74(10):1454-9.
8. Duarte PM, Nogueira Filho GR, Sallum EA, Sallum AW, Nociti Junior FH. The effect of an immunosuppressive therapy and its withdrawal on bone healing around titanium implants. A histometric study in rabbits. *J Periodontol* 2001; 72:1391-7.
9. Sakakura CE, Margonar R, Holzhausen M, Nociti Jr FH, Alba Jr RC, Marcantonio Jr E. influence of cyclosporin a therapy on bone healing around titanium implants. A histometric and biomechanic study in rabbits. *J Periodontol*. 2003; 74: 974-979.
10. Ruegger A, Kuhn M, Lichti H, et al. Cyclosporin A, a Peptide Metabolite from *Trichoderma polysporum* (Link ex

- Pers.) Rifai, with a remarkable immunosuppressive activity *Helv Chim Acta*. 1976; 59:1075-92.
11. Mccauley LK, Rosol TJ, Capen CC. Effects of cyclosporin A on rat osteoblasts (ROS 17/2.8 Cells) in vitro. *Calcif Tissue Int* 1992; 51: 291-297.
 12. Movsowitz C, Epstein S, Ismail F, Fallon M, Thomas S. Cyclosporin A in the oophorectomized rat: unexpected severe bone resorption. *J Bone Miner Res* 1989; 4: 393-398.
 13. Movsowitz C, Epstein S, Fallon M, Ismail F, Thomas S. Cyclosporin-A in vivo procedures severe osteopenia in the rat: effect of dose and duration of administration. *Endocrinol* 1988; 123: 2571-2577.
 14. Rucinski B, Liu CC, Epstein S. Utilization of cyclosporine H to elucidate the possible mechanisms of cyclosporine A-induced osteopenia in the rat. *Metabolism* 1994; 43:1114-18.
 15. Cayco A, Wysolmerski J, Simpson C, et al. Posttransplant bone disease: evidence for a high bone resorption state. *Transplantation* 2000; 70: 1722-1728.
 16. Julian BA, Laskow DA, Dubovsky J, Dubovsky EV, Curtis JJ, Quarles LD. Rapid loss of vertebral mineral density after renal transplantation. *N Engl J Med* 1991; 325: 544-50.
 17. Vedi S, Greer S, Skingle SJ, et al. Mechanism of bone loss after liver transplantation: a histomorphometric analysis. *J Bone Miner Res* 1999; 14: 281-287.
 18. Feitosa D da S, Bezerra B de B, Ambrosano GM, Nociti FH, Casati MZ, Sallum EA, de Toledo S. Thyroid hormones may influence cortical bone healing around titanium implants: a histometric study in rats. *J Periodontol* 2008; 79:881-7.
 19. Correa MG, Gomes Campos ML, César-Neto JB, Casati MZ, Nociti FH, Sallum EA. Histometric evaluation of bone around titanium implants with different surface treatments in rats exposed to cigarette smoke inhalation. *Clin Oral Implants Res* 2009; 20: 588-93.
 20. Donath K, Breuner G. A method for study of undecalcified bones and teeth with attached soft tissue. The sage-Scliff (sawing and grinding) technique. *J Oral Pathol* 1982; 11: 318-326.
 21. Davies, JE. Understanding peri-implant endosseous healing. *J Dent Edu*. 2003; 67 (8): 932-949
 22. Buchinsky FJ, Ma Y, Mann GN, et al. T lymphocytes play a critical role in the development of cyclosporin A-induced osteopenia. *Endocrinol* 1996;137:2278-2285.
 23. Horowitz M, Vignery A, Gershon RK, Baron R. Thymus-derived lymphocytes and their interaction with macrophages are required for production of osteoclast-acting factor in mouse. *Proc Natl Acad Sci USA* 1984; 81: 2181-2185.
 24. Grizon F, Aguado E, Huré G, Baslé MF, Chappard D. Enhanced bone integration of implants with increased surface roughness: a long term study in the sheep. *J Dent* 2002; 30: 195-203.
 25. Albrektsson T, Wennerberg A. Oral implant surfaces: Part 1 – review focusing on topographic and chemical properties of different surfaces and in vivo responses to them. *Int J Prosthodont* 2004; 17: 536-43.
 26. Schneider GB, Zaharias R, Seabold D, Keller J, Stanford C. Differentiation of preosteoblasts in affected by implant surface microtopographies. *J Biomed Mater Res A* 2004; 69: 462-8.
 27. Shane E, Rodino MA, McMahon DJ, et al. Prevention of bone loss after heart transplantation with antiresorptive therapy: a pilot study. *J Heart Lung Transplant* 1998; 17: 1089-1096.
 28. Fu E, Hsieh Y-D, Nieh S, Wikesjö, Liu D. Effects of cyclosporin A on alveolar bone: an experimental study in the rat. *J Periodontol* 1999; 70:189-194.