

Digital planning of a customized CAD-CAM healing abutment for soft tissue conditioning at the time of implant placement: A different digital and clinical perspective in molar implant rehabilitation

> L. LEPIDI¹, M. GALLI², C. SURIANO³, G. RUGGIERO⁴, L. CALABRESE⁶, J. LI², P. VENEZIA⁵

¹Freelance Researcher, StudioLepidi&Suriano, Andria, Italy

²Department of Periodontics and Oral Medicine, University of Michigan School of Dentistry, Ann Arbor, MI, USA

³Department of Clinical and Experimental Medicine, University of Foggia School of Dentistry, Foggia, Italy

⁴Department of Neurosciences, Reproductive and Odontostomatological Sciences, Division of Prosthodontics and Digital Dentistry, University "Federico II" of Naples, Naples, Italy

⁵Department of Prosthodontics, School of Dentistry, University of Catania, Catania, Italy

⁶Department di Biomedicina e Prevenzione, University of Rome "Tor Vergata", Rome, Italy

TO CITE THIS ARTICLE

Lepidi L, Galli M, Suriano C, Ruggiero G, Calabrese L, Li J, Venezia P. Digital planning of a customized CAD-CAM healing abutment for soft tissue conditioning at the time of implant placement: A different digital and clinical perspective in molar implant rehabilitation. *J Osseointegr J Osseointegr* 2021;13(4):S305-S310.

DOI 10.23805/JO.2021.13.S04.9

KEYWORDS Intraoral scanner; Cone Beam Computed Tomography; Guided implant surgery; Customized CAD-CAM healing abutment; Soft tissue conditioning.

ABSTRACT

Aims Achieving ideal peri-implant soft tissue contour is essential for a predictable restorative success. After tooth extraction, even in case of ridge preservation, a volume deficiency could be still observed at the time of implant planning. The aim of this clinical report was to present a new digital and clinical workflow in molar implant rehabilitations.

Clinical considerations A new workflow is described for planning and fabricating a customized healing abutment for conditioning peri-implant soft tissues at the same time of implant placement and also help digital impression-taking for the desired prosthetic emergence profile, with a time saving for both patient and dentist.

Conclusion A customized healing abutment helps digital impression-taking and prepares the soft tissue to the prosthetic finalization with further individual compensation simulating the root area in order to achieve the best possible definitive emergence profile.

understood, for this reason this topic has interesting clinical implications. Soft tissue contour preservation around implant-supported crowns is a key factor in attaining esthetic and anatomic results (5). While in a single-unit implant restoration the immediate loading and provisionalization in the front area could be achieved during biologic osseointegration with a good management of soft tissue, in the posterior area, this workflow is not recommended because of the increased risk of implant failure (6). The use of standardized healing abutments does not allow to reproduce an anatomic emergence profile and further steps are necessary when seating a temporary fixed restoration on implants, with subsequent increased clinical visits and biologic risks for the stability of peri-implant tissue (7). Repeated abutment change should be avoided, because this is associated with epithelial attachment damage which may compromise peri-implant seal, according to "one abutment/one time concept" (8). The use of a customized healing abutment may provide several advantages, including improving clinical and postoperative patient-reported outcomes (9). Current clinical decision-making in implant dentistry is increasingly focused on prosthetically guided implant therapy. Advances in digital dentistry and computer-aided design and computer-aided manufacturing (CAD-CAM) offer new options in the design of the emergence profile of restorations and allow the fabrication of customized restorations/healing abutment with the same shape during virtual waxing phase even before implant

INTRODUCTION

In the last few years, the benefits of customized healing abutments and provisional restoration of hard and soft tissues conditioning after implant placement have already been investigated (1-4). However, these digital methodologies are not so widespread in daily practice and maybe possible advantages are not completely

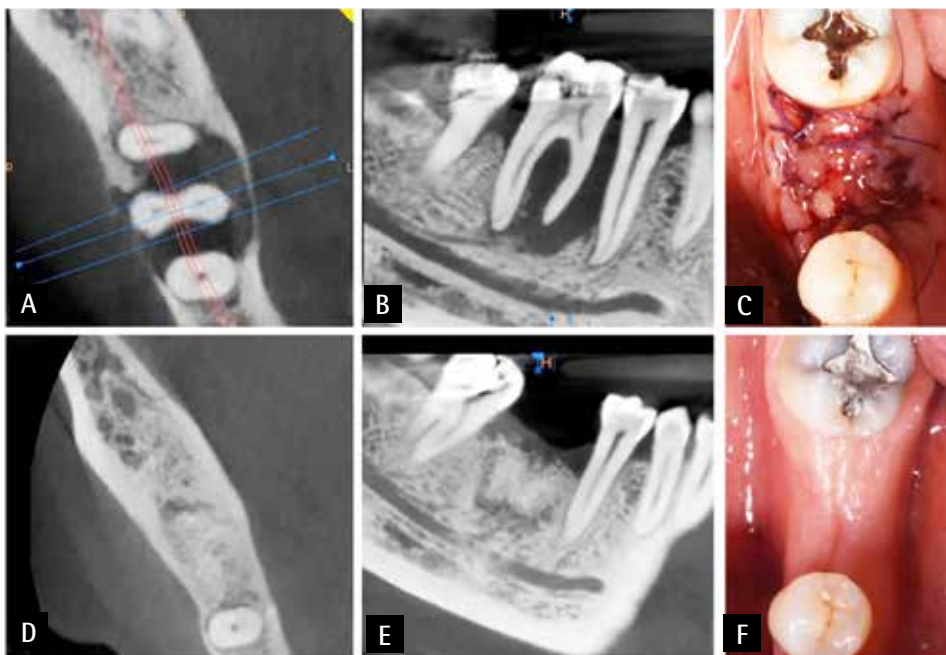


FIG. 1 Before and after alveolar ridge preservation, cone beam and clinical images: bone morphology prior to extraction and alveolar ridge preservation (A, B); intraoral view at the time of surgery (C); one year post-operative (D, E); intraoral view of the edentulous site after healing (F).

surgery. The most used CAD software allows to create a 3D virtual model by superimposing images from cone beam computed tomography (CBCT), intraoral scanners (IOS), as well as desktop scanners (DS), allowing clinicians to study soft tissue contours as well as also the underlying osseous morphology of the edentulous sites, highlighting and planning all three dimensional implant position in order to mimic the best emergence profile and thus designing a supra-implant tissue architecture as natural as possible (10). The aim of this clinical report was to present a digital workflow using CAD-CAM technology for planning and fabricating a customized healing abutment (CHA) within a guided surgery project in order to shape implant soft tissue at the same time of implant

placement, facilitate the digital impression-taking and prepare the soft tissues to receive the final restoration with the desired prosthetic emergence profile in a few visits, thus saving time for both patient and dentist.

CLINICAL REPORT

A 55-year old male patient, after the extraction of his lower right first molar, required implant restoration (Fig. 1). Since periodontal health is a critical factor in peri-implant stability, a radiographic and clinical examination including periodontal charting was conducted to assess the status of periodontal health of the adjacent

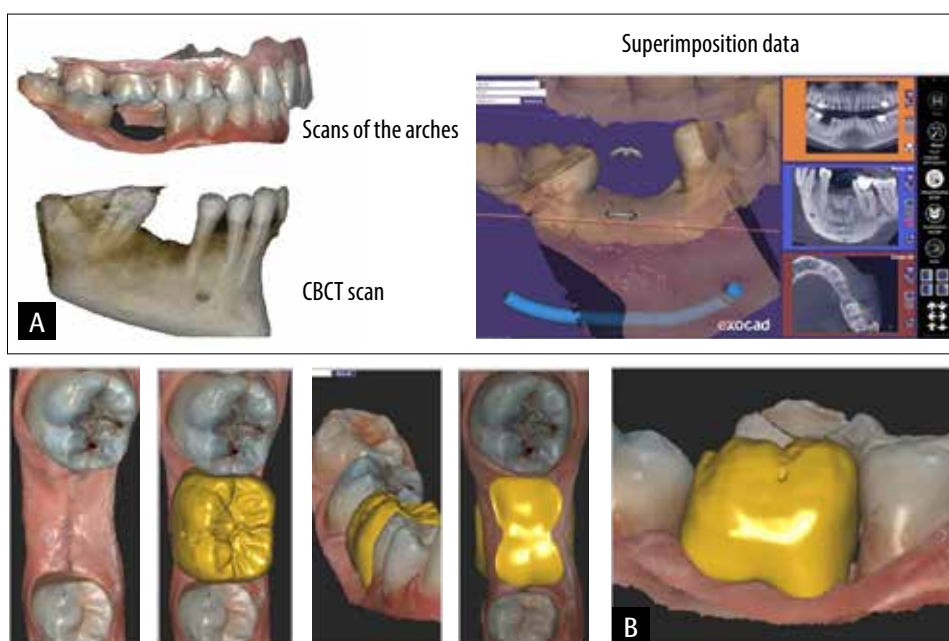


FIG. 2 First visit and CAD phase: superimposition of digital data acquired (A); design workflow of the virtual waxing of the prosthetic crown during treatment planning (B).



FIG. 3 CAD design and planning: implant placement using dental crown project (green) (A); virtual waxing of the customized healing abutment (yellow) (B); internal view of the customized healing abutment and waxing with prosthetic compensation (green) (C); sagittal view of the customized healing abutment (D).

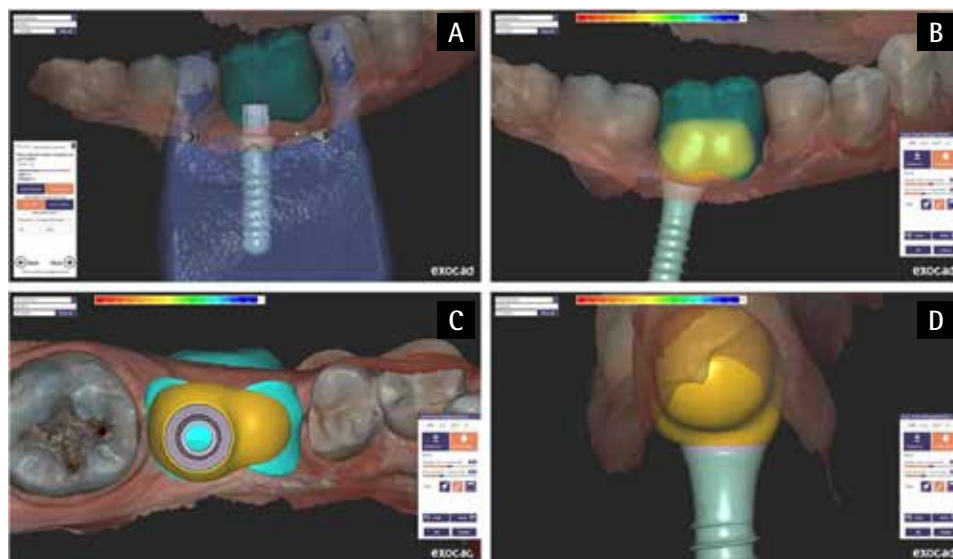
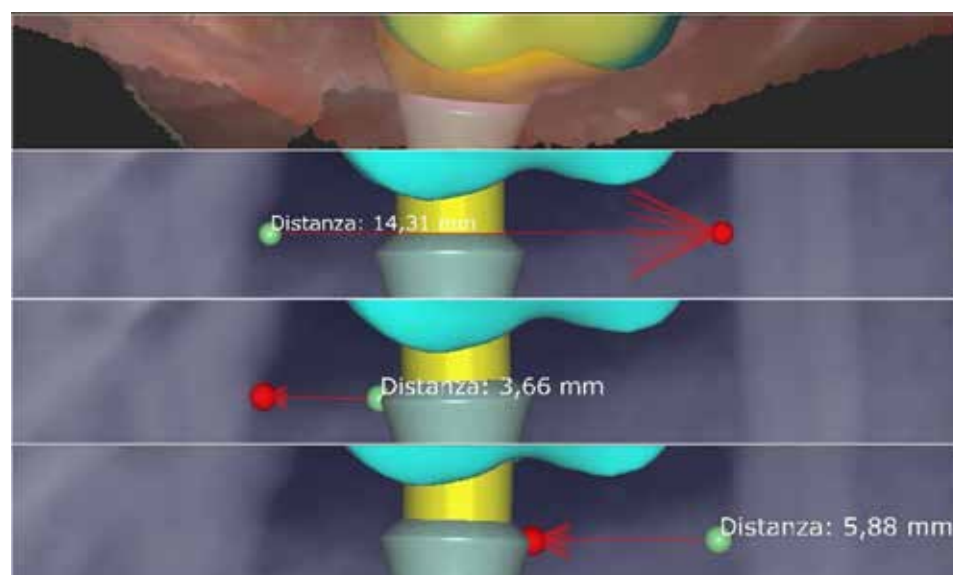


FIG. 4 Measurement of the distance between the implant and adjacent teeth.



teeth (11). Both intraoral (CS 3600; Carestream Health, Rochester, NY) and CBCT scans limited to the involved hemiarch were obtained (CS 81003D; Carestream Health, Rochester, NY).

The exam showed that, even with prior ridge preservation, a volume deficiency was still observed (Fig. 1). The mesio-distal distance between adjacent roots at the edentulous site was 14 mm combined with clinical attachment loss of the premolar and soft and hard tissue deficiency, which clinically defined the architecture of the edentulous site as *sui generis* (Fig. 1E,1F).

Virtual planning

A digital diagnostic impression was taken with an IOS (Cs 3600, Carestream Health, Rochester, NY) and a CBCT of the surgical field was acquired (Fig. 2A).

In order to prevent unsatisfactory tooth proportions, a bulky emergence profile, and limited access for hygiene, virtual planning and previsualization of the

final restoration were obtained (Fig. 2B). The dental CAD software (Exocad; exocad GmbH, Germany) allows simulation of different tooth morphologies, which helps the fabrication of a virtual waxing of the customized healing abutment, reproducing the root form of the lost tooth.

Diagnostic waxing with prosthetic compensation simulating the root area (WPC) was used to compensate for the ridge deficiency and offer the best restorative adaptation to soft tissue (Fig. 2B). It was also used for planning a prosthetically driven implant position and designing the CHA with an ovate pontic coping the shape of the virtual emergence profile roots of the final restoration (Fig. 3). A tooth-implant distance of about 3 mm from the adjacent molar, and about 6 mm from the adjacent premolar, was observed during digital positioning in the 3D-guided implant surgery planning software (Exoplan; exocad GmbH, Germany) (Fig. 4) (12). A 3-dimensional printer (Formlabs; Somerville, USA) was

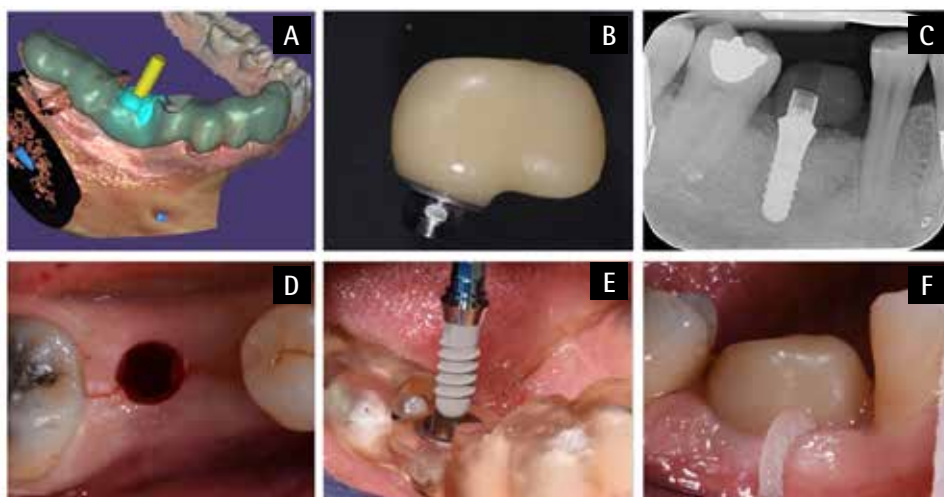


FIG. 5 Surgical procedure: surgical template project (A); milled customized healing abutment (B); Periapical radiography after with customized healing abutment fixed to the implant (C); intraoral view of the flapless approach (D); implant insertion through the surgical guide (E); intraoral view of the customized healing abutment fixed to the implant and access for hygiene (F).

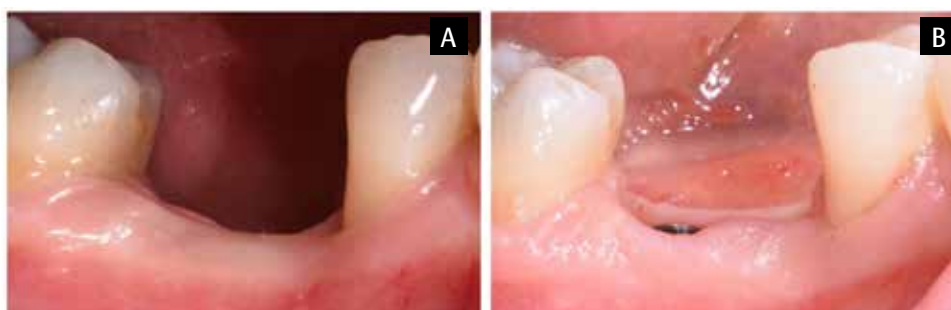

FIG. 6 Intraoral view of the soft tissue: before implant surgery procedure (A); upon removal of the customized healing abutment (B).

used to print the surgical guide template and cast using surgical guide resin and draft resin, respectively. The CHA was fabricated via milling using polyether ether ketone (PEEK) material (Bredent:BioHPPP, Senden, Germany).

Surgical procedure

The patient was instructed to use 0.2% chlorhexidine mouthwash twice a day (starting one day before implant surgery and for the following 10 days). Two grams of amoxicillin were prescribed 1 hour before surgery. Considering the presence of sufficient keratinized tissue, the surgery was performed using a flapless approach. Under local anesthesia with articaine and epinephrine (1:100,000), a soft tissue punch was performed. Following guided osteotomy preparation, a tissue level implant was placed (Fig. 5). The interface between the polished and rough surface was positioned at the level of the buccal crest.

A primary stability of 35 N/cm was achieved. Subsequently, a secondary t-base abutment (Variobase, 5.05 x 4 mm; Straumann, Switzerland) was tested on the head of the implant and afterwards bonded to a customized healing abutment outside of the oral cavity using vetroionomeric cement (GC Fuji I; GC Corporation, Japan). The CHA was inserted with 20 Ncm of torque, following a one stage surgical approach (Fig. 5 F).

Blanching of the tissues was observed clinically, demonstrating ischemia of the keratinized tissue

surrounding the implant. This indicated that the CHA had an active action in conditioning the peri-implant soft tissue according to the shape and profile planned during the CAD phase. Standardized periapical radiographs using a parallelization system with silicon bite-blocks were taken immediately post-surgery in order to assess the absence of misfit (Fig. 5 C).

Prosthetic phase and digital workflow

Ten weeks after implant placement, the soft tissue surrounding the CHA was stable and conditioned according to the WPC area, as planned with the CAD software (Fig. 6). During this visit, a direct digital impression was made using the workflow reported by Monaco et al. (13):

- 1) intraoral scanning of the CHA;
- 2) digital impression of the sulcus and peri-implant soft tissue immediately after removal of the CHA;
- 3) final impression with standardized scan body fixed to the implant to capture its position (Fig. 7) (13).

For all scans, the two adjacent teeth were captured to permit virtual superimposition. All the .STL files were exported to a virtual lab to facilitate superimposition in the CAD software. A virtual master model was fabricated where the morphology of the CHA, complete soft tissue contour (gingival sulcus and pontic area), and implant position were combined and merged. Lastly, the final restoration was designed, fabricated via a CAM process and delivered (Fig. 8).

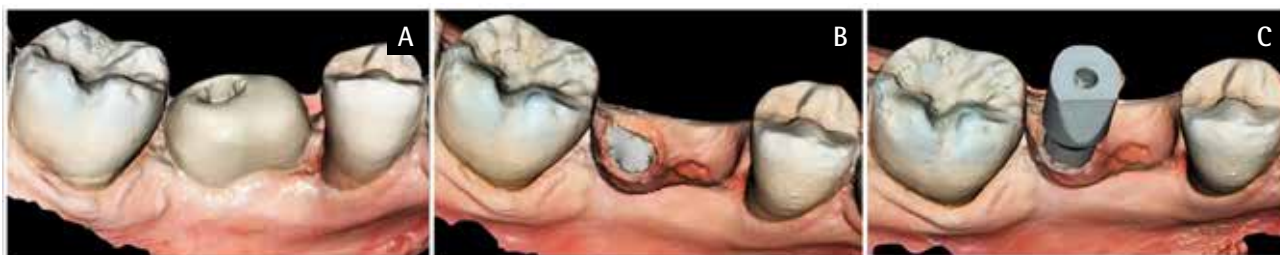

FIG. 7 Three ply files are sufficient to obtain all data needed to allow to design and fabrication of the definitive restoration: impression with customized healing abutment (A); impression of the peri-implant soft tissue contour upon removal of the customized healing abutment (B); impression with standardized scan body fixed on the implant (C).

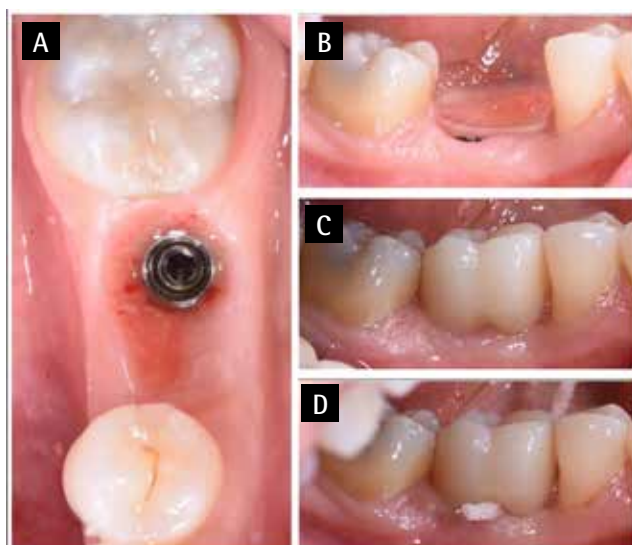


FIG. 8. Fourth visit: intraoral occlusal view of the soft tissue contour upon removal of the customized healing abutment (A, B); final prosthetic restoration and its design showing the sulcus and ovate pontic (C); after delivery: access for hygiene in the embrasure space (D).

DISCUSSION

The possibility to insert an implant in a central position is considered as the best option in clinical practice (14). For all those cases in which a different implant placement has to be evaluated based on anatomical factors, this clinical report could represent a useful guide. From the prosthetic and esthetic standpoints, the implant position in conjunction with an alternative prosthetic design, with a mesial pontic cantilever for both the CHA and final prosthesis, was chosen in the present case in order to obtain the best emergence profile possible, according to the condition the soft tissues, and to promote the best adaptation and papilla fill (15,16). For all the previous reasons this case should be considered as *sui generis*, even if all criteria validated were respected. In order to help understand the choice made, it is interesting to report, from a biologic perspective, that Tuna et al. in an *in vitro* study demonstrated better cleanability and access for hygiene utilizing this eccentric implant

positioning in conjunction with an alternative crown design (17). This alternative crown design, which was similar to the one used in the present study, provides access for hygiene interproximally through embrasure spaces. The application of a customized healing abutment has shown several advantages: it requires few visits, prepares the soft tissues for the final restoration, and facilitates impression-taking. Moreover, the results of this clinical report encourage future *in vivo* studies with long-term follow-up, in order to validate the alternative prosthetic design in comparison to central implant positioning. The main limit of this workflow could be the more expensive procedure for the clinician. The ovate pontic could represent an interesting and feasible solution for all those cases that require prosthetic ridge volume compensation. The main disadvantages could be the initial investment in terms of CAD software and higher costs associated with a CHA.

In view of the excellent results offered by the virtual environment, advances in digital dentistry could offer new clinical perspectives in all situations where anatomical features are not ideal but *sui generis* as in the present case.

CONCLUSIONS

In daily clinical practice, current digital methodologies allow the evaluation of many diagnostic variables for single-unit implant treatments, opening new clinical perspective. Peri-implant soft tissue conditioning using a CHA fixed on an implant and placed by guided surgery during the same appointment reduces the overall number of patient visits. A customized healing abutment facilitates digital impression-taking and prepares the soft tissue to prosthetic finalization with further individual compensation simulating the root area in order to achieve the best possible definitive emergence profile.

Acknowledgements

The authors would like to thank Domenico Faretra, SDT, Aldo Grammatica, DT (Corato, Italy), for their contributions to this manuscript.

Author contributions

Conceptualization, L.L. and C.S.; methodology, G.R. and L.L.; validation, L.L.; formal analysis, C.S.; investigation, G.R.; resources, G.R. and M.G.; data curation, C.S. and J.L.; writing—original draft preparation, P.V. and L.L.; writing—review and editing, P.V., L.C. and J.L.; visualization, P.V. and M.G.; supervision, L.L. and M.G.; project administration, L.L. and J.L. All authors have read and agreed to the published version of the manuscript.

Funding

This research received no external funding.

Conflicts of interest

The authors declare no conflict of interest. This research did not receive any specific grant from funding agencies in the public, commercial, or not-for-profit sectors.

REFERENCES

- Zimmermann M, Mehl A, Mörmann WH, Reich S. Intraoral scanning systems - a current overview. *Int J Comput Dent* 2015;18:101-29.
- Ruales-Carrera E, Pauletto P, Apaza-Bedoya K, Volpato CAM, Özcan M, Benfatti CAM. Peri-implant tissue management after immediate implant placement using a customized healing abutment. *J Esthet Restor Dent* 2019;31:533-541.
- Menchini-Fabris GB, Crespi R, Toti P, Crespi G, Rubino L, Covani U. A 3-year retrospective study of fresh socket implants: CAD/CAM customized healing abutment vs cover screws. *Int J Comput Dent* 2020;23:109-117.
- Finelle G, Popelut A, Knafo B, Martín IS. Sealing Socket Abutments (SSAs) in molar immediate implants with a digitalized cad/cam protocol: Soft tissue contour changes and radiographic outcomes after 2 years. *Int J Periodontics Restorative Dent* 2021;41:235-244.
- Perez A, Caiazza A, Valente NA, Toti P, Alfonsi F, Barone A. Standard vs customized healing abutments with simultaneous bone grafting for tissue changes around immediate implants. 1-year outcomes from a randomized clinical trial. *Clin Implant Dent Relat Res* 2020;22:42-53.
- Sanz-Sánchez I, Sanz-Martín I, Figuero E, Sanz M. Clinical efficacy of immediate implant loading protocols compared to conventional loading depending on the type of the restoration: a systematic review. *Clin Oral Implants Res* 2015;26:964-982.
- Atieh MA, Tawse-Smith A, Alsabeeha NHM, Ma S, Duncan WJ. The one abutment-one time protocol: A systematic review and meta-analysis. *J Periodontol* 2017;88:1173-1185.
- Beuer F, Groesser J, Schweiger J, Hey J, Güth JF, Stimmelmayer M. The digital one-abutment/one-time concept. A clinical report. *J Prosthodont* 2015;24:580-585.
- Tsoukaki M, Kalpidis CD, Sakellari D, Tsalikis L, Mikrogiorgis G, Konstantinidis A. Clinical, radiographic, microbiological, and immunological outcomes of flapped vs. flapless dental implants: a prospective randomized controlled clinical trial. *Clin Oral Implants Res* 2013;24:969-976.
- Joda T, Ferrari M, Braegger U. A digital approach for one-step formation of the supra-implant emergence profile with an individualized CAD/CAM healing abutment. *J Prosthodont Res* 2016;60:220-223.
- Schwarz F, Derks J, Monje A, Wang HL. Peri-implantitis. *J Clin Periodontol* 2018; 45 Suppl 20:S246-s266.
- Tarnow DP, Cho SC, Wallace SS. The effect of inter-implant distance on the height of inter-implant bone crest. *J Periodontol* 2000;71:546-549.
- Monaco C, Scheda L, Baldissara P, Zucchelli G. Implant digital impression in the esthetic area. *J Prosthodont* 2019;28:536-540.
- Su Cy, Fu J-H, Wang HL. The role of implant position on long-term success. *Clin Adv Periodontics* 2014;4:187-193.
- Gastaldo JF, Cury PR, Sendyk WR. Effect of the vertical and horizontal distances between adjacent implants and between a tooth and an implant on the incidence of interproximal papilla. *J Periodontol* 2004;75:1242-1246.
- Choquet V, Hermans M, Adriaenssens P, Daelemans P, Tarnow DP, Malevez C. Clinical and radiographic evaluation of the papilla level adjacent to single-tooth dental implants. A retrospective study in the maxillary anterior region. *J Periodontol* 2001;72:1364-1371.
- Tuna T, Kuhlmann L, Bishti S, Sirazitdinova E, Deserno T, Wolfart S. Removal of simulated biofilm at different implant crown designs with interproximal oral hygiene aids: An in vitro study. *Clin Oral Implants Res* 2019;30:627-636.