

Marginal bone loss of immediately loaded narrow diameter implants placed in fresh extraction sockets of mandibular incisors

> **G. BAVETTA¹, C. PADERNI², V. RANDAZZO¹, G. BAVETTA¹, A. CAVATAIO¹, S. RAVAZZOLO³, G. E. ROMANOS⁴**

¹DDS, Private Practice, Palermo, Italy

²DDS, PhD, Private Practice, Palermo, Italy

³DDS, Private Practice, Portogruaro, Italy

⁴DDS, PhD, Prof Dr med dent, Stony Brook University, School of Dental Medicine, Dept. of Periodontology, Stony Brook, NY, USA

TO CITE THIS ARTICLE

Bavetta G, Paderni C, Randazzo V, Bavetta G, Cavataio A, Ravazzolo S, Romanos GE. Marginal bone loss of immediately loaded narrow diameter implants placed in fresh extraction sockets of mandibular incisors. *J Osseointegr* 2022;14(1):6-12.

DOI 10.23805/JO.2022.14.12

KEYWORDS Bone changes; Lower incisors; Morse-taper connection; Narrow implants; Platform switching.

ABSTRACT

Aim The aesthetic success of implant therapy in the anterior sites is determined by the respect of the soft and hard tissue integrity, the fundamental peri-implant structures required for tissue stability. The aim of this study was to evaluate the 1-year marginal bone level changes of immediately loaded narrow diameter implants (NDI) with conical implant-abutment connection and platform switching that were placed in fresh extraction sockets of mandibular incisors.

Materials and methods Twenty narrow implants were immediately loaded after placement in fresh extraction sockets for the replacement of single lower incisors. To evaluate interproximal bone peak changes around the implants, standardized periapical radiographs were performed at t0 (placement), t1 (4-month healing), and t2 (1-year after loading the final restoration). All data were subjected to statistical analysis using Student's t-test ($p < 0.01$).

Results No implant failure or complications were recorded throughout the duration of the study. The mean bone loss at t2 on the mesial proximal aspect of implants was 0.227 ± 0.13 mm, and was 0.174 ± 0.24 mm on the distal proximal aspect. The p-values for mesial and distal bone loss were not statistically significant at t1 and t2. An average peri-implant bone loss of 0.337 mm was recorded for the duration of the study interval (16 months).

Conclusion Our study revealed no significant changes in interproximal bone peaks one year after the functional loading of immediately loaded NDI for replacement of mandibular incisors with conical connection and platform switching placed in fresh extraction sockets.

INTRODUCTION

The replacement of the anterior teeth with implant-supported prostheses cannot only be based on the biological principles of osseointegration by Branemark (1) and the success criteria of Albrektsson (2), but must also guarantee an adequate aesthetic result (3), obtaining a correct proportion between the white color of the tooth and the pink color of the gingiva. The aesthetic outcome can be considered through different aspects of anatomical parameters, including the presence of interproximal papilla and the correct position of the gingival zenith (4, 5).

Tarnow et al. have shown that the presence of the interproximal dental papilla depends on the distance from the contact point to the bone crest: when this measurement is 5 mm or less, the papilla is present almost 100% of the time (6). After implant treatment, the presence of the papilla depends on the maintenance of the interproximal bony peaks of the adjacent teeth and on the accurate placement of a provisional or definitive prosthetic restoration that determines the interdental contact point.

In the same way, the correct location of the gingival zenith is guaranteed by the preservation and/or regeneration of the buccal plate in the edentulous bone ridge (7).

To guarantee the preservation of these bone structures, an adequate surgical procedure, appropriate implant diameter, and correct implant positioning are necessary (8). The choice of the implant diameter is usually calculated based on the alveolar crest width and must be calculated by subtracting 3 mm (1.5 mm per side) from the mesiodistal dimension of the edentulous space

to ensure the survival of the bony peaks. Subcrestal implant placement and narrow diameter implants (NDI) were recommended as a strategy for soft and hard tissue stability (9). NDI is defined as implants with a diameter < 3.5 mm and is divided into 3 categories by Klein et al.: category 1: < 3.0 mm ("mini-implants"); category 2: 3.0 to 3.25 mm; and category 3: 3.30 to 3.50 mm (10). These implants are necessary for the replacement of teeth with a mesiodistal diameter < 6.5 mm, such as lower incisors and upper lateral incisors in females (11–13).

The implant-abutment connection can influence the maintenance of peri-implant bone levels (14). Platform switching, which occurs when the abutment has a smaller diameter than the implant platform (15), locates the micro gap of the implant-abutment connection away from the vertical bone-to-implant contact area. Moreover, a conical implant-abutment connection reduces the micro-movements and bacterial accumulation that could create an insult on the crestal bone. Both of these advantages can allow for better long-term implant prognosis and peri-implant soft tissue stability (16, 17).

This study aimed to evaluate the marginal bone level changes around immediately loaded narrow-diameter implants with conical implant-abutment connection and platform switching placed in fresh extraction sockets after one year of functional loading.

MATERIALS AND METHODS

This retrospective pilot study was conducted at a private practice (Dr. Giuseppe Bavetta, Palermo, Italy). During the period of November 2016–January 2018, 20 narrow implants (Eztetic™ Implant, Zimmer-Biomet, Palm Beach Gardens, FL, USA) were placed in a homogeneous sample, consisting of patients requiring a single crown restoration for the replacement of a lower incisor.

Patients, who were 18 or older and able to indicate written informed consent were eligible for inclusion in this study. Exclusion criteria were: a) general contraindications to implant surgery; b) previous head and neck chemo/radiotherapy; c) treated or under treatment with oral or intravenous bisphosphonates; d) uncontrolled diabetes; e) poor oral hygiene and

motivation; f) acute or uncontrolled periodontitis; g) pregnancy; h) severe bruxism (i.e. clear clinical signs and symptoms). The principles outlined in the Declaration of Helsinki on clinical research involving human beings were adhered to. All patients were adequately informed of the treatment modalities and signed a written informed consent form before being enrolled in the present study.

For each case, an initial cone-beam computed tomogram (CBCT) was performed to virtually evaluate the possibility of placing an implant in the fresh extraction socket (Fig. 1). A ".stl" file" was acquired utilizing an intra-oral scanner and, after matching the ".stl" and DICOM file together, a template for a flapless surgical placement of the implants was obtained (18). All patients underwent at least one session of oral hygiene instructions and professionally delivered debridement when required before the surgery session. Anti-microbial prophylaxis was obtained with 1g of amoxicillin and clavulanic acid (Augmentin, Roche spa, Milan) every 12 hours from 4 days before the surgical procedure to the 3rd post-surgical day (19). Patients allergic to penicillin were given clarithromycin 500 mg (Klacid, Abbott Srl, Rome, Italy) according to the previously described treatment protocol. On the day of surgery, patients were treated under local anesthesia. After tooth extraction, debridement of the extraction fresh socket was performed and each implant was inserted flapless in a fresh socket using the template for guided surgery (Fig. 2). To perform immediate loading, we achieved a torque value equal to or greater than 30 Ncm) (20). Tapered narrow-diameter implants titanium grade 5 (Eztetic Implant, Zimmer Biomet, Palm Beach Gardens, FL, USA) with conical Double Friction Fit™ connection and platform switch were used. All gaps in the fresh sockets were grafted with xenograft bone (RegenerOSS, Zimmer Biomet, Palm Beach Gardens, FL, USA) to cover implant surfaces as described by Chu et al. (21). In all cases, a screw-retained provisional crown was immediately inserted (t0) and maintained during 4-months to achieve implant osseointegration (t1) (Fig. 2). After healing, final restoration was inserted (Fig. 3). To evaluate implant success and mesiodistal interproximal bone changes around implants, all patients underwent a check-up and radiographs after 1 year of prosthetic

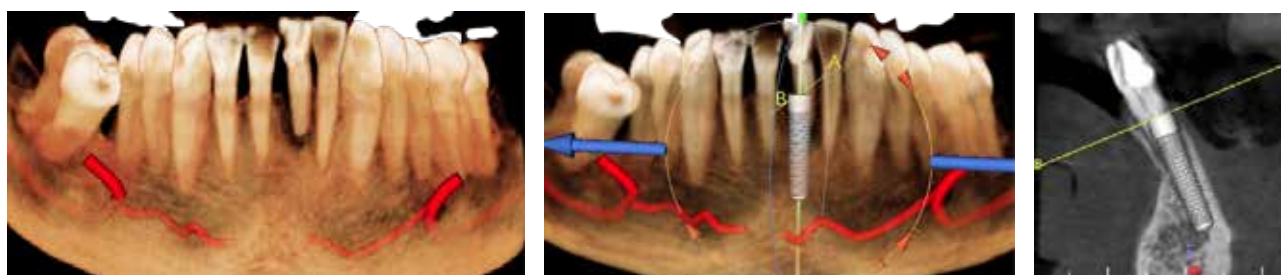


FIG. 1. An initial CBCT was performed to virtually evaluate the possibility of placing a narrow implant in the fresh extraction socket.

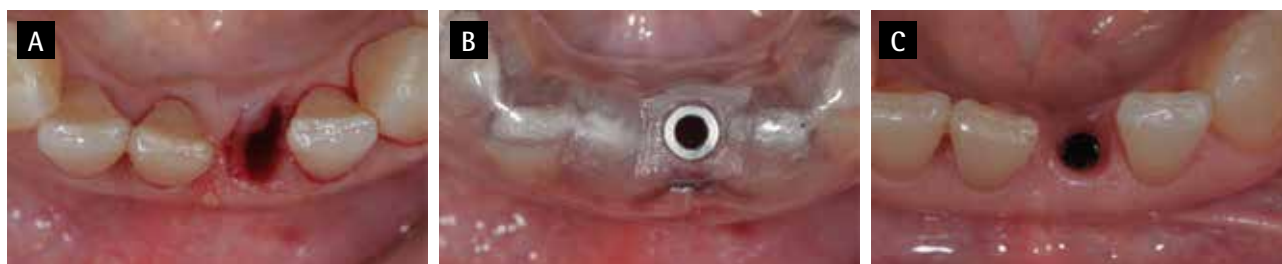

FIG. 2 A: fresh extraction socket after tooth extraction. B: surgical template for guided implant placement. C: bone volume and tissue peri-implant contour after 4-month healing and removal of screw-retained provisional immediately placed after implant placement.

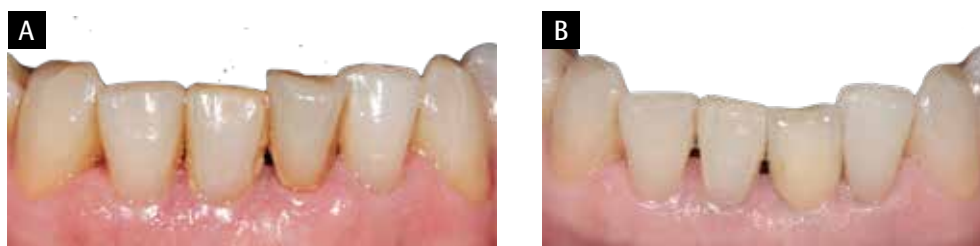

FIG. 3 A: Clinical initial case: 3.1 tooth needs to be replaced. B: final restoration (t2); the use of NI with conical and platform switching connection and a correct surgical and prosthetic protocol guarantee the preservation of initial bone volume supporting peri-implant soft tissue for a good long-term aesthetic outcome.

loading of the final restoration (t2).

All necessary data to evaluate the study outcomes were collected for each patient.

Implant success was evaluated as the absence of implant mobility, progressive marginal bone loss, or infection at t1 and t2. For all patients,, marginal bone loss was assessed by probing and presence/absence of bleeding at t1 and t2. At t1, the stability of each implant was measured digitally by ISQ values with OSSTELL (W&H Italia SRL, Italy). An ISQ value ≥ 65 was considered adequate to switch to the final restoration. At t2, implant success was evaluated after the clinical and radiographic check-up.

Complications were considered any biological or prosthetic complication that occurred during the follow-up time.

Implant interproximal bone level changes during follow-up time were evaluated by standardized periapical radiographs performed at t0 (implant placement), t1 (final restoration placement), and t2 (1 year after loading the final restoration). The radiography equipment used was composed of a long-cone paralleling technique for digital radiography, with the aid of the Rinn XCP x-ray holder and a Gendex x-ray machine. Bite blocks were customized for each patient with the aid of a low contraction red acrylic resin (Duralay, Reliance Dental MFG. Co, USA). Digital radiographs were converted to TIFF format with a 600dpi resolution. Peri-implant marginal bone levels were measured using VixWin software (Gendex, Kav0 Dental). Known implant lengths were used for the calibration of the measurements. The measurements were taken parallel to the implant axis

on both its mesial and distal surface. Reference points for the linear measurements were the most coronal margin of the implant collar and the most coronal point of bone-to-implant contact. Crestal bone loss changes were obtained by subtracting the bone level at t0 from the bone level at t1 and t2. One examiner, who was not involved in the treatment of patients evaluated all intraoral radiographs. Intra-examiner reliability was assessed in the sample of 25 randomly selected periodical radiographs that were measured twice, baseline, and after 4 months. In all cases recorded data did not show any differences (Pearson correlation coefficient of 0.992, $P=0.000$) (Fig. 4).

Descriptive statistics were obtained for all evaluated parameters, and baseline patient and implant characteristics were summarized in terms of frequencies and percentages. The Student's paired t-test was used to evaluate the bone level changes. Significance was considered at $p<0.05$.

RESULTS

Twenty patients (10 males and 10 females; average age: 56.5 years, min: 24, max: 76) were enrolled in the study. The homogeneity of the sample was guaranteed as only patients with the need to replace lower incisors were considered eligible for the study. The main baseline patient features, implant site, and sizes are listed in Table 1. During the surgical and prosthetic steps of the treatment plan, there were no complications; at t1 and t2 no implant failed (100% implant survival). In no cases

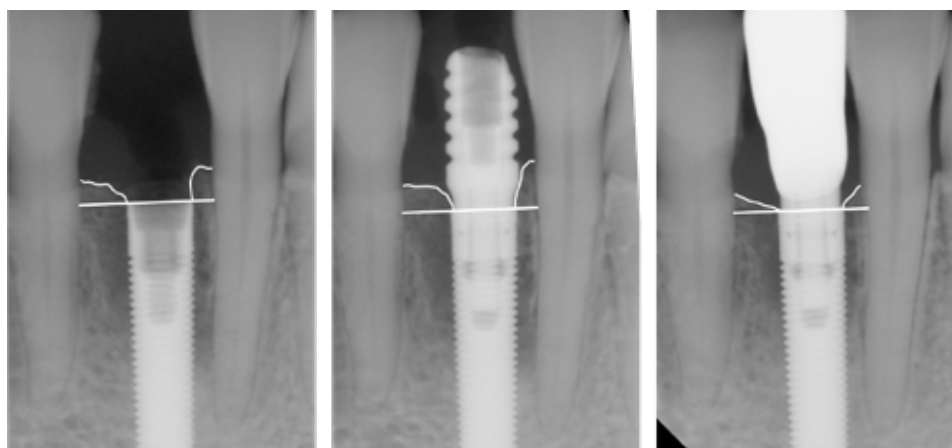


FIG. 4. Standardized periapical radiographs performed at t0 (implant placement), t1 (4-month healing with screw-retained provisional) and t2 (1-year load with final restoration); Reference points for the linear measurements were the most coronal margin of the implant collar and the most coronal point of bone-to-implant contact. Bone loss changes were obtained subtracting the bone level at t0 from the bone level at t1 and t2.

with implant mobility, bleeding on probing, suppuration or peri-implant radiolucency were reported.

Probing depth mean values of 4 sites at T1 and T2 and overall values at the same time point were as follows.

- T1: mesial 2.78 ± 1.2 ; distal 2.32 ± 1 ; buccal 2.64 ± 1.2 ; lingual 2.75 ± 1.3 ; overall mean: 2.62 ± 0.2 .
- T2: mesial 2.8 ± 0.5 ; distal 2.49 ± 0.8 ; buccal $2.72 \pm$

0.4 ; lingual 2.78 ± 0.5 ; overall mean: 2.69 ± 0.1 .

The radiographic data are summarized in Table 1. At t1 (4-month healing with provisional restoration), the mean bone loss around the mesial and distal implant surface was 0.2 ± 0.394 and 0.075 ± 0.142 , respectively (Table 2). These bone change values were not statistically significant, suggesting good preservation of bone

ID implant	Age	Sex	Implant position	Implant size	t0-t1 on mesial aspect	t1-t2 on mesial aspect	t0-t1 on distal aspect	t1-t2 on distal aspect
1	55	F	31	3.1x16mm	0,62	0,24	0,24	0,012
2	54	F	31	3.1x13mm	0,1	0,15	0,15	0,13
3	47	M	31	3.1x 16mm	-0,26	0,12	0,12	0,16
4	48	M	31	3.1x16mm	0,55	0,31	0,31	0,012
5	55	M	41	3.1x16mm	0,59	0,32	0,32	0,011
6	50	F	31	3.1x 16mm	-0,88	0,16	0,16	1,02
7	54	M	42	3.1x 16mm	-0,45	0,47	0,47	0,34
8	53	F	32	3.1x16mm	0,09	0,1	0,1	0,25
9	76	M	42	3.1x 16mm	-0,04	0,02	0,02	0,01
10	73	F	41	3.1x 16mm	0,02	0,035	0,035	0,021
11	72	M	32	3.1x 16mm	0,25	0,28	0,28	0,24
12	65	F	31	3.1x16mm	0,21	0,25	0,25	0,16
13	58	F	31	3.1x 13mm	0,52	0,53	0,53	0,48
14	68	F	42	3.1x13mm	0,16	0,08	0,08	0,17
15	60	M	41	3.1x16mm	0,36	0,27	0,27	0,3
16	58	F	31	3.1x16mm	0,59	0,32	0,32	0,01
17	24	M	32	3.1x 16mm	0,55	0,31	0,31	0,021
18	45	M	41	3.1x 16mm	0,62	0,24	0,24	0,021
19	57	M	42	3.1x 13mm	0,26	0,21	0,21	0,02
20	59	F	32	3.1x16mm	0,15	0,13	0,13	0,11

TABLE 1 Main baseline patient features, implant size and location, and radiographic data a t0-t1 and t1-t2.

	t0-t1	t0-t2	t0-t2	t0-t2	TEST STUDENT	CRITICAL VALUE P<0,01
	($\mu \pm \sigma$)	σ^2	($\mu \pm \sigma$)	σ^2	t0-t1/t0-t2	
Mesial	0,200 \pm 0,394	0,140	0,227 \pm 0,133	0,017	-7,42*	2,71
Distal	0,075 \pm 0,142	0,019	0,174 \pm 0,240	0,053	-0,69*	2,71

* t-test < critical value means not significant statistical difference

TABLE 2 Mean interproximal bony peaks (mesial and distal) changes recorded at t0-t1 and t1-t2. For each, mean value, variance (σ^2), and Student's t-test was calculated (p-value<0.01 was considered statistically significant).

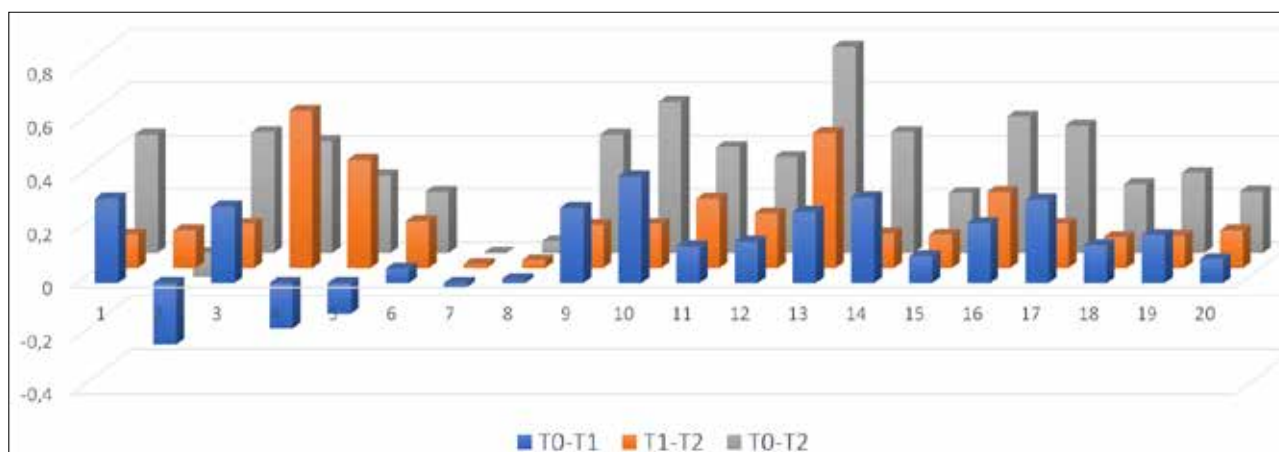


FIG. 5 Distal and mesial mean values at t0-t1, t1-t2 and t0-t2 for each patient.

volumes after tooth extraction and immediate implant placement with a screw-retained provisional. The mean bone loss at t2 on the mesial proximal aspects of implants was 0.227 ± 0.133 mm and on the distal proximal aspects of implants was 0.174 ± 0.240 mm (Table 2). The p-value for both values was found to be statistically not significant also at t2 (p-value < 0.01 is highly statistically significant). These results suggest that no statistically significant changes in interproximal bone peaks were recorded one year after functional loading of immediately loaded narrow implants with conical and platform switched connection placed in fresh extraction sockets. These results suggest that there were good implant stability and favorable long-term prognosis of soft tissues around implants. Distal and mesial means values at t0-t1, t1-t2, and t0-t2 and overall bone loss values at t2 are reported in Figures 5 and 6 respectively.

DISCUSSION

We utilized 20 NDI with a diameter between 3 and 3.25 mm, characterized by a prosthetic abutment connection similar to standard implants ($\emptyset > 3.5$ mm).

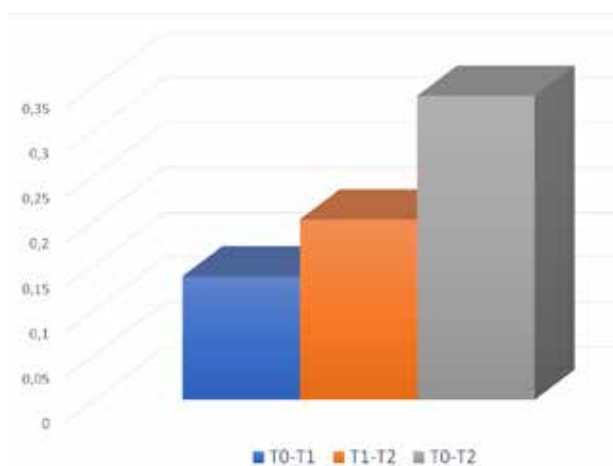


FIG. 6 Overall mean values at t0-t1, t1-t2 and t0-t2.

Restorations incorporating NDIs have resulted in similar short-term and long-term survival rates as restorations using standard implants, as a recent systematic review reported survival rates >95% (10). Another study examined the success of 255 NDIs that underwent immediate loading, of which, 194 were inserted into the healed bone and 61 in post-extractive sites. No statistically significant difference was reported, suggesting that even the immediate loading of NDIs placed in fresh extraction sockets should be considered

as safe and predictable a procedure as those that utilize standard diameter implants (22).

It has been suggested that an NDI could lead to a smaller implant/bone contact area and reduced fracture resistance (23, 24). However, no such association was observed in a recent review: only two fractures were recorded out of a total of 2,980 implants (25). Fatigue fracture has been reported to occur after a long loading period (26) and is around 0.2–0.6%. Regarding length, the failure rate tends to increase when using implants measuring <13 mm in length, compared with longer implants (27). In all cases, however, before choosing NDI, the biomechanical risk factors must be carefully evaluated, such as the possible presence of parafunction (e.g. grinding and/or dental clenching). However, implants with a narrow diameter had similar mechanical stability after insertion compared to conventional diameter implants *in vitro* (28). The slightly tapered implant macro-design seems to be more important than the implant diameter (29).

In the relevant literature, the use of these implants is well documented in cases of anterior teeth not subjected to excessive functional loading (11). Moreover, NDIs may be utilized in specific instances where the alveolar ridge is thin, allowing in some cases to avoid the need for bone grafting, especially in elderly patients or those with risk factors for invasive procedures. On the contrary, the use of standard-diameter implants in non-ideal anatomical situations could increase the risk of complications and failures.

For these reasons, the choice of implant diameter must be carefully considered in narrow edentulous spaces, like in the mandibular incisor region. Currently, conical connections can reduce micromovements and microgaps, which results in less bone resorption and more mechanical stability, improving the connection (29). A recent study by Vella et al. (30) suggested that the use of platform switched implants allows for placement 1 mm from adjacent teeth, and these implant types still maintain the bone interproximal peaks after about one year of loading. Furthermore, reducing the implant-tooth distance may result in better aesthetic and functional results in situations with limited mesiodistal space. However, Romanos and Javed (31) suggested that crestal bone loss around implants seems to be associated with several factors other than platform switching, such as the cervical features of the implant design, 3D-implant positioning, prosthetic concept, width of the alveolar ridge, and prevention of micromotion at the implant-abutment interface. A subcrestal placement was recommended (9). In a lower number of cases using the same implant design, a minimal crestal bone loss (0.21 mm) was reported after 2 years of loading restoring mandibular incisors with immediate implants without abutment removal (32).

In our study, all NDIs were inserted in fresh sockets employing a flapless guided surgery protocol and were

immediately loaded with screw-retained provisional restorations (t0); all residual gaps between implants and bone walls were filled with bone graft.

After the 1-year loading follow-up of the final restoration (t2), further radiographic examinations were recorded for each implant and the interproximal peak changes between t1 and t2 were measured in the same way. The mean bone loss at t2 on the mesial proximal aspects of implants was 0.227 ± 0.133 mm, on the distal proximal aspect of implants was 0.174 ± 0.240 mm, and an average value of 0.2 mm. This further bone loss that occurs in the t1-t2 interval, as mentioned, is referred to as the stabilization of bone remodeling due to the possible removal of the abutment to finalize the prosthetic restoration.

This result suggests that the maintenance of the periosteum integrity avoiding disturbing bone vascularization through a guided flapless surgery in fresh sockets, the maintenance of the functional stimulus through immediate loading, and the use of a bone graft have contributed to the preservation of bone volume and the limitation morpho-structural changes of the socket. It is the authors' opinion that these excellent results were due to the kind of implants and the surgical and prosthetic protocols used. Limitations of the present study are the small sample size, and that the 1-year follow-up may be too short to make definitive statements on the predictability of the treatment option tested. Longer follow-up periods and larger sample size are needed for confirmation of the proposed conclusions.

CONCLUSIONS

NDIs with conical implant-abutment connection and platform switching inserted in fresh extraction sockets and immediate loading represent the best option for the replacement of small diameter teeth, such as the lower incisors. Their use, together with an appropriate surgical and prosthetic protocol, has shown bone remodeling following tooth extraction and establishment of the biological width.

The maintenance of the crestal bone peaks guarantees adequate support to the peri-implant soft tissues for long-term aesthetic success.

Conflicts of interest

None. The authors certify that they have NO affiliations with or involvement in any organization or entity with any financial interest (such as honoraria; educational grants; membership, employment, consultancies, stock ownership, or other equity interest; and expert testimony or patent-licensing arrangements), or non-financial interest (such as personal or professional relationships, affiliations, knowledge or beliefs) in the subject matter or materials discussed in this manuscript.

REFERENCES

1. Branemark PI. Osseointegration and its experimental background. *J Prosthet Dent* 1983;50(3):399-410.
2. Albrektsson T, Zarb G, Worthington P, Eriksson AR. The long-term efficacy of currently used dental implants: a review and proposed criteria of success. *Int J Oral Maxillofac Implants* 1986;1(1):11-25.
3. Smith DE, Zarb GA. Criteria for success of osseointegrated endosseous implants. *J Prosthet Dent* 1989;62(5):567-72.
4. Furhauser R, Florescu D, Benesch T, Haas R, Mailath G, Watzek G. Evaluation of soft tissue around single-tooth implant crowns: the pink esthetic score. *Clin Oral Implants Res* 2005;16(6):639-44.
5. Jemt T. Regeneration of gingival papillae after single-implant treatment. *Int J Periodontics Restorative Dent* 1997;17(4):326-33.
6. Tarnow D, Elian N, Fletcher P, Froum S, Magner A, Cho SC, et al. Vertical distance from the crest of bone to the height of the interproximal papilla between adjacent implants. *J Periodontol* 2003;74(12):1785-8.
7. Elian N, Jalbout ZN, Cho SC, Froum S, Tarnow DP. Realities and limitations in the management of the interdental papilla between implants: three case reports. *Pract Proced Aesthet Dent* 2003;15(10):737-44; quiz 746.
8. Sarnachiaro GO, Chu SJ, Sarnachiaro E, Gotta SL, Tarnow DP. Immediate Implant Placement into Extraction Sockets with Labial Plate Dehiscence Defects: A Clinical Case Series. *Clin Implant Dent Relat Res* 2015;18(4):821-9.
9. Romanos GE. Tissue preservation strategies for fostering long-term soft and hard tissue stability. *Int J Periodontics Restorative Dent* 2015;35(3):363-71.
10. Klein MO, Schiegnitz E, Al-Nawas B. Systematic review on success of narrow-diameter dental implants. *Int J Oral Maxillofac Implants* 2014;29 Suppl:43-54.
11. Davarpanah M, Martinez H, Tecucianu JF, Celletti R, Lazzara R. Small-diameter implants: indications and contraindications. *J Esthet Dent* 2000;12(4):186-94.
12. Misch CE. Consideration of biomechanical stress in treatment with dental implants. *Dent Today* 2006;25(5):80, 82, 84-5; quiz 85.
13. Vigolo P, Givani A. Clinical evaluation of single-tooth mini-implant restorations: a five-year retrospective study. *J Prosthet Dent* 2000;84(1):50-4.
14. Baggi L, Di Girolamo M, Mirisola C, Calcaterra R. Microbiological evaluation of bacterial and mycotic seal in implant systems with different implant-abutment interfaces and closing torque values. *Implant Dent* 2013;22(4):344-50.
15. Lazzara RJ, Porter SS. Platform switching: a new concept in implant dentistry for controlling postrestorative crestal bone levels. *Int J Periodontics Restorative Dent* 2006;26(1):9-17.
16. Macedo JP, Pereira J, Vahey BR, Henriques B, Benfatti CAM, Magini RS, et al. Morse taper dental implants and platform switching: The new paradigm in oral implantology. *Eur J Dent* 2016;10(1):148-154.
17. Romanos GE, Biltucci MT, Kokaras A, Paster BJ. Bacterial Composition at the Implant-Abutment Connection under Loading in vivo. *Clin Implant Dent Relat Res* 2016;18(1):138-45.
18. Vafiadis D, Goldstein G, Garber D, Lambrakos A, Kowalski B. Immediate Implant Placement of a Single Central Incisor Using a CAD/CAM Crown-Root Form Technique: Provisional to Final Restoration. *J Esthet Restor Dent*;29(1):13-21.
19. Casap N, Zeltser C, Wexler A, Tarazi E, Zeltser R. Immediate placement of dental implants into debrided infected dentoalveolar sockets. *J Oral Maxillofac Surg* 2007;65(3):384-92.
20. Bavetta G, Bavetta G, Randazzo V, Cavataio A, Paderni C, Grassia V, et al. A Retrospective Study on Insertion Torque and Implant Stability Quotient (ISQ) as Stability Parameters for Immediate Loading of Implants in Fresh Extraction Sockets. *Biomed Res Int* 2019;2019:9720419.
21. Chu SJ, Salama MA, Salama H, Garber DA, Saito H, Sarnachiaro GO, et al. The dual-zone therapeutic concept of managing immediate implant placement and provisional restoration in anterior extraction sockets. *Compend Contin Educ Dent* 2012;33(7):524-32, 534.
22. Degidi M, Piattelli A, Carinci F. Clinical outcome of narrow diameter implants: a retrospective study of 510 implants. *J Periodontol* 2008;79(1):49-54.
23. Allum SR, Tomlinson RA, Joshi R. The impact of loads on standard diameter, small diameter and mini implants: a comparative laboratory study. *Clin Oral Implants Res* 2008;19(6):553-9.
24. Schwarz MS. Mechanical complications of dental implants. *Clin Oral Implants Res* 2000;11 Suppl 1:156-8.
25. Sierra-Sanchez JL, Martinez-Gonzalez A, Garcia-Sala Bonmati F, Manes-Ferrer JF, Brotons-Oliver A. Narrow-diameter implants: are they a predictable treatment option? A literature review. *Med Oral Patol Oral Cir Bucal* 2014;19(1):e74-81.
26. Malo P, de Araujo Nobre M. Implants (3.3 mm diameter) for the rehabilitation of edentulous posterior regions: a retrospective clinical study with up to 11 years of follow-up. *Clin Implant Dent Relat Res* 2011;13(2):95-103.
27. Arisan V, Bolukbasi N, Ersanli S, Ozdemir T. Evaluation of 316 narrow diameter implants followed for 5-10 years: a clinical and radiographic retrospective study. *Clin Oral Implants Res* 2010;21(3):296-307.
28. Romanos GE, Delgado-Ruiz RA, Sacks D, Calvo-Guirado JL. Influence of the implant diameter and bone quality on the primary stability of porous tantalum trabecular metal dental implants: an in vitro biomechanical study. *Clin Oral Implants Res* 2018;29(6):649-655.
29. Schmitt CM, Nogueira-Filho G, Tenenbaum HC, Lai JY, Brito C, Doring H, et al. Performance of conical abutment (Morse Taper) connection implants: a systematic review. *J Biomed Mater Res A* 2014;102(2):552-74.
30. Vela X, Mendez V, Rodriguez X, Segala M, Tarnow DP. Crestal bone changes on platform-switched implants and adjacent teeth when the tooth-implant distance is less than 1.5 mm. *Int J Periodontics Restorative Dent* 2012;32(2):149-55.
31. Romanos GE, Javed F. Platform switching minimises crestal bone loss around dental implants: truth or myth? *J Oral Rehabil* 2014;41(9):700-8.
32. Peron C, Romanos G. Immediate Provisionalization of Single Narrow Implants in Fresh Extraction Sockets and Healed Sites: Clinical and Radiographic Outcomes of 2 Years Follow-up. *Int J Periodontics Restorative Dent* 2020;40(3):417-424.