

Pterygoid implants: anatomical considerations and surgical placement

> **P. GEORGE¹, G. M. KURTZMAN²**

¹Clinical lecturer in Restorative dentistry at Royal Liverpool University Dental Hospital, Liverpool, UK

²General dentist in Silver Spring, MD, USA

TO CITE THIS ARTICLE

George P, Kurtzman GM. Pterygoid Implants: Anatomical considerations and surgical placement. *J Osseointegr* 2022;14(2):81-87.

DOI 10.23805/JO.2022.14.15

ABSTRACT

Aim Loss of bone in the posterior maxilla through resorption due to atrophy, periodontal disease or enlargement of the maxillary sinus create challenges to implant placement. Frequently, osseous augmentation has been utilized to create adequate bone volume to house traditional implants. In recent years, utilization of specialized implants placed into the pterygoid area have allowed circumvention of the lack of adequate bone in the molar region, while avoiding sinus augmentation to utilize bone on the tuberosity area to either connect with traditional implants in the premolar zone, angled pterygoid implants avoiding the anterior wall of the sinus or in severe resorption cases to zygomatic implants.

Materials and methods This article will discuss the utilization of pterygoid implants from planning to surgical placement and the initial restorative phase of treatment.

Results Pterygoid implants allow restoration of the resorbed posterior maxilla in less time by avoiding the healing period required when osseous grafting would be required to place implants in the deficient ridge below the enlarged sinus. Treatment costs for the patient are also shortened by elimination of maxillary sinus augmentation procedures.

Conclusion Pterygoid implants should be considered when inadequate bone is present in the posterior maxilla as an alternative to osseous augmentation to permit implant placement.

KEYWORDS Pterygoid implants; Maxillary posterior resorption; Tuberosity; Pterygoid process; Osseodensification.

INTRODUCTION

Loss of teeth in the maxilla, specifically in the posterior segments, may complicate implant placement related to

enlargement of the maxillary sinus through a combination of crestal resorption and pneumatization of the sinus, both natural occurrences. The posterior maxilla poses some challenges for the surgeon with limitations to implant placement (1). Those include low bone quality and quantity, pneumatization of the maxillary sinus and poor accessibility to the area (2). Low bone density at possible implant sites reduces implant success related to impairment of the primary stability of the implants (3-5). Implant placement in those circumstances has traditionally required sinus augmentation to create sufficient volume of bone to house the planned implants. This may allow simultaneous implant placement at the time of grafting or may require a delay to allow graft healing before implant placement. Alternatively, implant placement into the tuberosity with engagement into the pterygoid process has been utilized to avoid augmentation of the sinus and take advantage of bone present in that region and the anatomy.

Pterygoid implants have been placed in combination with traditional implants placed mesial to the maxillary sinus (premolar area) and in combination with zygomatic implants when restoring a partially or fully edentulous maxillary arch. Implant placement in the tuberosity and pterygoid region provides posterior bone support, while not requiring sinus augmentation, utilizing bone present to house the implant. Placement of pterygoid implants is more technically demanding than placement of traditional implants either in a grafted sinus area or anterior to the maxillary antrum. Few risks associated with implant placement in pterygoid area have been reported and placement in this region allows more distal placement of implants for better prosthetic load management. Loss of the implant into the infratemporal space, affecting pterygoid muscles, trauma to nerves leading to facial sensory issues is one of the few risks with placement of implants into this area (6). A meta-analysis from 1995 through 2018 reported mean implant survival rate of 94.87%, demonstrating that pterygoid implants can be successfully used in patients with atrophic posterior maxilla (7).

Anatomy of the posterior maxilla

The tuberosity is the posterior portion of the maxillary alveolar ridge and presents as a convex protuberance that

is typically distal to the second molar when present. The medial and posterior boundary is the pyramidal process of the palatine bone and the anterior surface of the pterygoid process of the sphenoid bone (8). The pyramidal process binds to the anterior surface of the pterygoid plates of the sphenoid bone and is interposed between the inferior end of the pterygoid plates and the maxillary tuberosity creating a narrow column of dense bone, referred to as the pterygoid pillar, into which the apical portion of an implant may be placed. The bone within the tuberosity is typically of poor quality; therefore, use of osseodensification with appropriate instruments such as the Densah burs (Versah LLC, Jackson, Michigan, USA) is recommended to improve bone quality around the implant being placed into the pterygoid area.

When the tuberosity has favorable dimensions in height, width, and length, an implant may be successfully placed within this osseous anatomy. However, when the volume and/or quality of the tuberosity bone is insufficient, a more medially angled and posteriorly placed implant is determined by the maxillary sinus posterior walls angle (9). The implant requires placement parallel to the posterior sinus wall to prevent penetration of the sinus, necessitating the angled implant placement. Related to the anatomy an implant may be placed to have greater bone-implant-contact (BIC) and a tapered implant is recommended in greater length than typically placed elsewhere in the arch. Care during osteotomy preparation and implant insertion to avoid perforating the posterior wall of the maxillary sinus or the posterior aspect of the pyramidal process of the palatine bone, and the pterygoid process of the sphenoid bone. Support for pterygoid implants is derived from the maxillary tuberosity, the pyramidal process of the palatine bone, and the pterygoid process of the sphenoid bone (10). The length of pterygoid implant ensures that the implant can engage the cortical bone of the pterygopalatine suture.

Radiographic analysis is important to understand the patient's particular anatomy and plan the point of initiation into the bone by the drills as well as the

angulation that will parallel the posterior sinus wall and keep the implant within the osseous anatomy. Essentially, the edentulous tuberosity and pterygoid area is classified as one of two types (Fig. 1). Type A presents as osseous height in the tuberosity with the posterior wall of the maxillary sinus in a more anterior position, which allows the implant placement to be more vertical in orientation but still medially tilted (Fig. 1 left). This places the pterygoid implant in a higher position bypassing the pyramidal process, engaging only the tuberosity and the pterygoid bone. Typically, this has the implant platform positioned more distal than type B, which may be at the second or third molar position. A type B clinical presentation has less available osseous height to the tuberosity as well as greater sinus enlargement, necessitating a greater angle of placement so that the pterygoid implant is in a lower position engaging the tuberosity, pyramidal process and pterygoid bone (Fig. 1 right). This may place the implant platform more mesial than in type A with emergence at the 3rd molar position. Depending on whether the pterygoid implant is placed high or low, different osseous structures will be traversed by the implant when it is placed (Fig. 2). Those structures include the medial pterygoid plate of sphenoid, pyramidal process of palatine bone and the maxilla.

PTG implant and surgical procedure for pterygoid implant placement:

The PTG implant (Biohorizons, Birmingham, AL, USA) is specifically designed for use in the pterygoid area or may also be placed mesial to the maxillary sinus to avoid the need for sinus augmentation by angulation paralleling that structure. The implant is available in a 4.2 mm diameter in two lengths (15 and 18 mm) (Fig. 3). Determination on which length is appropriate will be based on a measurement on the radiograph from the crestal surface, paralleling the sinus and extending into the pterygoid process. The reduced apical diameter of 2.2 mm allows for precise placement of the implant apex in the narrow osseous confines with the dual tapered body

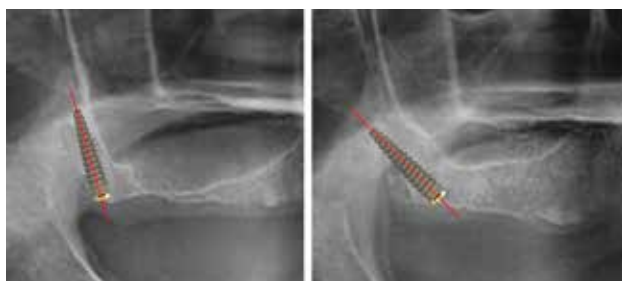

FIG. 1 The area of the posterior edentulous maxilla can be classified into two groups depending on the position of the maxillary sinus in relation to the available bone of the tuberosity where a pterygoid implant will be placed. The High PTG (left) permitting a more vertical placement going through tuberosity and reaching pterygoid plates but not passing through the pyramidal process and the Low PTG (right) requiring placement angled posteriorly which passes from tuberosity, pyramidal process and finally reaching the pterygoid plates.

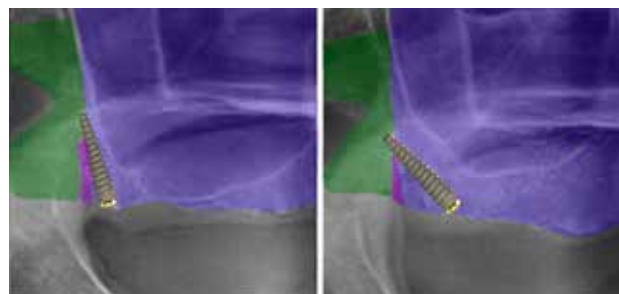


FIG. 2 The pterygoid implant depends on if its high (left) or low (right) placement contacts different bone in the posterior maxilla (green- medial pterygoid plate of sphenoid, purple- pyramidal process of palatine bone and blue- maxilla).



FIG. 3 The PTG (pterygoid) implants are provided in 4.2 mm diameter and in two available lengths, 15 mm and 18 mm to accommodate anatomical conditions.

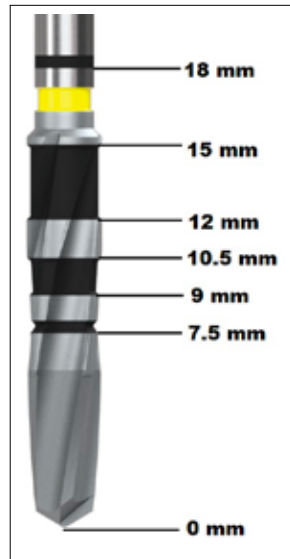


FIG. 5 The osteotomy drills are clearly marked for depth to aid in site preparation in the posterior maxilla where visualization may be hampered due to the surrounding anatomy.

and aggressive buttress threads suitable for engagement during angled placement providing stability in the pterygomaxillary region. A reduced collar is present to preserve crestal vital bone and preventing deviation during placement. The crestal 1.8 mm of the implant has the Laser-Lok surface with micro-threads that has been demonstrated to create a connective tissue attachment and aid in retaining crestal bone. The Laser-Lok surface has been shown to reduce the incidence of peri-implantitis compared to traditional surfaces and attract a physical connective tissue attachment (11-16). The implant has an internal hex connector providing a platform switch to a 3.5 mm prosthetic diameter.

Following local anesthetic administration to the posterior maxilla, a crestal incision is made from the hamular notch mesially to the premolar area, a vertical releasing incision is made at the anterior aspect of the incision and a full thickness flap is elevated to expose the tuberosity. When implants will be placed in a full arch surgical approach, the crestal incision would be continued to the opposite hamular notch and the vertical releasing incision may be placed in the canine area bilaterally or at the midline. A dimple is created at the planned osteotomy at the center of the tuberosity with a #6 round bur in the surgical handpiece (Fig. 4A). This will prevent the subsequent drill from skipping over the bone as they initiate penetration. The alignment drill (Fig. 4B) is next used to initiate the osteotomy to a depth of 5 mm at the angulation planned based on radiographic analysis. The hub on this drill prevents further penetration than 5 mm ensuring



FIG. 4 Surgical instrumentation for site preparation and placement of the pterygoid implant which includes: #6 round bur (A), alignment drill (B), 1.5 mm starter drill (C), Lindemann drill (D), osteotomy drills in 2.0, 2.5, 2.8, 3.2 and 3.7 mm diameter (E), handpiece driver (F), ratchet driver (G), drill extender (H), 4 mm square drive extender and hand wrench (I), deep bone profiler (J) and bone profiler guide pin (K).

greater safety. The alignment drill can be removed from the handpiece and inserted into the hole it created in the tuberosity and a periapical radiograph taken to verify that the trajectory of the drill parallels the posterior wall of the sinus. Should the angle require correction this may be done before proceeding to the next drill. Next, the 1.5 mm starter drill (Fig. 4C) is utilized to a depth until the dense bone of the pterygoid plates are felt and. The drills are then purposefully punctured through by 1-2 mm. of 10.5 mm based on the depth marking on the drills shaft. Angulation verification may also be performed with this drill inserted into the site prior to radiograph capture. Should the angulation require correction the Lindemann bur which is side cutting may be used (Fig. 4D). The osteotomy is continued using extended shank HD drills (Fig. 4E) that are available in 2.0, 2.5, 2.8, 3.2 and 3.7 mm diameters. These drills have clear measurement markings so the surgeon can see the depth the drill is at in the posterior maxilla (Fig. 5). Should osseodensification be planned as part of site preparation following use of the 2.0 mm extended shank HD drill, the osseodensification drills would be used short of the depth to a 3.7 mm width and then the implant itself will do the final osseodensification during placement.

Drill sequence will be determined based on the density of the bone present at the site that will accommodate the implant. Bone at the osteotomy site can be thus divided into normal, low or high density and the technique employed to create the osteotomy and place the implant will vary accordingly. Site bone density can be estimated based on the radiographic appearance or in the case of use of a CBCT, the Hounsfield number as determined in the software, but is properly determined by the surgeon by use of the starter drill or 2.0 mm initial drill at the site (Fig. 6). The 2.0 mm drill is taken to the depth for the planned implant as measured from the crest utilizing the

markings on the drill for either 15 or 18 mm. A radiograph can be taken with this drill detached from the handpiece inserted into the osteotomy to verify angulation and depth related to the anatomy present.

When normal density bone is noted osteotomy sequence will follow this sequence. The osteotomy is continued with the 2.5 mm PTG drill to final depth (Fig. 7). The site is further prepared with the 2.8 mm PTG drill to final depth. This is repeated with the 3.2 mm drill (Fig. 8) and osteotomy site preparation is completed with the 3.7 mm drill to depth (Fig. 9). The site is now ready for implant placement.

Improvement in bone density in low density bone and its quality can be accomplished with osseodensification, a useful technique to obtain increased implant insertion torque and bone to implant contact (BIC) (17,18). When low density bone presents at the site osseodensification with Densah drills is recommended to improve bone quality that will surround the PTG implant being placed. Osseodensification with the Densah drills has no reported negative effects on healing (19). Following use of the 2.0 mm PTG bur to the selected depth of 15 or 18 mm. The 2.3 mm Densah osseodensification bur is advanced to depth at the angulation established by the 2.0 mm drill. This is then followed by the 2.5, 3.0, 3.3, 3.5 and then completed with the 4.0 mm Densah drills to the established depth. When very low density bone is present following use of the 3.5 mm Densah drill, the osteotomy can be filled with either autogenous or allograft bone and the 3.5 mm drill used again to further laterally condense the site increasing bone density and quality prior to implant insertion. In this clinical situation the 4.0 mm drill would not be used and the implant would provide the final osseodensification as it is inserted yielding a stable implant upon final seating in the site. As the osteotomy is greater depth and due to the position in the posterior maxilla, the drill extender (Fig. 4H) will be necessary to allow osseodensification to the desired depth to accommodate the implant being placed. When dense bone is present at the planned osteotomy site

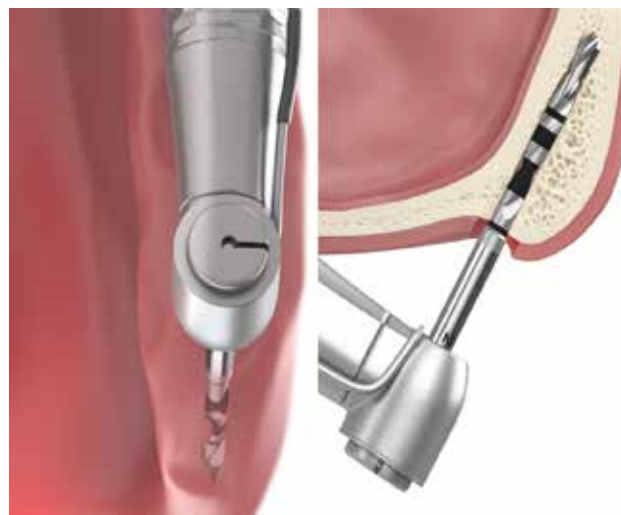

FIG. 6 A 2.0 mm drill is utilized following the same angulation and track that was performed with the 1.5mm starter drill to the desired depth of either 15 or 18 mm, depending on the PTG implant that has been planned based on anatomy present (Illustration Mike Chapman).

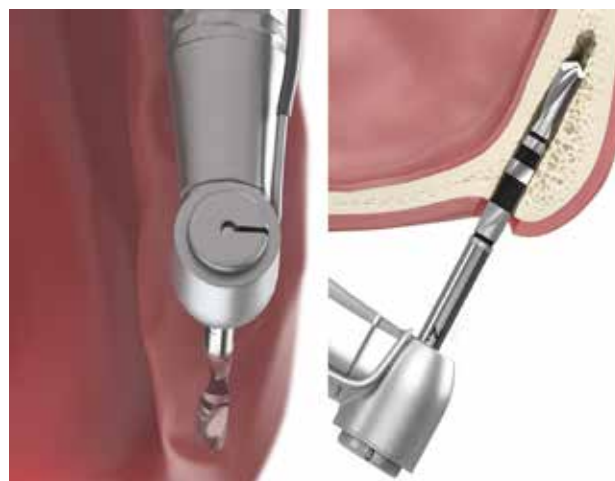

FIG. 7 The osteotomy is continued with the 2.5 mm drill to the established depth (Illustration Mike Chapman).

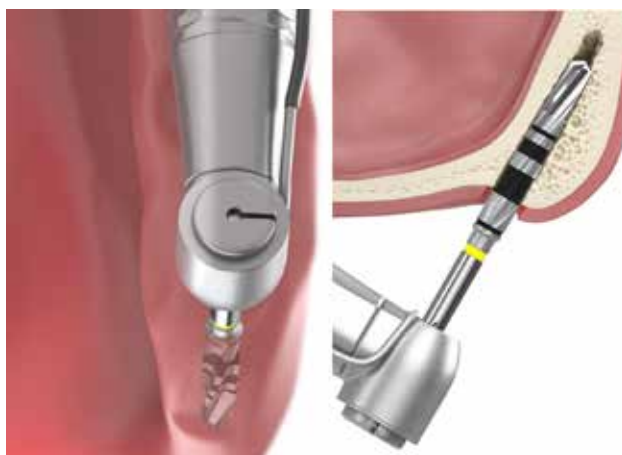

FIG. 8 The osteotomy is then continued with the 3.2 mm drill following the angulation and depth established with the prior PTG drills (Illustration Mike Chapman).

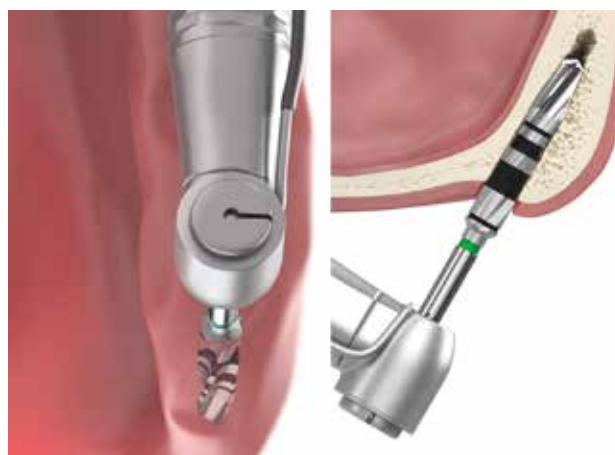

FIG. 9 The osteotomy is completed with the 3.7 mm drill to accommodate the 4.2mm diameter PTG implant which will perform osseocompression as it is inserted into the osteotomy providing good initial stability with the surrounding bone (Illustration Mike Chapman).



FIG. 10 The handpiece and ratchet drivers have a hex that locks into the internal hex in the PTG implant with a PEEK snap ring that frictionally connects the driver and implant preventing the implant from falling off the driver while carrying it to the prepared site intraorally.

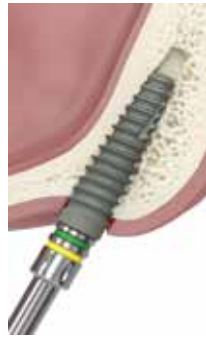

FIG. 11 Initial placement of the PTG implant into the osteotomy is accomplished with the handpiece driver until resistance is felt then further advancement is performed with the ratchet driver.



FIG. 12 Orientation of the flat of the implants internal hex is aided by a dimple on the handpiece or ratchet driver which corresponds to the hex flat.

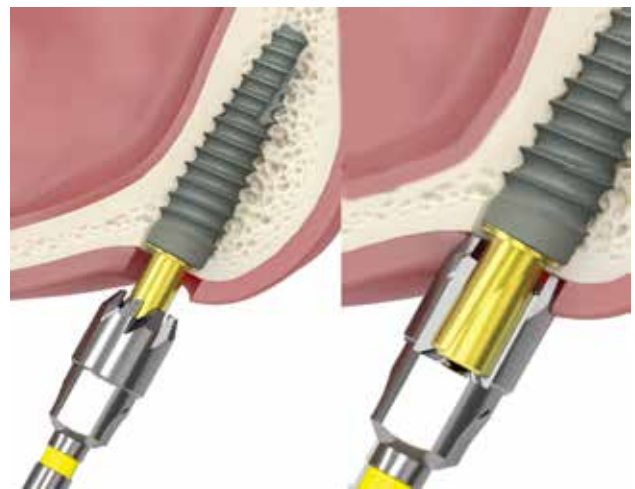

FIG. 13 A 3.5 mm diameter bone profiler is used with a guide pin that is threaded into the PTG implant to guide bone removal (left) to expose the implants platform and allow seating of prosthetic parts without sacrificing lateral bone (right) that may be removed with traditional burs at implant uncoverly.

as determined by some physical resistance when the 2.0 mm PTG drill is used, it is advised that the 2.3 mm PTG drill be used next for site preparation as the 2.5 mm drill will meet some resistance and it is possible that may cause some burnishing of the bone at the osteotomy and affect osseointegration with the implants surface. This is then followed by the 2.5, 2.8, 3.2 and 3.7 mm drills to depth. A 4.0 mm osteotomy drill can be used at the crest to a depth of 4–5 mm to allow easier implant placement in the denser bone of the site.

When the osteotomy has been completed, the handpiece driver (Fig. 4F) is placed into the surgical handpiece and inserted into the implant in the container with the hex on the driver engaging the implants internal hex. A PEEK snap ring engages the implant apical to the hex to stabilize the implant on the driver and prevent it falling when being carried from the container to the osteotomy site during insertion (Fig. 10). The implant is carried to the osteotomy on the driver and at 30 rpm and set at 35 ncm torque, the PTG implant is threaded into the site until it is placed $\frac{3}{4}$ into the osteotomy or the surgical unit reaches insertion torque (Fig. 11). Should the implant not be to the desired depth that the osteotomy was prepared to, or higher insertion torque is required to fully seat it, a ratchet driver is placed into a torque wrench (Fig. 4G) and then placed into the implant to allow greater insertion force to fully seat the implant. Should the anatomy not allow the two drivers to get close enough to place the implant into the site, a drill extender will work by engaging the latch end of the handpiece driver (Fig. 4H) or a 4 mm square drive extender can be used with the ratchet driver (Fig. 4I). A hand wrench will engage the ratchet driver or its extender when initial hand placement is desired before use of the torque wrench.

Orientation of the hex is important to align the multi-abutment correctly and one of the hex flats needs to be at the buccal of the ridge (Fig. 12 left). The geometry of

the hex will when the hex is oriented to the buccal also place a hex flat on the palatal side of the ridge. The two drivers to aid in this orientation during implant insertion have a dimple on the side of the driver that corresponds to one of the hex flats (Fig. 12 right). The goal during implant insertion is that at final insertion into the osteotomy, the dimple is at the mid buccal (or mid palatal) of the ridge, assuring that the implants hex is oriented properly.

The PTG pterygoid implant upon placement is set slightly below the crestal and modification of the crestal bone is required for placement of the multi-abutment whether immediate or delayed loading will be performed to allow osseointegration. A guide pin (Fig. 4K) is inserted into the PTG implant placed at the site, which will act as a guide for the bone profile drill to be utilized. The bone profile drill (Fig. 4J) has a diameter of 3.5 mm and is inserted over the guide pin, the handpiece activated and advanced along the pin until the guide pin prevents further advancement towards the implant. This ensures that bone is only removed immediately over the implant and the drill does not affect the most coronal surface of the implant platform.

Following bone profiling selection of the multi-abutment

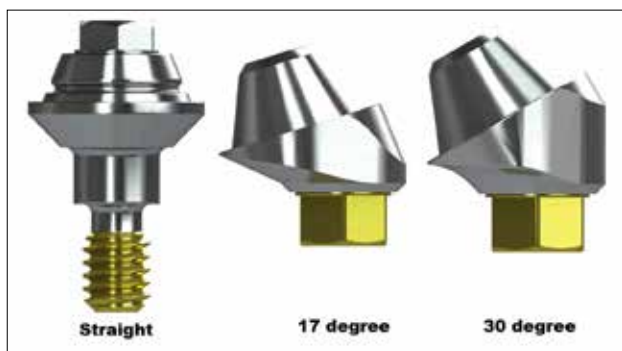


FIG. 14 Straight multi-unit abutments are typically used, but due to the angulation that the pterygoid implant is placed both in the mesial-distal and buccal-palatal planes an angled multi-abutment is required, which are available in both a 17 and 30 degree angulation with all multi-unit abutments available in different collar heights based on soft tissue depth.




FIG. 15 Multi-unit try-in abutments are available for the straight, 17 degree and 30 degree multi-abutments to aid in measurement of the soft tissue thickness to select the appropriate multi-unit abutment for that specific site.

is needed to position the implant prosthetic emergence in the proper angulation to permit restoration. Multi-abutments are available in either straight (Fig. 14 left), a 17-degree (Fig. 14 middle) or with a 30-degree angulation (Fig. 14 right). As the pterygoid implant is placed related to the osseous anatomy with the implant tipped to the mesial, typically an angled multi-abutment will be required to place the prosthetic axis so that emergence will be on the occlusal surface of the restoration. The pterygoid implant may also have been placed with it angled to the buccal due to osseous resorption. The angled multi-abutment orientation can be corrected in that plane by rotation of the abutment in a mesial or distal direction before inserting it to engage the hex of the PTG implant. Usage of a straight multi-abutment would angle the prosthetic axis to the mesial and make insertion of the prosthetics difficult to allow engagement of the multi-abutment on its mesial aspect. The straight multi-abutment is utilized on implants placed in the premolar and molar sites when that placement allowed for vertical positioning of the implants in the respected anatomy. To determine which multi-abutment is required for the site, multi-abutment

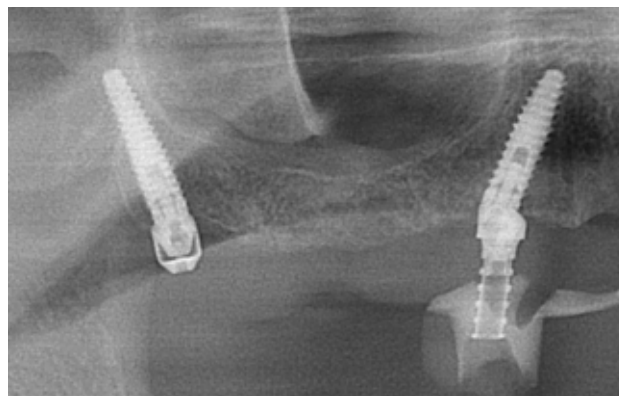


FIG. 16 Pterygoid implants may also be placed mesial to the maxillary sinus to allow avoidance of sinus augmentation and permit placement of the implant platform distal to where vertical placement in the available anatomy would allow (multi-unit cover coping on implant on left, multi-unit coping on implant on right).

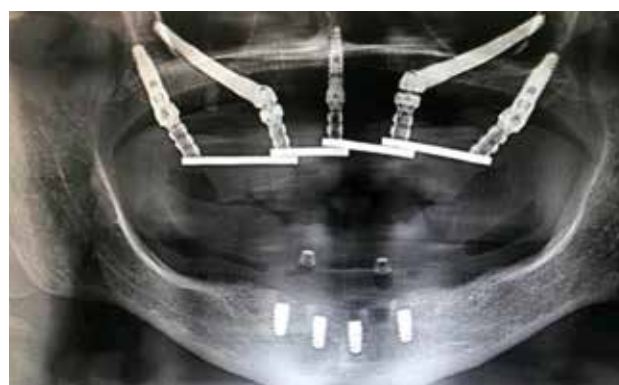


FIG. 17 PTG implant placed into the pterygoid area used in conjunction with zygomatic implants to treat a severely resorbed maxillary arch.

try-in abutments are available (Fig. 15). These try-in abutments are marked gingivally to determine soft tissue thickness to aid in selection of the correct cuff height for the multi-abutment to be utilized at that site.

If immediate loading through a provisional hybrid prosthesis is planned and insertion torque permits that, a titanium temporary abutment (multi-unit coping) is placed on to the PTG implant and picked up in the provisional restoration (Fig. 16). When immediate loading can not be performed, a multi-unit cover coping is placed on the multi-abutment to prevent irritation to the patient's cheek and tongue during the healing phase (Fig. 16).

DISCUSSION

Pterygoid implants have seen increased usage to aid in avoiding augmentation when the maxillary sinus has enlarged and/or periodontal bone loss presents with inadequate height for implant placement in the posterior maxilla. Bone in the tuberosity is typically not affected

by sinus enlargement and presents with bone to allow longer implants to be placed at or distal where the 2nd molar would be restoratively. With greater degrees of crestal resorption that will require greater angulation of the pterygoid implant to engage the available bone and preplanning through CBCT evaluation of the area is needed to determine what angulation of implant placement (group A or B) and whether a 15 or 18 mm implant will engage the osseous structures of the pterygoid area. Additionally, the PTG implant may also be utilized anterior to the maxillary sinus, skirting the mesial sinus wall when adequate bone is present in the premolar area of the arch to either connect with a PTG implant at the tuberosity or implants placed anterior to this implant (Fig. 16). Those cases being treated with zygomatic implants may also be supplemented with pterygoid implants allowing better posterior stabilization for improved load handling during function (Fig. 17).

CONCLUSION

Utilization of pterygoid implants allows restoration of the resorbed posterior maxilla in less time by avoiding the healing period required when osseous grafting would be required to place implants in the deficient ridge below the enlarged sinus. Treatment costs for the patient are also shortened by elimination of maxillary sinus augmentation procedures. Pterygoid implants should be considered when inadequate bone is present in the posterior maxilla as an alternative to osseous augmentation to permit implant placement.

REFERENCES:

- Javed F, Romanos GE. Role of implant diameter on long-term survival of dental implants placed in posterior maxilla: a systematic review. *Clin Oral Investig*. 2015;19(1):1-10. Song HY, Huh YH, Park CJ, Cho LR. A two-short-implant-supported molar restoration in atrophic posterior maxilla: A finite element analysis. *J Adv Prosthodont*. 2016;8(4):304-12.
- Jinfeng L, Jinsheng D, Xiaohui W, Yanjun W, Ningyu W. The Pneumatization and Adjacent Structure of the Posterior Superior Maxillary Sinus and Its Effect on Nasal Cavity Morphology. *Med Sci Monit*. 2017;23:4166-74.
- Zita Gomes R, de Vasconcelos MR, Lopes Guerra IM, de Almeida RAB, de Campos Felino AC. Implant Stability in the Posterior Maxilla: A Controlled Clinical Trial. *Biomed Res Int*. 2017;2017:6825213.
- Ko YC, Huang HL, Shen YW, Cai JY, Fuh LJ, Hsu JT. Variations in crestal cortical bone thickness at dental implant sites in different regions of the jawbone. *Clin Implant Dent Relat Res*. 2017;19(3):440-6.
- Kim YH, Choi NR, Kim YD. The factors that influence postoperative stability of the dental implants in posterior edentulous maxilla. *Maxillofac Plast Reconstr Surg*. 2017;39(1):2.
- Balshi TJ, Wolfinger GJ, Balshi SF 2nd. Analysis of 356 pterygomaxillary implants in edentulous arches for fixed prosthesis anchorage. *Int J Oral Maxillofac Implants*. 1999 May-Jun;14(3):398-406. PMID: 10379114.
- Araujo RZ, Santiago Júnior JF, Cardoso CL, Benites Condezo AF, Moreira Júnior R, Curi MM. Clinical outcomes of pterygoid implants: Systematic review and meta-analysis. *J Craniomaxillofac Surg*. 2019 Apr;47(4):651-660. doi: 10.1016/j.jcms.2019.01.030. Epub 2019 Feb 1. PMID: 30799134.
- von Arx T, Lozanoff S, Bornstein MM. Extraoral anatomy in CBCT – a literature review. Part 3: Retromaxillary region. *Swiss Dent J*. 2020 Mar 9;130(3):216-228. PMID: 32162855.
- Krekmanov L. Placement of posterior mandibular and maxillary implants in patients with severe bone deficiency: a clinical report of procedure. *Int J Oral Maxillofac Implants*. 2000 Sep-Oct;15(5):722-30. PMID: 11055139.
- Bidra AS, Huynh-Ba G. Implants in the pterygoid region: a systematic review of the literature. *Int J Oral Maxillofac Surg*. 2011 Aug;40(8):773-81. doi: 10.1016/j.ijom.2011.04.007. Epub 2011 May 23. PMID: 21601424.
- Nevins M, Nevins ML, Camelo M, Boyesen JL, Kim DM. Human histologic evidence of a connective tissue attachment to a dental implant. *Int J Periodontics Restorative Dent*. 2008 Apr;28(2):111-21. PMID: 18546807.
- Weiner S, Simon J, Ehrenberg DS, Zweig B, Ricci JL. The effects of laser microtextured collars upon crestal bone levels of dental implants. *Implant Dent*. 2008 Jun;17(2):217-28. doi: 10.1097/ID.0b013e3181779016. PMID: 18545054.
- Shin SY, Han DH. Influence of a microgrooved collar design on soft and hard tissue healing of immediate implantation in fresh extraction sites in dogs. *Clin Oral Implants Res*. 2010 Aug;21(8):804-14. doi: 10.1111/j.1600-0501.2010.01917.x. PMID: 20666795.
- Nevins M, Nevins M, Gobbato L, Lee HJ, Wang CW, Kim DM. Maintaining interimplant crestal bone height via a combined platform-switched, Laser-Lok implant/abutment system: a proof-of-principle canine study. *Int J Periodontics Restorative Dent*. 2013 May-Jun;33(3):261-7. doi: 10.11607/prd.1773. PMID: 23593619.
- Nevins M, Kim DM, Jun SH, Guze K, Schupbach P, Nevins ML. Histologic evidence of a connective tissue attachment to laser microgrooved abutments: a canine study. *Int J Periodontics Restorative Dent*. 2010 Jun;30(3):245-55. PMID: 20386781.
- Nevins M, Camelo M, Nevins ML, Schupbach P, Kim DM. Connective tissue attachment to laser-microgrooved abutments: a human histologic case report. *Int J Periodontics Restorative Dent*. 2012 Aug;32(4):385-92. PMID: 22577643.
- Inchingolo AD, Inchingolo AM, Bordea IR, Xhajanka E, Romeo DM, Romeo M, Zappone CMF, Malcangi G, Scarano A, Lorusso F, Isacco CG, Marinelli G, Contaldo M, Ballini A, Inchingolo F, Dipalma G. The Effectiveness of Osseodensification Drilling Protocol for Implant Site Osteotomy: A Systematic Review of the Literature and Meta-Analysis. *Materials (Basel)*. 2021 Feb 28;14(5):1147. doi: 10.3390/ma14051147. PMID: 33671038; PMCID: PMC7957527.
- Padhye NM, Padhye AM, Bhatavadekar NB. Osseodensification -- A systematic review and qualitative analysis of published literature. *J Oral Biol Craniofac Res*. 2020 Jan-Mar;10(1):375-380. doi: 10.1016/j.jobcr.2019.10.002. Epub 2019 Nov 2. PMID: 31737477; PMCID: PMC6849357.
- Witek L, Neiva R, Alifrag A, Shahraki F, Sayah G, Tovar N, Lopez CD, Gil L, Coelho PG. Absence of Healing Impairment in Osteotomies Prepared via Osseodensification Drilling. *Int J Periodontics Restorative Dent*. 2019 Jan/Feb;39(1):65-71. doi: 10.11607/prd.3504. PMID: 30543729.