

➤ **ARIS PETROS TRIPODAKIS¹, GEORGIOS KAMPEROS², NIKOLAOS NIKITAKIS³,
ALEXANDRA SKLAVOUNOU-ANDRIKOPOULOU⁴**

Department of Oral Medicine and Pathology, School of Dentistry, National and Kapodistrian University of Athens, Athens, Greece

¹Associate Professor, Department of Prosthodontics and Department of Oral Medicine and Pathology

²Postgraduate Student

³Assistant Professor

⁴Professor

Implant therapy on patients treated with oral bisphosphonates

TO CITE THIS ARTICLE

Tripodakis AP, Kamperos G, Nikitakis N, Sklavounou-Andrikopoulou A. Implant therapy on patients treated with oral bisphosphonates. *J Osseointegr* 2012;1(4):9-14.

ABSTRACT

Aim Bisphosphonates represent a group of drugs with a significant effect on bone structure preventing bone remodelling. They can be administered for the treatment of osteoporosis, Paget's disease, osteogenesis imperfecta, osteopenia and bone metastases. The aim of this study was to discuss the necessary precautions for successful implant therapy on patients treated with per os bisphosphonates.

Case reports Two female patients, both in the seventh decade of life, requested implant therapy. Their medical history was significant for osteoporosis, managed with per os bisphosphonates (Risedronate and Alendronate, respectively), without other risk factors for osteonecrosis. The duration of bisphosphonate administration was 4 years and 2 months respectively. After consultation with the treating physician, the patients stopped the bisphosphonates 3 months before and 3 months after the placement of the implants. The patients received antibiotic coverage for the surgical interventions. The treatment plan was completed uneventfully with placement of fixed prostheses without complications during a 2-year follow-up period.

Conclusion The greatest dental treatment-related risk for patients on bisphosphonate therapy is bisphosphonate-associated osteonecrosis, which presents with exposure of avascular bone of the jaws and, according to the clinical stage, pain, inflammation, fractures and/or extensive osteolysis. Most of reported cases of bisphosphonate-associated osteonecrosis consist of patients on intravenous drug therapy who had undergone dentoalveolar surgery. Patients on per os bisphosphonates may undergo all types of dentoalveolar surgery, including implant placement, as long as the necessary precautions (bisphosphonate discontinuation, antibiotic coverage, meticulous oral hygiene) are taken.

KEYWORDS Dental implants; Oral bisphosphonates; Osteonecrosis.

INTRODUCTION

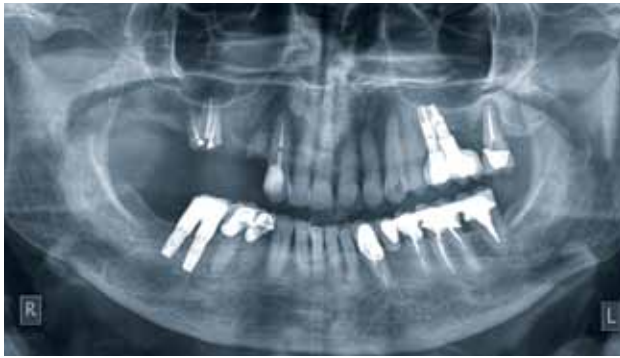The use of bisphosphonates is increasing rapidly. These drugs are being prescribed for osteoporosis, osteogenesis imperfecta, bone metastases of various malignancies (most commonly prostate or breast cancer), multiple myeloma and other diseases (1-4). The vast majority of patients on bisphosphonates are osteoporotic and receive per os treatment in order to prevent bone fractures (5). These patients frequently require dental treatment with or without dental implants (6). Nevertheless, many case reports of jaw osteonecrosis in patients on bisphosphonate therapy (bisphosphonate-related osteonecrosis of the jaws – BRONJ) have been published since 2003, and various prevention and treatment protocols for this condition have been advocated (1-4,7-9).

The aim of this paper was to present and discuss the necessary precautions for a successful dental treatment including implant placement and prevention of BRONJ in patients receiving per os bisphosphonates.

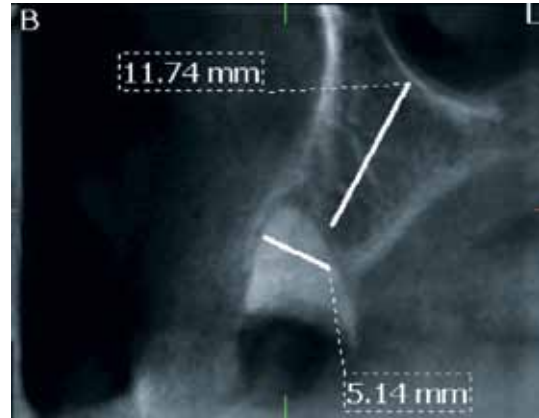
CASE REPORTS

Case report 1

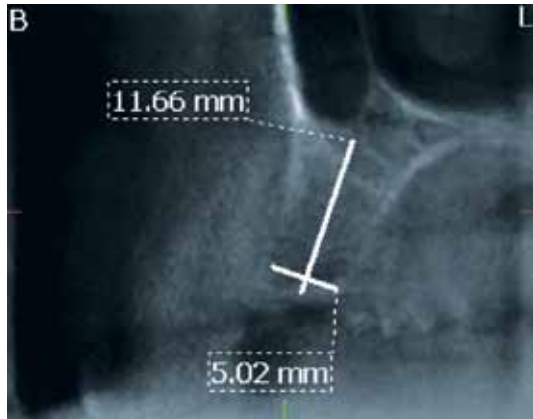
A 70 years old woman already treated with implant supported prostheses in the past, requested a fixed partial denture supported by additional dental implants. Her medical history was significant for hypertension and hyperlipidemia, both controlled by medications. For the past 2 months, she was managed for osteoporosis with oral bisphosphonates (Risedronate), calcium and vitamin D3 supplements. The patient was informed of the possible risks and, after consultation with her physician, she agreed to a drug holiday of 3 months before and 3 months after implant surgery. After careful clinical and radiographic evaluation involving orthopantomogram (Fig. 1) and 3D Volumetric Tomography (Morita Acuitomo, Japan) (Fig. 2, 3, 4), the treatment plan consisted of extraction of the right



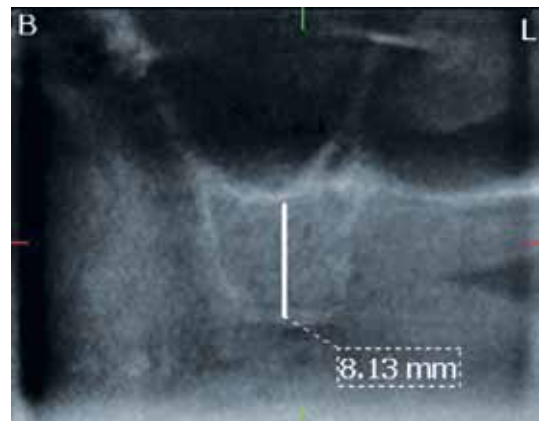
1



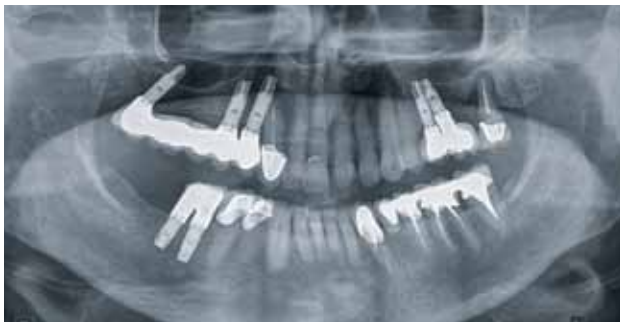2



3



4



5

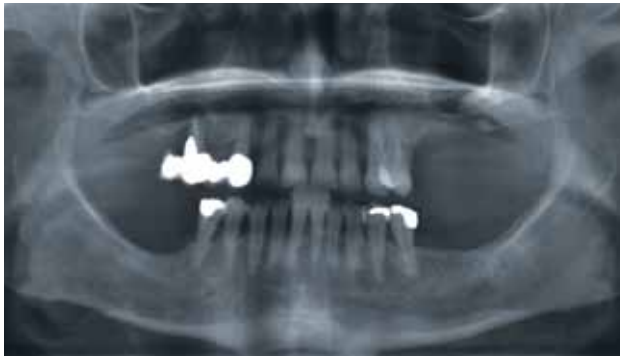FIG. 1 Preoperative panoramic radiograph.
 FIG. 2 Volumetric view of site 14.
 FIG. 3 Volumetric view of site 15.
 FIG. 4 Volumetric view of site 17.
 FIG. 5 Panoramic radiograph two years postoperatively.

maxillary first premolar and first molar because of their poor prognosis and placement of 3 dental implants in the right posterior maxilla (sites 14, 15, 17) (Branemark System Mk III Groovy, Nobel Biocare, Goteborg, Sweden). The patient was under antibiotic coverage (Amoxicillin 500mg three times daily; GlaxoSmithKline, Athens, Greece) that started 24 hours before the surgical intervention and finished ten days postoperatively. The final prosthetic restoration was a fixed metal-ceramic partial denture that was inserted 3 months after implant placement, directly attached on the implants without the application of transmucosal abutments. The treatment plan was completed uneventfully. No complications were noted during a 2-year follow-up period (Fig. 5).

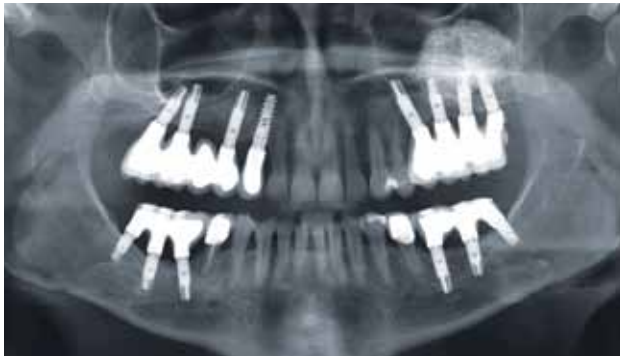Case report 2

A 65 years old woman requested fixed prosthetic restorations supported by dental implants. Her medical

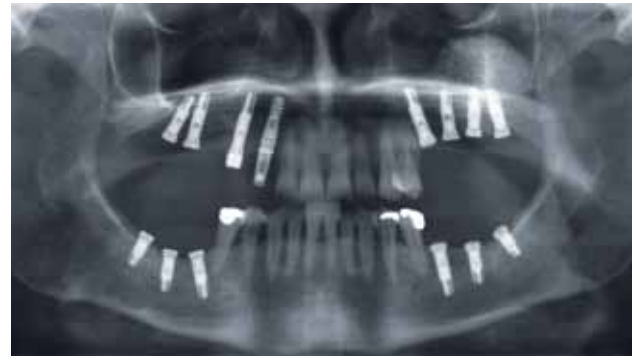history was significant only for osteoporosis, which was managed with oral bisphosphonates (Alendronate) for the past 4 years. The patient was informed of the possible risks and consulted her treating physician concerning the temporary discontinuation of the drug. The physician agreed for a drug holiday of 3 months before and 3 months after surgery to ensure uneventful healing and successful osseointegration of the implants and to minimize the risk of BRONJ. After careful clinical and radiographic examination, including orthopantomogram (Fig. 6) and 3D Volumetric Tomography (Dental scan Newton, Italy) the treatment plan consisted of extraction of the right maxillary canine and second premolar because of their poor prognosis. The first surgical intervention involved all maxillary implants. The placement of 4 dental implants in the right posterior maxilla followed immediately after the extractions (sites 13, 14, 16, 17). The implant on site 13 (SPI, Alpha Bio, Petach Tikva Israel) 16 mm was placed by a flapless approach and was immediately connected to a prefabricated Ti abutment and attained immediate provisionalization and passive immediate loading



6



8



7

FIG. 6 Preoperative panoramic radiograph.

FIG. 7 Panoramic radiograph after the second surgical procedure.

FIG. 8 Panoramic radiograph four years postoperatively.

avoiding any centric or functional occlusal contact. Implants in sites 14, 16 and 17 (Branemark System Mk III Groovy, NobelBiocare, Goteborg, Sweden) 13 mm were applied by the traditional two-stage approach along with closed sinus augmentation through the alveolar crest (Summers' technique) (Fig. 7). The placement of the 4 implants in the left posterior maxilla (sites 25, 26, 27, 28) was accomplished, simultaneously with sinus augmentation via lateral approach (osteotomy window technique) (Fig. 7).

In the second surgical session (one month later) 6 implants were placed in the posterior regions of the mandible (sites 36, 37, 38, 46, 47, 48) by the traditional two-stage approach (Fig. 7). The patient was under antibiotic coverage Amoxicillin 500mg three times daily (GlaxoSmithKline, Athens, Greece) that started 24 hours before each of the surgical interventions and finished 10 days postoperatively.

The final prosthetic restorations were fixed metal-ceramic partial dentures that were inserted 6 months after placement in the maxilla and 3 months after placement in the mandible, directly attached on the implants without the application of a transmucosal abutment. The treatment plan was completed uneventfully. No complications were noted during a 4-year follow-up period (Fig. 8).

DISCUSSION

Bisphosphonates may be administered per os or intravenously (IV) (3,4). Alendronate, Risedronate

and Ibandronate are commonly administered per os for treating osteoporosis, while other drugs (such as Zoledronate and Pamidronate) are administered IV mainly for treating bone malignancies (4). The major difference between per os and IV administered bisphosphonates lies in their bioavailability (0.64% and 60% respectively) (10–12). Bisphosphonates accumulate in the bone matrix and prevent the function of osteoclasts, leading them to apoptosis (13,14). Bone vascularity is decreased and bone remodelling and healing are hindered (2–4,7,15). Bisphosphonates may be detected in the bone even many years after the end of treatment (4, 7, 14, 15).

The frequency of BRONJ is unknown. Various studies on IV administered bisphosphonates report BRONJ rates of 1.9 – 28% with the most common causative factor being dentoalveolar surgery (16–23). As a result, dentoalveolar surgery and placement of dental implants in patients on IV bisphosphonates is generally contraindicated (16–23). As for oral bisphosphonates, BRONJ rates of 0.09–0.34% after tooth extraction have been reported (4). In a large Australian study, the frequency of BRONJ occurring after extractions was estimated at 1 in 296 to 1 in 1,130 extractions in patients taking oral bisphosphonates (24). Marx et al. presented 30 cases of BRONJ in patients taking oral bisphosphonates (90% Alendronate, 10% Risedronate) for more than 3 years (12). Khosla et al. claimed that only a total of 64 cases of BRONJ in patients taking oral bisphosphonates had been reported in the literature until 2007 (25). Consequently, the risk of BRONJ in patients on per os bisphosphonates may be considered low but cannot be ignored (25).

The risk factors for developing BRONJ can be divided into drug-related, local and systemic factors (4). Systemic risk factors include other drugs (chemotherapeutics, corticosteroids), diabetes mellitus, smoking, as well as other conditions (2–4,7,26–28). In the cases presented here, no other systemic factors were identified. On the other hand, local triggering agents include

dentoalveolar surgery (e.g. tooth extraction or dental implant placement) or denture-induced traumatic ulcers, along with poor oral hygiene (2-4,8,12,15,29). In 20-25% of BRONJ cases, no triggering agent can be identified (8,12).

BRONJ commonly presents as an unhealed extraction socket or a poorly healed surgical site (2-4). The mandible is usually affected in 65-70% of the cases (4). In the early stages, BRONJ may be presented as mucosal inflammation without bone exposure (2-4). After a period of time, necrotic bone will be seen in the oral cavity (avascular necrosis) (8,12). BRONJ is usually painless, unless it is infected or there are sharp bone fragments that cause additional trauma in the adjacent mucosa (2-4). During the progression of BRONJ, other signs may appear such as fistula, jaw fractures and excessive osteolysis, even involving the lower border of the mandible (2-4). Ruggiero et al. (4) divide BRONJ into 4 stages.

- ◀ Stage 0, no clinical evidence of necrotic bone, but non-specific clinical findings and symptoms.
- ◀ Stage 1, exposed and necrotic bone in asymptomatic patients without evidence of infection.
- ◀ Stage 2, exposed and necrotic bone associated with infection as evidenced by pain and erythema in region of exposed bone with or without purulent drainage.
- ◀ Stage 3, exposed and necrotic bone in patients with pain, infection, and one or more of the following: exposed and necrotic bone extending beyond the region of alveolar bone, resulting in pathologic fracture, extraoral fistula, oral antral/oral nasal communication, or osteolysis extending to the inferior border of the mandible or the sinus floor.

The AAOMS position paper claims that patients may be considered to have BRONJ if all of the following 3 characteristics are present: current or previous treatment with a bisphosphonate, exposed bone in the maxillofacial region that has persisted for more than 8 weeks, no history of radiation therapy to the jaws (4). Biopsy of the lesion is not routinely recommended, because the histopathologic features are not unique, and the trauma inflicted may worsen the condition (4,9).

Notwithstanding the minimal risk of patients on per os bisphosphonates for developing BRONJ, a thorough examination of the oral cavity is advised (4,12). The decreased risk of developing BRONJ in the first 3 years of therapy gives the dentist the necessary time to treat any site of inflammation (4,12). These patients must have a meticulous oral hygiene and a regular dental follow-up schedule (4,7,8). Patients on per os bisphosphonates may receive any non-surgical dental treatment (4,7,8,15). For individuals who have taken oral bisphosphonates for fewer than 3 years and have no clinical risk factors, any surgical procedure may be performed (4). If the duration of bisphosphonate treatment exceeds a 3 years period

or there are other systemic risk factors (such as chronic corticosteroid use), it is preferable for the patient to be on a drug holiday in order to undergo oral surgery (4,7,8,12,15). If systemic conditions permit, the clinician might consider discontinuation of oral bisphosphonates for a 3-month period before and a 3-month period after surgery to lower the risk of BRONJ and ensure successful healing (4). The surgical intervention should be minimally invasive and performed with antibiotic coverage (7,8,15). If systemic conditions do not permit the drug discontinuation, necessary surgical procedures should be performed after patient's approval (7,8,15). Marx et al. proposed a new method for evaluating the bone remodeling ability by observation of the morning fasting serum C-terminal telopeptide (CTX) (12). This method has not yet been approved by the majority of the scientific community.

If BRONJ develops in a patient receiving per os bisphosphonates, drug discontinuation is advisable for a period of 6-12 months, thus facilitating successful healing or sequestration if the necrosis is small (4,12,15,29). In case of large necrosis, the drug discontinuation may not be enough for successful healing (12). If the exposed bone becomes mobile or shows radiographic evidence of sequestration, then a local debridement can be accomplished after a drug holiday of 6-12 months (12). Apart from the discontinuation of oral bisphosphonates, the following procedures have been proposed by AAOMS, according to the stage of the disease.

- ◀ Stage 0, systemic management, including use of pain medication and antibiotics.
- ◀ Stage 1, antibacterial mouth rinse (chlorhexidine 0,12%).
- ◀ Stage 2, systemic antibiotics, antibacterial mouth rinse, pain control; stage 3, all of the above along with possible surgical debridement / resection (4).

Regardless of disease stage, mobile segments of bony sequestrum, as well as sharp bone fragments, should be removed and symptomatic teeth within exposed, necrotic bone should be extracted (3,4,9). Osteonecrosis may also be covered by a special splint to avoid further trauma (7). Strict follow-up schedule is also advised (every 3 weeks) (2,7).

Newest methods for the treatment of BRONJ include ozone, hyperbaric oxygen and laser therapy (30,31). Ozone and hyperbaric oxygen therapy, both combined with conservative removal of necrotic tissue, may stimulate cell proliferation, soft tissue healing and angiogenesis (30,31). On the other hand, laser applications at low intensity (Low Level Laser Therapy - LLLT) as well as Er:YAG laser have been reported in the literature for the treatment of BRONJ. Laser therapy improves the reparative process, stimulates lymphatic and blood capillaries growth and can be used for conservative removal of necrotic bone (30). Long-term, prospective studies are required to establish the efficacy

of these methods (30,31).

Dental implants have a high rate of success (95% or better) when correctly implanted into the jaws (32). The successful integration and function of an implant involves 3 phases: osteoconduction, osteogenesis, bone remodelling (33). Bisphosphonates significantly reduce bone turnover and as a result they may interfere with integration (34,35). The occurrence of dental implant failure with or without osteonecrosis due to per os bisphosphonates is not known; yet several surveys have indicated that it may be considered rare (6, 35–38).

Leonida et al. reported a 100% success rate without implant loss or BRONJ development in a pilot study of patients on oral bisphosphonates for osteoporosis after immediate loading of dental implants in mandible full arch (39).

Bedogni et al. reported a case of BRONJ after implant placement in patients receiving oral nitrogen-containing bisphosphonates; they highlighted the need to offer a full explanation of the potential risks of BRONJ development and implant failure in patients receiving per os bisphosphonates and stressed the importance of meticulous long-term oral hygiene of implant-prosthetic restorations (40).

A large Australian survey in 16,000 patients who had received dental implants showed that only 7 patients on per os bisphosphonate therapy experienced implant failure or BRONJ and the implant failure rate was calculated 1 in 114 (0.89%) (32). Five of these patients had been on bisphosphonate therapy for 3 years or more (32). In 3 patients one implant failed to integrate, while in 4 patients one or more implants lost their osseointegration and were removed (32).

Madrid et al., 2009, in a systematic review stated that the placement of implants may be considered a safe procedure in patients taking oral bisphosphonates for less than 5 years (41).

In general, it is advised to discontinue the per os bisphosphonate treatment, after consultation with the treating physician and if systemic conditions permit, for at least 3 months before the placement of the implants and until osseointegration is achieved, especially in patients receiving oral bisphosphonates for more than 3 years and/or treated jointly with corticosteroids (4,12,42,43). Serologic bone turnover tests have been proposed, but their clinical value is uncertain, unless more surveys are conducted (32).

Informed consent must be obtained before placing dental implants on patients receiving per os bisphosphonates (4,43). Last but not least, prolonged follow-up is indicated (44).

CONCLUSION

In conclusion, the risk of BRONJ in patients on per os bisphosphonates may be considered minimal but cannot

be ignored (41,45). Dental implants can be placed in these patients as long as they are aware of the possible risks and the necessary precautions are taken.

REFERENCES

1. Marx RE. Pamidronate (Aredia) and zoledronate (Zometa) induced avascular necrosis of the jaws: A growing epidemic. *J Oral Maxillofac Surg* 2003 Sep;61(9):1115-7.
2. Marx RE, Sawatari Y, Fortin M, Broumand V. Bisphosphonate-induced exposed bone (osteonecrosis/osteopetrosis) of the jaws: risk factors, recognition, prevention, and treatment. *J Oral Maxillofac Surg* 2005; 63(11):1567-75.
3. Ruggiero SL, Mehrotra B, Rosenberg TJ, Engroff SL. Osteonecrosis of the jaws associated with the use of bisphosphonates: A review of 63 cases. *J Oral Maxillofac Surg* 2004; 62(5):527-34.
4. Colella G, Campisi G, Fusco V. American Association of Oral and Maxillofacial Surgeons position paper: bisphosphonate-related osteonecrosis of the jaws-2009 update: the need to refine the BRONJ definition. *J Oral Maxillofac Surg* 2009; 67(12):2698-9.
5. Bone HG, Hosking D, Devogelaer JP, Tucci JR, Emkey RD, Tonino RP, Rodriguez-Portales JA, Downs RW, Gupta J, Santora AC, Liberman UA. Alendronate Phase III Osteoporosis Treatment Study Group. Ten years' experience with alendronate for osteoporosis in postmenopausal women. *N Engl J Med* 2004;350(12):1189-99.
6. Grant BT, Amenedo C, Freeman K, Kraut RA. Outcomes of placing dental implants in patients taking oral bisphosphonates: a review of 115 cases. *J Oral Maxillofac Surg* 2008; 66(2):223-30.
7. Migliorati CA, Casiglia J, Epstein J, Jacobsen PL, Siegel MA, Woo SB. Managing the care of patients with bisphosphonate-associated osteonecrosis: an American Academy of Oral Medicine position paper. *JADA* 2005; 136(12):1658-68.
8. Migliorati CA, Schubert MM, Peterson DE, Seneda LM. Bisphosphonate-associated osteonecrosis of mandibular and maxillary bone: an emerging oral complication of supportive cancer therapy. *Cancer* 2005; 104(1):83-93.
9. Ruggiero SL, Fantasia J, Carlson E. Bisphosphonate-related osteonecrosis of the jaw: background and guidelines for diagnosis, staging and management. *Oral Surg Oral Med Oral Pathol Oral Radiol Endod* 2006; 102(4):433-41.
10. Tıraş MB, Noyan V, Yildiz A, Yildirim M, Daya S. Effects of alendronate and hormone replacement therapy, alone or in combination, on bone mass in postmenopausal women with osteoporosis: a prospective, randomized study. *Human Reproduction* 2000; 15(10):2087-92.
11. Lindsay R, Cosman F, Lobo RA, Walsh BW, Harris ST, Reagan JE, Liss CL, Melton ME, Byrnes CA. Addition of alendronate to ongoing hormone replacement therapy in the treatment of osteoporosis: a randomized, controlled clinical trial. *J Clin Endocrinol & Metabolism* 1999; 84(9):3076-81.
12. Marx RE, Cillo JE Jr, Ulloa JJ. Oral bisphosphonate-induced osteonecrosis: risk factors, prediction of risk using serum CTX testing, prevention, and treatment. *J Oral Maxillofac Surg* 2007; 65(12):2397-410.
13. Porras AG, Holland SD, Gertz BJ. Pharmacokinetics of alendronate. *Clin Pharmacokinet* 1999; 36(5):315-28.
14. Lin JH, Russell G, Gertz B. Pharmacokinetics of alendronate: an overview. *Int J Clin Pract Suppl* 1999; 101:18-26.
15. Gutta R, Louis PJ. Bisphosphonates and osteonecrosis of the jaws: science and rationale. *Oral Surg Oral Med Oral Pathol Oral Radiol Endod* 2007; 104(2):186-93.
16. Durie BG, Katz M, Crowley J. Osteonecrosis of the jaw and bisphosphonates. *N Engl J Med* 2005; 353(1):99-102.
17. Bamias A, Kastiris E, Bamia C, Moulopoulos LA, Melakopoulos I, Bozas G, Koutsoukou V, Gika D, Anagnostopoulos A, Papadimitriou C, Terpos E, Dimopoulos MA. Osteonecrosis of the Jaw in Cancer After Treatment With Bisphosphonates: Incidence and Risk Factors. *J Clin Oncol* 2005;23(34):8580-7.

18. Maerevoet M, Martin C, Duck L. Osteonecrosis of the jaw and bisphosphonates. *N Engl J Med* 2005; 353(25):2728.
19. Dimopoulos MA, Kastritis E, Anagnostopoulos A, Melakopoulos I, Gika D, Mouloupoulos LA, Bamia C, Terpos E, Tsionos K, Bamias A. Osteonecrosis of the jaw in patients with multiple myeloma treated with bisphosphonates: evidence of increased risk after treatment with zoledronic acid. *Haematologica* 2006; 91(7):968-71.
20. Tosi P, Zamagni E, Cangini D, Tacchetti P, Di Raimondo F, Catalano L, D'Arco A, Ronconi S, Cellini C, Offidani M, Perrone G, Ceccolini M, Brioli A, Tura S, Baccarani M, Cavo M. Osteonecrosis of the jaws in newly diagnosed multiple myeloma patients treated with zoledronic acid and thalidomide-dexamethasone. *Blood* 2006; 108(12):3951-2.
21. Pozzi S, Marcheselli R, Sacchi S, Baldini L, Angrilli F, Pennese E, Quarta G, Stelitano C, Caparotti G, Luminari S, Musto P, Natale D, Broglio C, Cuoghi A, Dini D, Di Tonno P, Leonardi G, Pianezze G, Pitini V, Polimeno G, Ponchio L, Masini L, Musso M, Spriano M, Pollastri G; Gruppo Italiano Studio Linfomi. Bisphosphonate-associated osteonecrosis of the jaw: a review of 35 cases and an evaluation of its frequency in multiple myeloma patients. *Leuk Lymphoma* 2007; 48(1):56-64.
22. Ibrahim T, Barbanti F, Giorgio-Marrano G, Mercatali L, Ronconi S, Vicini C, Amadori D. Osteonecrosis of the jaw in patients with bone metastases treated with bisphosphonates: a retrospective study. *Oncologist* 2008; 13(3):330-6.
23. Boonyapakorn T, Schirmer I, Reichart PA, Sturm I, Massenkeil G. Bisphosphonate-induced osteonecrosis of the jaws: prospective study of 80 patients with multiple myeloma and other malignancies. *Oral Oncol* 2008; 44(9):857-69.
24. Mavrokki T, Cheng A, Stein B, Goss A. Nature and frequency of bisphosphonate-associated osteonecrosis of the jaws in Australia. *J Oral Maxillofac Surg* 2007 65(3):415-23.
25. Khosla S, Burr D, Cauley J, Dempster DW, Ebeling PR, Felsenberg D, Gagel RF, Gilsanz V, Guise T, Koka S, McCauley LK, McGowan J, McKee MD, Mohla S, Pendrys DG, Raisz LG, Ruggiero SL, Shafer DM, Shum L, Silverman SL, Van Poznak CH, Watts N, Woo SB, Shane E. American Society for Bone and Mineral Research. Bisphosphonate-associated osteonecrosis of the jaw: report of a task force of the American Society for Bone and Mineral Research. *J Bone Miner Res* 2007; 22(10):1479-91.
26. Bagán J, Blade J, Cozar JM, Constela M, García Sanz R, Gómez Veiga F, Lahuerta JJ, Lluch A, Massuti B, Morote J, San Miguel JF, Solsona E. Recommendations for the prevention, diagnosis, and treatment of osteonecrosis of the jaw (ONJ) in cancer patients treated with bisphosphonates. *Med Oral Patol Oral Cir Bucal* 2007; 12(4):E336-40.
27. Badros A, Weikel D, Salama A, Goloubeva O, Schneider A, Rapoport A, Fenton R, Gahres N, Sausville E, Ord R, Meiller T. Osteonecrosis of the jaw in multiple myeloma patients: clinical features and risk factors. *J Clin Oncol* 2006; 24(6):945-52.
28. Wessel JH, Dodson TB, Zavras AI. Zoledronate, smoking, and obesity are strong risk factors for osteonecrosis of the jaw: a case-control study. *J Oral Maxillofac Surg* 2008; 66(4):625-31.
29. Brooks JK, Gilson AJ, Sindler AJ, Ashman SG, Schwartz KG, Nikitakis NG. Osteonecrosis of the jaws associated with use of risedronate: report of 2 new cases. *Oral Surg Oral Med Oral Pathol Oral Radiol Endod* 2007; 103(6):780-6.
30. Vescovi P, Nammour S. Bisphosphonate-Related Osteonecrosis of the Jaw (BRONJ) therapy. A critical review. *Minerva Stomatol* 2010; 59(4):181-203, 204-13.
31. Chiu CT, Chiang WF, Chuang CY, Chang SW. Resolution of oral bisphosphonate and steroid-related osteonecrosis of the jaw--a serial case analysis. *J Oral Maxillofac Surg* 2010; 68(5):1055-63.
32. Goss A, Bartold M, Sambrook P, Hawker P. The nature and frequency of bisphosphonate-associated osteonecrosis of the jaws in dental implant patients: a South Australian case series. *J Oral Maxillofac Surg* 2010; 68(2):337-43.
33. Davies JE. Understanding peri-implant endosseous healing. *J Dent Educ* 2003; 67(8):932-49.
34. Javed F, Almas K. Osseointegration of dental implants in patients undergoing bisphosphonate treatment: a literature review. *J Periodontol* 2010; 81(4):479-84.
35. Starck WJ, Epker BN. Failure of osseointegrated dental implants after diphosphonate therapy for osteoporosis: a case report. *Int J Oral Maxillofac Implants* 1995;10(1):74-8.
36. Fugazzoto PA, Lightfoot WS, Jaffin R, Kumar A. Implant placement with or without simultaneous tooth extraction in patients taking oral bisphosphonates: postoperative healing, early follow-up, and the incidence of complications in two private practices. *J Periodontol* 2007; 78:1664-9.
37. Wang HL, Weber D, McCauley LK. Effect of long-term oral bisphosphonates on implant wound healing: literature review and a case report. *J Periodontol* 2007; 78(3):584-94.
38. Shin EY, Kwon YH, Herr Y, Shin SI, Chung JH. Implant failure associated with oral bisphosphonate-related osteonecrosis of the jaw. *J Periodontol Implant Sci* 2010; 40(2):90-5.
39. Leonida A, Vescovi P, Baldoni M, Rossi G, Lauritano D. Immediate loading of dental implants in mandible full-arch: pilot study in patients with osteoporosis treated with bisphosphonates therapy. *J Oral Implantol*. 2010 Jun 16. doi.org/10.1563/AAID-JOI-D-09-00132.1
40. Bedogni A, Bettini G, Totola A, Saia G, Nocini PF. Oral bisphosphonate-associated osteonecrosis of the jaw after implant surgery: a case report and literature review. *Oral Maxillofac Surg* 2010; 68(7):1662-6.
41. Madrid C, Sanz M. What impact do systemically administered bisphosphonates have on oral implant therapy? A systematic review. *Clin Oral Implants Res* 2009; 20 Suppl 4:87-95.
42. Scully C, Madrid C, Bagan J. Dental endosseous implants in patients on bisphosphonate therapy. *Implant Dent* 2006;15(3):212-8.
43. Flichy-Fernández AJ, Balaguer-Martínez J, Peñarocha-Diago M, Bagán JV. Bisphosphonates and dental implants: current problems. *Med Oral Patol Oral Cir Bucal*. 2009; 14(7):E355-60.
44. Lazarovici TS, Yahalom R, Taicher S, Schwartz-Arad D, Peleg O, Yarom N. Bisphosphonate-related osteonecrosis of the jaw associated with dental implants. *J Oral Maxillofac Surg* 2010; 68(4):790-6.
45. Goiato MC, dos Santos DM, Rondon BC, Moreno A, Baptista GT, Verri FR, Dekon SF. Care required when using bisphosphonates in dental surgical practice. *J Craniofac Surg* 2010; 21(6):1966-70.