

# Crestal approach for the repair of the Schneiderian membrane perforated during transalveolar sinus elevation

> **B.A. LEE<sup>1</sup>, S.B. LEE<sup>2</sup>, Y.T. KIM<sup>1</sup>**

Department of Periodontology, National Health Insurance Service Ilsan Hospital, Goyang, Korea

<sup>1</sup>DDS, PhD

<sup>2</sup>DDS

## TO CITE THIS ARTICLE

Lee BA, Lee SB, Kim YT. Crestal approach for the repair of the Schneiderian membrane perforated during transalveolar sinus elevation. *J Osseointegr* 2021;13(3):150-155.

DOI 10.23805 /JO.2021.13.03.8

## ABSTRACT

**Aim** The most common complication during maxillary sinus floor elevation is perforation of the Schneiderian membrane. Most of studies presented repair procedures via a lateral approach, which can induce additional complications. Therefore, in the present study the procedure was performed via crestal approach.

**Case report** This study included three patients who showed a low residual alveolar bone height in the maxillary posterior edentulous region and in whom the placement of implants with sinus floor elevation was planned via a transalveolar approach. Perforation of the sinus membrane occurred during the procedure, and so collagen dressing material was inserted through the drilling hole to cover the perforated membrane. Xenogeneic bone was grafted under the elevated sinus membrane, and implants were placed simultaneously. The final prostheses were delivered at 6 to 8 months after the surgery. There were no complications in any of the patients.

**Results** All implants showed successful stability, and no specific clinical or radiographic complication was observed during follow-ups lasting 2 to 3 years.

**Conclusion** A crestal approach can be a reliable option when repairing a sinus membrane that is perforated during transalveolar sinus floor elevation.

**KEYWORDS** Dental implant; Sinus lift; Resorbable collagen membrane; Perforation; Schneiderian membrane.

## INTRODUCTION

Maxillary sinus floor elevation (SFE) is used to augment insufficient alveolar bone when placing dental implants in

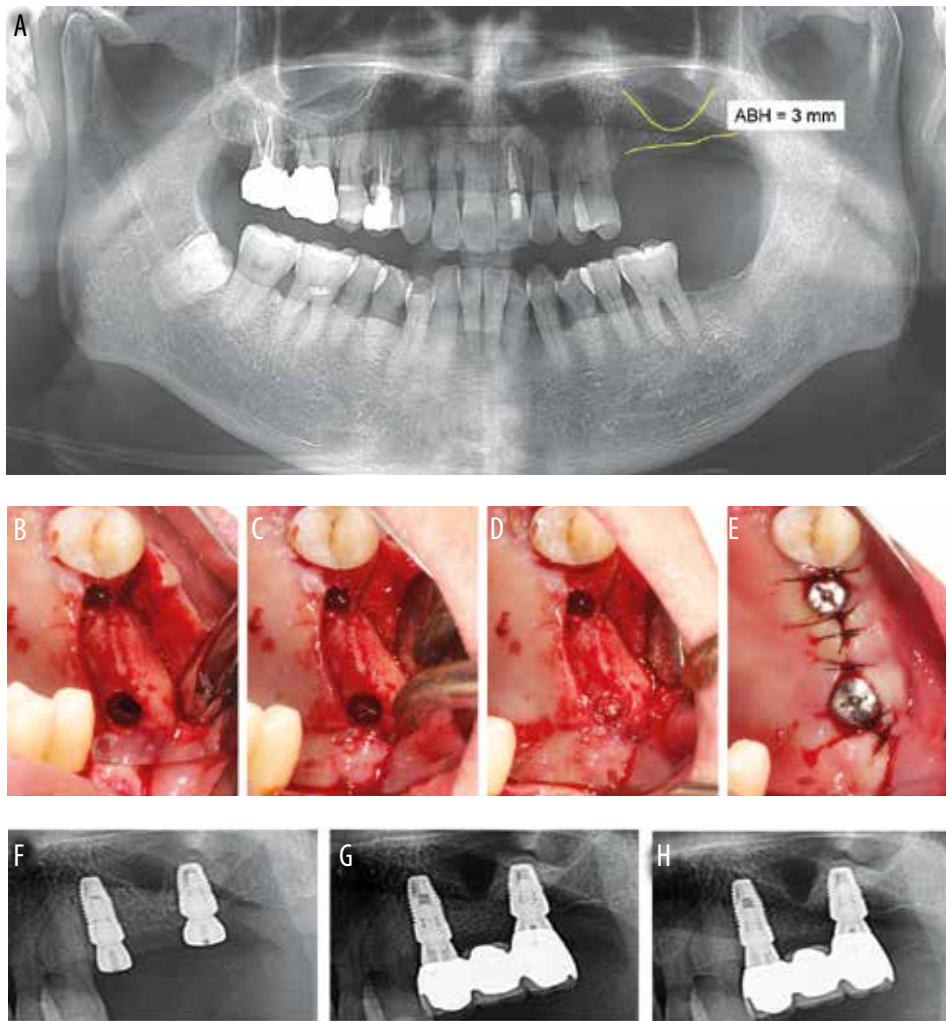
the maxillary posterior region, and can be accomplished via a transalveolar approach (1) or a lateral approach (2). The transalveolar approach is less invasive than the lateral approach, but less augmentation is achievable in the former (3). One of the transalveolar techniques is osteotome sinus floor elevation (OSFE), in which an osteotome is inserted to fracture the cortical bone of the sinus floor and elevate the Schneiderian membrane (1). This can be accompanied with bone grafting (4). The method of bone-added osteotome sinus floor elevation can simplify the elevation of the sinus floor and reduce the rate of membrane perforation (4).

Zitzmann and Schärer recommended using the osteotome technique with simultaneous implant placement when the residual bone height exceeds 6 mm (5). When the residual bone height is less than 4 mm, staged implant placement after a lateral approach for SFE is recommended. The survival rate of implants placed simultaneously with SFE has been reported to be 95% to 98% (6–8).

The most-common complication during SFE is perforation of the Schneiderian membrane (8,9), with a reported prevalence of 8–32% (10–12). The risk factors include the presence of sinus septa, low residual bone height, and smoking (12). Some studies have found that membrane perforation increased the prevalence of sinusitis (12,13).

It has been reported that survival rates do not differ significantly between implants placed under perforated and intact Schneiderian membranes (11), whereas there are also some studies reporting a relationship between membrane perforation and graft failures or implant failures (13,14). It is thought that the displacement of a graft material into the sinus may be responsible for complications such as maxillary sinusitis after sinus perforation (10). Therefore, various methods aimed at repairing the perforated membrane have been reported, including suturing (15) and the use of fibrin adhesive (15) and absorbable collagen membrane (16). However, most of these studies presented repair procedures via a lateral approach for SFE.

There are few reports on repairing the Schneiderian membrane that has been perforated during transalveolar SFE. Tavelli et al. suggested that only small perforations (with a diameter <2 mm) can be repaired by applying a



**FIG. 1** Case 1 (58-year-old female patient).

A: Preoperative panoramic radiograph showing low available bone height in the maxillary left posterior region. B: Perforation of the sinus membrane during maxillary sinus floor elevation (SFE).

C: Absorbable collagen dressing material was applied via a crestal approach to cover the perforation. D: Bone graft material was inserted.

E: Implants were placed and suturing was performed.

F: Postoperative radiograph showing dome-shaped augmented bone around the fixture. ù

G: A fixed partial denture was applied 6 months later.

H: There were no complications during the 3-year follow-up.

cushion material over the perforation after elevating the remaining membrane via a crestal approach (17). They also recommended avoiding additional bone grafting. A large perforation can be repaired via a lateral sinus window (16,17). The lateral approach for repairing a membrane perforation requires an additional incision, the elevation of a large flap, and additional antrostomy, which increase morbidity. A lateral approach for SFE is reported to be associated with a higher pain level and greater incidence of swelling, bruising, and bleeding than a transalveolar approach (18).

The aim of this case report is to present three cases in which the Schneiderian membrane, that was perforated during transalveolar SFE, was repaired via a crestal approach and implants were simultaneously placed with additional bone grafting.

## CASE REPORT

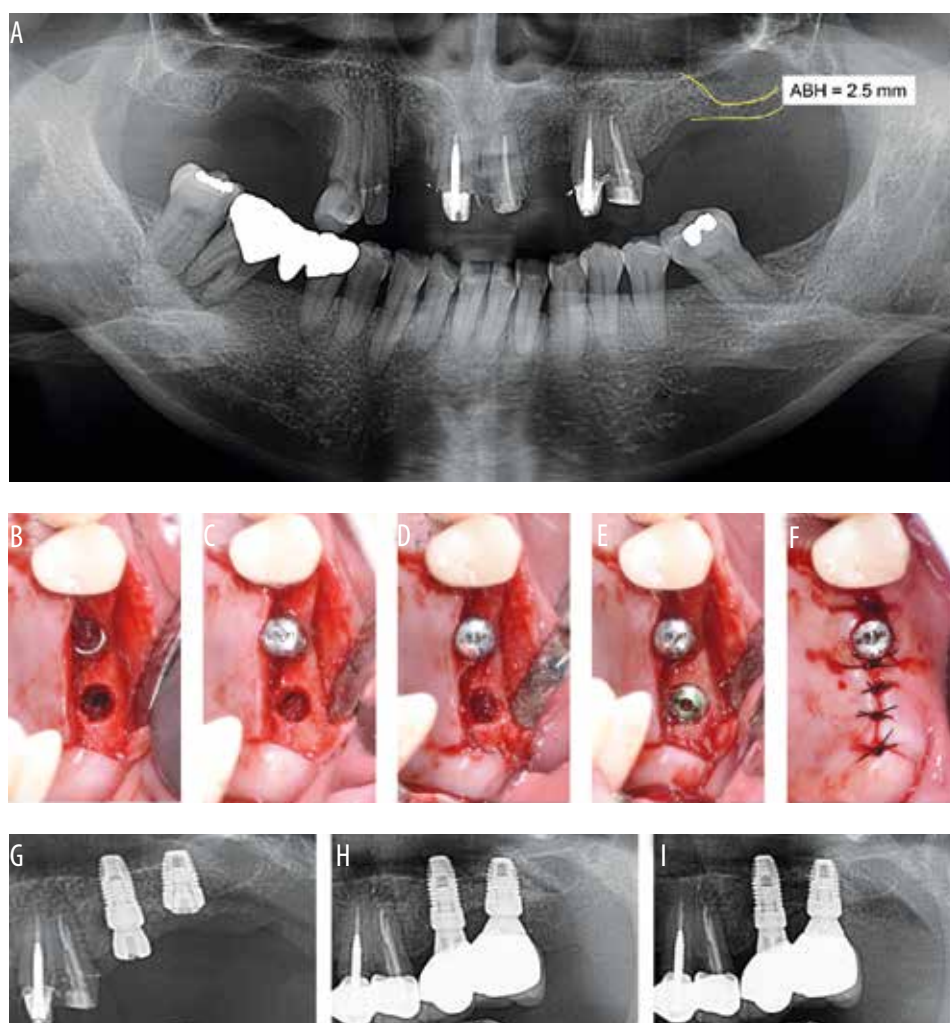
This study involved three patients who showed low residual alveolar bone height in the maxillary posterior edentulous region and the placement of implants with

transalveolar SFE was planned. Perforation of the Schneiderian membrane occurred during the procedure. The intact part of the membrane was detached from the sinus floor and elevated gently. Collagen dressing material was inserted through the drilling hole to cover the perforated membrane. Xenogeneic bone was grafted under the repaired membrane, and implants were placed simultaneously.

### Case 1

A 58-year-old female patient visited the clinic with the chief complaint of a mobile fixed partial denture in the maxillary left posterior region. Clinical and radiographic examinations revealed vertical root fracture of the maxillary left second premolar and secondary caries in the maxillary left second molar. The maxillary left first molar was pontic. The teeth were extracted and implant placement at the site of the second premolar and second molar was planned.

Implant placement was performed 5 months after extraction. The available bone height at the second molar was 3 mm (Fig. 1a), and transalveolar SFE was planned. Prophylactic antibiotics was administered before the



**FIG. 2** CASE 2 (52-year-old female patient).

A: Preoperative panoramic radiograph showing low available bone height in the maxillary left posterior region.

B: Perforation of the sinus membrane was detected during maxillary SFE.

C: Absorbable collagen dressing material was applied via a crestal approach to cover the perforation.

D: Bone graft material was inserted.

E: Implants were placed.

F: Suturing was performed. G: Postoperative radiograph showing augmented bone around the fixture.

H: Splinted crowns were applied 8 months later.

I: There were no complications during the 3-year follow-up.

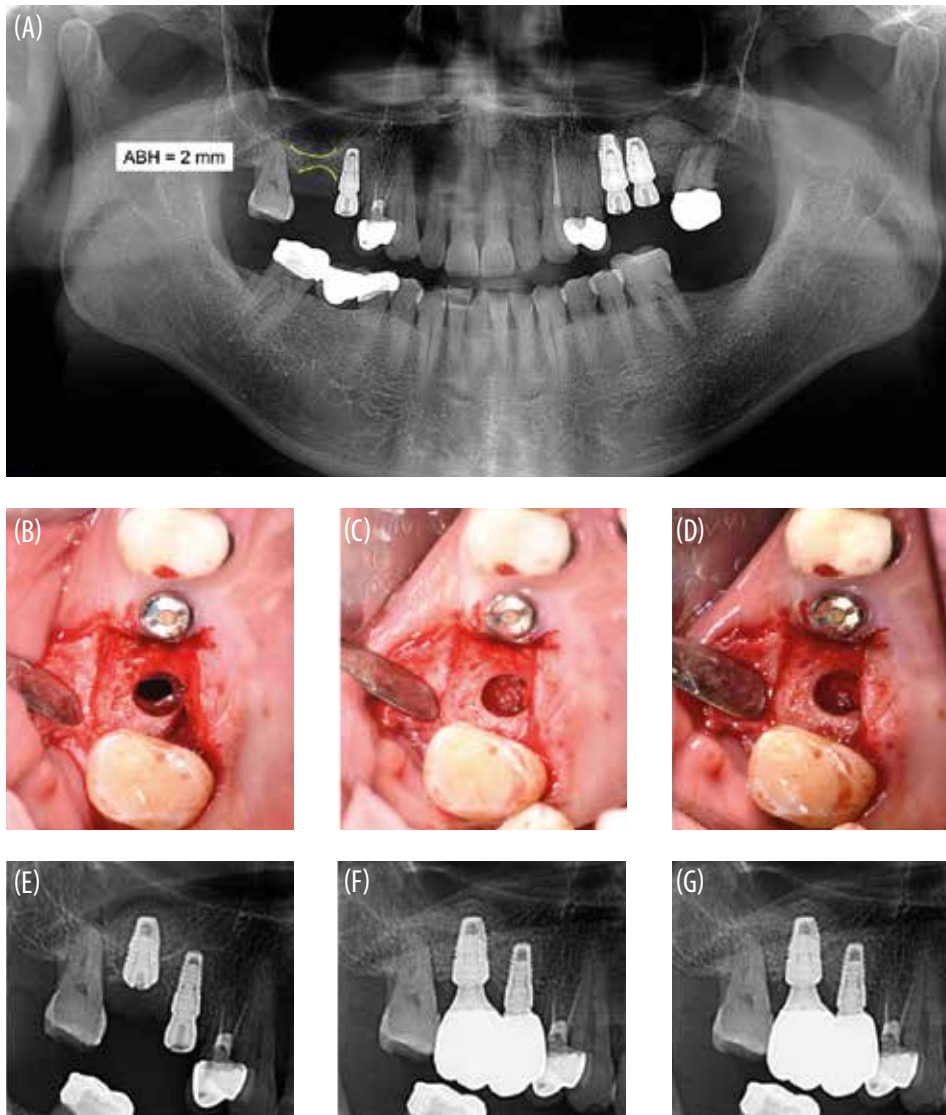
procedure. Local anesthesia using 2% lidocaine with 1:80,000 epinephrine was administered. Crestal and vertical incisions were made, and a full-thickness flap was elevated. Sequential drilling was performed remaining on the cortical bone of sinus floor and an osteotome was applied. Perforation of the Schneiderian membrane with a diameter of 2.5 mm was detected (Fig. 1b). The intact part of membrane was gently detached from the sinus floor, and an absorbable collagen dressing material (CollaTape®, Zimmer Dental, Mississauga, ON, Canada) was applied via a crestal approach to cover the perforation (Fig. 1c). Xenogeneic particulated bone (Bio-oss®, Geistlich Pharma, Wolhusen, Switzerland) was grafted under the elevated sinus membrane (Fig. 1d). Fixtures with sizes of 4.3 mm × 10 mm and 4.8 mm × 8 mm (Implantium®, Dentium, Seoul, Korea) were placed at the level of the second premolar and second molar, respectively. The final torque was 20 Ncm, and healing abutments were connected (Fig. 1e). A postoperative radiograph showed dome-shaped augmented bone without leakage (Fig. 1f). The bone height was 9.5 mm. Antibiotics and non-steroidal anti-inflammatory drugs (NSAIDs) were administered for 7 days, and there were

no complications such as maxillary sinusitis.

The implants showed sufficient stability after 6 months, and so a prosthesis was applied. A radiograph showed a slight reduction of the bone height to 9.1 mm (Fig. 1g). The augmented bone was well maintained without any complications, and the alveolar bone height was 9.0 mm on a radiograph taken at the 3-year follow-up (Fig. 1h).

### Case 2

A 52-year-old female patient visited the clinic for rehabilitation of the maxillary left second premolar and first molar, which had been extracted several years previously. The available bone height was 9 mm at the first molar and 2.5 mm at the second molar (Fig. 2a), and so transalveolar SFE was planned. Prophylactic antibiotic was administered before the procedure. Perforation of the Schneiderian membrane with a diameter of 2 mm was detected during the procedure (Fig. 2b). The intact part of the membrane was gently detached from the sinus floor, and an absorbable collagen dressing material (CollaTape®, Zimmer Dental) was applied via a crestal approach to cover the perforation (Fig. 2c). Xenogenic particulated bone (Bio-oss®, Geistlich Pharma) was



**FIG. 3** Case 3 (59-year-old male patient).

A: Preoperative panoramic radiograph showing low available bone height in the maxillary right posterior region.

B: Perforation of the sinus membrane was detected during maxillary SFE.

C: Absorbable collagen dressing material was applied via a crestal approach to cover the perforation.

D: Bone graft material was inserted.

E: Postoperative radiograph showing dome-shaped augmented bone around the fixture.

F: Prostheses were applied 8 months later.

G: There were no complications during the 2-year follow-up.

grafted under the elevated sinus membrane (Fig. 2d). Fixtures with sizes of 4.3 mm × 10 mm and 4.8 mm × 8 mm (Implantium®, Dentium) were placed at the second premolar and first molar, respectively. The final torque was 40 Ncm, and healing abutments were connected to the second premolar; however, the implant at the first molar was submerged due to the inadequate residual bone (Fig. 2e, 2f). A postoperative radiograph showed dome-shaped augmented bone (Fig. 2g). The bone height was 10 mm. Antibiotics and NSAIDs were administered for 7 days. Infection of graft material was not detected and the patient presented no complications. The second surgery was performed after 5 months, during which a healing abutment was applied at the first molar. The implants showed sufficient stability 3 months later, and a prosthesis was applied. A radiograph showed a slight reduction of the bone height to 9.5 mm (Fig. 2h). The augmented bone was well maintained without any complications, and the alveolar bone height was 9.4 mm on a radiograph taken at the 3-year follow-up (Fig. 2i).

### Case 3

A 59-year-old male patient visited the clinic for implantation at the maxillary right first molar. Implants had previously been placed at the maxillary left second premolar, left first molar, and right second premolar. The available bone height was 2 mm (Fig. 3a), and so transalveolar SFE was planned. Prophylactic antibiotics was administered before the procedure. Perforation of the Schneiderian membrane with a diameter of 3 mm was detected during the procedure (Fig. 3b). The intact part of membrane was gently detached from the sinus floor, and an absorbable collagen dressing material (CollaTape®, Zimmer Dental) was applied via a crestal approach to cover the perforation (Fig. 3c). Xenogeneic particulate bone (The Graft®, Purgo, Seongnam, Korea) was grafted under the elevated sinus membrane (Fig. 3d). A fixture with a size of 4.8 mm × 8 mm (Implantium®, Dentium) was placed at the first molar. The final torque was 40 Ncm, and the implant was submerged. A postoperative radiograph showed dome-shaped augmented bone without leakage

(Fig. 3e). The bone height was 10.4 mm. Antibiotics and NSAIDs were administered for 7 days, and there were no complications.

The second surgery was performed after 5 months, during which a healing abutment was applied at the first molar. The implants showed sufficient stability, and a prosthesis was applied 3.5 months later. A radiograph showed a slight reduction of the bone height to 10 mm (Fig. 3f). The augmented bone was well maintained without any complications, and the alveolar bone height was 10 mm on the radiograph taken at the 2-year follow-up (Fig. 3g).

## DISCUSSION

Membrane perforation is the most common complication of the SFE procedure (8), and is usually repaired via a lateral approach (16). However, when perforation occurs during OSFE, the lateral approach requires a second operation site and increases patient discomfort. In the present three cases, the sinus membrane that was perforated during transalveolar SFE was repaired via an already prepared hole, which resulted in no postoperative complications including swelling, bruising, or maxillary sinusitis.

The prevalence of maxillary sinusitis after SFE has been reported to be 8.4–9.8% (12,19), with the incidence rate of sinusitis being lower for a crestal approach than for a lateral approach (19). Membrane perforation is a risk factor for postoperative sinusitis (12), which decreases the survival rates of implants (19). In the present study, postoperative medication including antibiotics and NSAIDs were administered and patients were instructed not to blow their nose and to sneeze with the mouth open in order to prevent the occurrence of maxillary sinusitis. CollaTape® was used in this study to repair the perforated membrane. The use of resorbable collagen membrane is reportedly a reliable technique for repairing membrane perforations (20). CollaTape® is an absorbable collagen dressing material that is absorbed within 10–14 days (21), and so it was expected not to interrupt the healing process of the Schneiderian membrane. CollaTape® has been used for socket preservation, and Moustafa et al. reported that this material can enhance bone formation and improve the quality of the formed bone (22). In addition, it is hydrophilic and chemotactic for fibroblasts, and so it can adhere to the Schneiderian membrane. CollaTape® is also pliable, making it easy to insert into drilling holes and adapt to a perforation.

After repairing the perforated membrane, xenogeneic particulate bone was grafted under the elevated sinus membrane. Postoperative radiographs revealed that there was no displacement of graft materials into the sinus. Although a previous study recommended avoiding additional bone grafting (17), the present study found that additional bone grafting did not fail if leakage of the graft materials was prevented. The perforations in this case report had sizes of 2 to 3 mm, and a hole with a

diameter of 4.8 mm was prepared for implant placement. This means that the collagen dressing material inserted via the hole could cover the perforation completely, and the graft materials were well maintained under the repaired membrane.

A previous meta-analysis suggested that small perforations with sizes of 1–3 mm allow simultaneous implant placement with the repair of the perforated membrane using an absorbable membrane (23). In the present study, implants placed under a repaired membrane showed good initial stability, and no complications were reported over follow-ups lasting 2–3 years. Ardekian et al. also reported that membrane perforation did not affect the success rate of the implants (11). Hernández-Alfaro et al. suggested that the leakage of graft material may be responsible for implant failures after sinus perforation (10). These observations together indicate that implants show high survival and success rates if the graft material is well maintained.

The residual bone height was 2 to 3 mm and the mean change in the bone height after SFE was 7.5 mm in this study. Previous studies found mean bone gains after transalveolar SFE of 2.5–5.7 mm, while the lateral approach has been reported to augment the alveolar bone by 10–12 mm (5,24,25). Therefore, a transalveolar SFE approach has been recommended for single teeth with a residual bone height of 5–8 mm, while lateral SFE is recommended when <5 mm of bone is available (25,26). In contrast, other studies have shown high success rates of implants placed with transalveolar SFE using certain instruments when the residual bone height is insufficient (27–29). The main factor limiting the residual bone height in transalveolar SFE might be membrane perforation. However, the present study showed that a transalveolar SFE and simultaneous implant placement can be successfully performed even at sites with a residual bone height of 2–3 mm, although membrane perforation has occurred. The prognosis of implants appears to be affected more by the primary stability than by the residual bone height.

The results obtained in this study indicate that a crestal approach can be a reliable option for repairing a sinus membrane that is perforated during transalveolar SFE. Despite the presence of undesirable events, transalveolar SFE can be a successful treatment.

## Funding

This research received no external funding.

## Conflict of interest

The authors declare no conflict of interest.

## REFERENCES

1. Summers RB. A new concept in maxillary implant surgery: the osteotome technique. *Compendium* 1994;15:152, 154–156, 158 passim; quiz 162.
2. Boyne PJ, James RA. Grafting of the maxillary sinus floor with autogenous

- marrow and bone. *J Oral Surg* 1980;38:613–616.
3. Woo I, Le BT. Maxillary sinus floor elevation: review of anatomy and two techniques. *Implant Dent* 2004;13:28–32.
  4. Summers RB. The osteotome technique: part 3--less invasive methods of elevating the sinus floor. *Compendium* 1994;15:698, 700, 702–694 passim; quiz 710.
  5. Zitzmann NU, Schärer P. Sinus elevation procedures in the resorbed posterior maxilla. Comparison of the crestal and lateral approaches. *Oral Surg Oral Med Oral Pathol Oral Radiol Endod* 1998;85:8–17.
  6. Duan DH, Fu JH, Qi W, Du Y, Pan J, Wang HL. Graft-free maxillary sinus floor elevation: a systematic review and meta-analysis. *J Periodontol* 2017;88:550–564.
  7. Pjetursson BE, Tan WC, Zwahlen M, Lang NP. A systematic review of the success of sinus floor elevation and survival of implants inserted in combination with sinus floor elevation. *J Clin Periodontol* 2008;35:216–240.
  8. Călin C, Petre A, Drafta S. Osteotome-mediated sinus floor elevation: a systematic review and meta-analysis. *Int J Oral Maxillofac Implants* 2014;29:558–576.
  9. Stacchi C, Andolsek F, Berton F, Perinetti G, Navarra CO, Di Lenarda R. Intraoperative complications during sinus floor elevation with lateral approach: a systematic review. *Int J Oral Maxillofac Implants* 2017;32:e107–e118.
  10. Hernández-Alfaro F, Torradeflot MM, Marti C. Prevalence and management of Schneiderian membrane perforations during sinus-lift procedures. *Clin Oral Implants Res* 2008;19:91–98.
  11. Ardekian L, Oved-Peleg E, Mactei EE, Peled M. The clinical significance of sinus membrane perforation during augmentation of the maxillary sinus. *J Oral Maxillofac Surg* 2006;64:277–282.
  12. Schwarz L, Schiebel V, Hof M, Ulm C, Watzek G, Pommer B. Risk factors of membrane perforation and postoperative complications in sinus floor elevation surgery: review of 407 augmentation procedures. *J Oral Maxillofac Surg* 2015;73:1275–1282.
  13. Nolan PJ, Freeman K, Kraut RA. Correlation between Schneiderian membrane perforation and sinus lift graft outcome: a retrospective evaluation of 359 augmented sinus. *J Oral Maxillofac Surg* 2014;72:47–52.
  14. Al-Moraissi E, Elsharkawy A, Abotaleb B, Alkebsi K, Al-Motwakel H. Does intraoperative perforation of Schneiderian membrane during sinus lift surgery causes an increased the risk of implants failure?: A systematic review and meta regression analysis. *Clin Implant Dent Relat Res* 2018;20:882–889.
  15. Schwartz-Arad D, Herzberg R, Dolev E. The prevalence of surgical complications of the sinus graft procedure and their impact on implant survival. *J Periodontol* 2004;75:511–516.
  16. Vlassis JM, Fugazzotto PA. A classification system for sinus membrane perforations during augmentation procedures with options for repair. *J Periodontol* 1999;70:692–699.
  17. Tavelli L, Borgonovo AE, Saleh MH, Ravidà A, Chan HL, Wang HL. Classification of sinus membrane perforations occurring during transcresal sinus floor elevation and related treatment. *Int J Periodontics Restorative Dent* 2020;40:111–118.
  18. Farina R, Franceschetti G, Travaglini D, Consolo U, Minenna L, Schincaglia GP, et al. Morbidity following transcresal and lateral sinus floor elevation: a randomized trial. *J Clin Periodontol* 2018;45:1128–1139.
  19. Kim YK, Hwang JY, Yun PY. Relationship between prognosis of dental implants and maxillary sinusitis associated with the sinus elevation procedure. *Int J Oral Maxillofac Implants* 2013;28:178–183.
  20. Kim GS, Lee JW, Chong JH, Han JJ, Jung S, Kook MS, et al. Evaluation of clinical outcomes of implants placed into the maxillary sinus with a perforated sinus membrane: a retrospective study. *Maxillofac Plast Reconstr Surg* 2016;38:50.
  21. Almazrooa SA, Noonan V, Woo SB. Resorbable collagen membranes: histopathologic features. *Oral Surg Oral Med Oral Pathol Oral Radiol* 2014;118:236–240.
  22. Moustafa H, Omar S, Osman S, Kawana K. Effect of Collatape® collagen wound dressing alone and combined with Ingenios® synthetic bone graft on the socket healing in rabbits. *Alex Dent J* 2015;40:27–32.
  23. Al-Dajani M. Incidence, risk factors, and complications of Schneiderian membrane perforation in sinus lift surgery: a meta-analysis. *Implant Dent* 2016;25:409–415.
  24. Bae OY, Kim YS, Shin SY, Kim WK, Lee YK, Kim SH. Clinical outcomes of reamer- vs osteotome-mediated sinus floor elevation with simultaneous implant placement: a 2-year retrospective study. *Int J Oral Maxillofac Implants* 2015;30:925–930.
  25. Pjetursson BE, Lang NP. Sinus floor elevation utilizing the transalveolar approach. *Periodontol* 2000 2014;66:59–71.
  26. Lundgren S, Cricchio G, Hallman M, Jungner M, Rasmusson L, Sennerby L. Sinus floor elevation procedures to enable implant placement and integration: techniques, biological aspects and clinical outcomes. *Periodontol* 2000 2017;73:103–120.
  27. Gonzalez S, Tuan MC, Ahn KM, Nowzari H. Crestal approach for maxillary sinus augmentation in patients with  $\leq 4$  mm of residual alveolar bone. *Clin Implant Dent Relat Res* 2014;16:827–835.
  28. Bernardello F, Righi D, Cosci F, Bozzoli P, Soardi CM, Spinato S. Crestal sinus lift with sequential drills and simultaneous implant placement in sites with  $<5$  mm of native bone: a multicenter retrospective study. *Implant Dent* 2011;20:439–444.
  29. Jang JW, Chang HY, Pi SH, Kim YS, You HK. Alveolar crestal approach for maxillary sinus membrane elevation with  $<4$  mm of residual bone height: a case report. *Int J Dent* 2018;2018:1063459.