

➤ **ARTHUR B. NOVAES JR**¹, **PATRICIA GARANI FERNANDES**², **FLÁVIA ADELINO SUAID**², **MARCIO FERNANDO DE MORAES GRISI**³, **SERGIO LUIS SCOMBATTI DE SOUZA**³, **MARIO TABA JR.**³, **DANIELA BAZAN PALIOTO**³, **VALDIR ANTONIO MUGLIA**⁴

¹ DDS, MSc, PhD, Chairman of Periodontology - Ribeirão Preto School of Dentistry, University of São Paulo.

² DDS, MSc, Graduate Students of Department of Oral Surgery and Periodontology - Ribeirão Preto School of Dentistry, University of São Paulo.

³ DDS, MSc, PhD, Associate Professor of Department of Oral Surgery and Periodontology - Ribeirão Preto School of Dentistry, University of São Paulo.

⁴ DDS, MSc, PhD, Professor of Department of Dental Materials and Prosthodontics- Ribeirão Preto School of Dentistry, University of São Paulo.

Ridge preservation with acellular dermal matrix and anorganic bone matrix cell-binding peptide P-15 after tooth extraction in humans. A histologic and morphometric study

TO CITE THIS ARTICLE

Novaes AB Jr, Fernandes PG, Suaid FA, de Moraes Grisi MF, Scombatti de Souza SL, Taba M Jr, Palioto DB, Muglia VA. Ridge preservation with acellular dermal matrix and anorganic bone matrix cell-binding peptide P-15 after tooth extraction in humans. A histomorphometric study. *J Osseointegr* 2012;2(4):23-30.

ABSTRACT

Aim The aim of this study was to analyze by histomorphometric parameters the use of acellular dermal matrix (ADM) with or without anorganic bovine bone matrix (ABM) / synthetic cell-binding peptide P-15 in the formation of bone in human alveoli.

Materials and methods Eighteen patients in need of extraction of maxillary anterior teeth were selected and randomly assigned to the test group (ADM plus ABM/P-15) or the control group (ADM only). Histomorphometric measurements and histological analysis were recorded about 6 months after ridge preservation procedures in ten patients. The amount of newly formed bone, the most recently formed bone, fibrous tissue plus marrow spaces and remaining graft particles were measured and analyzed.

Results At 6 months, the new bone area parameter and the percentage of fibrous tissue plus marrow space areas showed higher values to the control group, and statistically significant differences when compared with the test group ($p=0.03$).

Conclusion The ADM acted as a membrane. The association of ABM/P-15 with ADM resulted in new bone formation within the alveoli, but the results were not considered relevant when used in this indication.

KEY WORDS Biocompatible materials; bone regeneration; bone grafting; socket graft; tooth extraction

INTRODUCTION

Alveolar bone resorption after tooth extraction is

an inherent condition of the healing process. It is accelerated at the first 6 months after extraction and followed by a gradual remodeling that includes changes in size and shape, with loss of approximately 40% in height and 60% in width (1-3). The reduction in height and width of the alveolar ridge is progressive and irreversible and it can make implant placement difficult, especially in the anterior maxilla, where bone volume is important for functional and esthetic reasons (4). Early extraction socket healing is expected to decrease the alveolar ridge by 2 to 4 mm horizontally and 1 mm vertically. These changes are time dependent, by the end of the first year post extraction nearly 6 mm of buccal bone loss can be expected (5-7).

The general understanding is that bone graft placement in the extraction socket should offset the catabolic processes observed within the crestal ridge. Therefore, several procedures, such as the use of bone autografts, bone replacement materials, and regenerative techniques, have been proposed to prevent and correct alveolar bone resorption. Guided bone regeneration (GBR) is based on the principle of selecting cells using membranes to prevent epithelial proliferation (8). Conventionally, non-resorbable and resorbable membranes are used in GBR techniques. More recently, some studies have shown the possibility of using acellular dermal matrix (ADM) as a biologic membrane in GBR (9-12).

ADM is allogeneic human skin obtained from tissue banks. It is processed by removing of the epidermis and all dermal cells; however, the complex basement membrane and the structure of collagen and elastin are preserved (13). In this context, there is a structural biocompatibility as a scaffold for the incorporation and migration of epithelial cells, keratinocytes, and fibroblasts, which will be incorporated into this material (8,13). In addition, ADM has been used in periodontal regenerative procedures, not only because of its biocompatibility but also because of its ability to increase the keratinized tissue for root coverage, be used as membrane in the GBR, and to eliminate gingival

melanin pigmentation (14-16). The use of ADM for the ridge preservation after tooth extraction has been demonstrated by successful clinical reports (10,12,15,17). Moreover, some studies have shown good histologic results in GBR (12,15,17). In general, the amount of newly formed bone is limited by the space below the membrane. ADM can collapse into the bone defects; therefore, the use of bone substitutes has been suggested as space maintainers.

Some biomaterials, such as hydroxyapatite, calcium sulfate, bioactive glass, and xenograft bone substitutes, have demonstrated good results when associated with membranes or ADM (16,18-20). A new bone substitute composed of anorganic bovine bone matrix (ABM) and P-15, a synthetic component with a sequence of 15 amino acids of collagen type I, has been used as a new alternative (21). ABM/P-15 has osteoconductive properties because of its ability to promote cell binding, such as fibroblasts and osteoblasts, initiating the cascade of events that allows bone formation including cell migration and differentiation (21). Some studies in dogs have demonstrated the association of ABM/P-15 and biologic membranes. Barboza et al. (22) induced surgical Class III alveolar defects on mandibular second premolars. At 8 weeks, the defects in the test group were filled with ABM associated with a bioabsorbable membrane, and the control group was filled only with ABM/P-15. Clinical results showed significant bone increase and histologic images showed bone formation in the test areas. Beck and Mealey (23) evaluated histologically the bone formation using a single bone allograft material at two different time points after tooth extraction and socket grafting. No statistically significant differences in the amount of new bone formation was found between sites that healed for an average of 14 weeks compared to those that healed for an average of 27 weeks. All sites examined in that study displayed evidence of new bone formation. Moreover, other studies (24-26) suggest that ridge preservation techniques using mineralized human bone allograft may promote new bone formation in the healing extraction socket. The histological analysis of the use of ABM/P-15 with ADM for the treatment of ridge defects after tooth extraction has not been reported in the literature. Therefore, this study aims to analyze through histomorphometric analysis the use of both biomaterials to preserve alveolar bone after tooth extraction.

MATERIALS AND METHODS

The present study was performed at the Ribeirão Preto School of Dentistry, University of São Paulo, São Paulo, Brazil, between February 2009 and February 2011. It was approved by the Ethical Committee for Human Research of the same institution, protocol number 2009.1.388.58.0.

This study is a sequence of a recently published study (27), in which the surgical phase of the study is detailed. In summary, 18 patients (five males and 13 females; age range: 33 to 58 years) were selected. They received detailed written information about the treatment and signed an informed consent form. To be included in the study, the patient had to present ≥ 2 hopeless, single-rooted, and non-adjacent teeth in the maxilla. This was established to avoid the situation where the bone plate of one group could interfere with the healing process of the other group, since the bone plates could be in intimate contact. Therefore, all hopeless teeth were extracted, regardless of whether or not they were included in the study.

In this split-mouth study, the test group had 18 sockets treated with ABM/P-15 (PepGen P-15, DENTSPLY Friadent CeraMed, Lakewood, CO) associated with ADM (Alloderm, BioHorizons, Birmingham, Alabama), and the control group (blood clot) had 18 sockets treated only with ADM. Surgical procedures were performed under local anesthesia, and for the extractions a periosteal flap was used to reduce trauma to the bone. Intra-alveolar incisions were performed after making releasing incisions on the proximal surfaces of the adjacent teeth, and a mucoperiosteal flap was elevated to expose both the labial and palatal aspects of the alveolar ridge. After tooth removal, the granulation tissue was curetted and removed. The two sockets selected for the study were treated with GBR, using ADM as a barrier membrane, however, only the test socket was filled with the grafting material. After the socket grafting procedure, the full-thickness buccal and lingual flaps were repositioned and sutured with 5.0 non-resorbable sutures. The ADM was intentionally left exposed in its central portion (≤ 2 mm) to induce an increase in the width of the keratinized tissue.

Six months after the first surgical procedure, a reentry surgery was performed using the same approach described previously and biopsies measuring 2x5 mm were made in the previously extraction socket area with a 2.75-mm trephine drill (outer diameter) in the central portion of the alveolus for the test (ADM plus ABM/P-15) and control (ADM only) groups. Some patients were not included in this phase of the study, because the remaining bone was not sufficient for implant placement and others did not want to continue participating in this research. So, 10 of 18 patients were selected for the biopsies and implant placement.

In most of the sites, implants were placed after the biopsies and preparation of the site. The biopsies were fixed using 4% formalin at pH 7 for 10 days and transferred to a 70% ethanol solution to wait for processing. The samples were dehydrated in increasing alcohol concentrations until 100% concentration was reached. They were embedded in LR White resin (London Resin Company Ltd, UK), subsequently two sections from the center of the tissue blocks were made perpendicularly to the long axes using a microtome following the technique for hard tissues, one group of sections were stained with Stevenel's blue

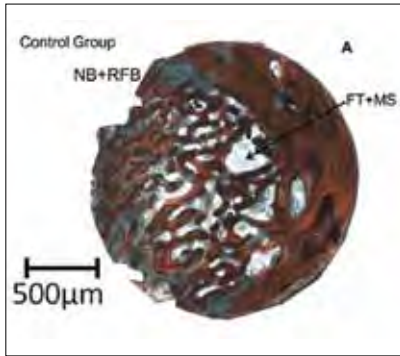


FIG. 1A The control group biopsy shows the formation of the new bone (NB) and recently formed bone (RFB) in the center.

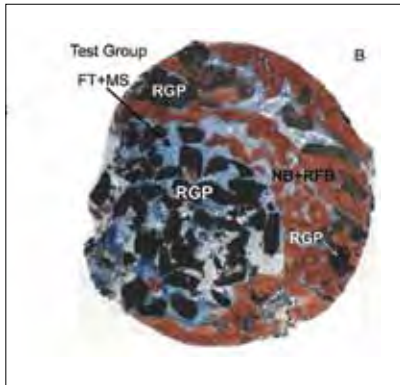


FIG. 1B The test group biopsy shows the residual graft particles (RGP) and fibrous tissue plus marrow spaces (FT+MS) in the center and the formation of the new bone (NB) and recently formed bone (RFB) in the extremity (Mallory trichromic stain; original magnification, x1.6).

and Alizarin red S, and the other with Toluidine blue for optical microscopy. With this last stain it was possible to identify the bone tissue that was in formation during the healing process and the bone that was being deposited at the time of the biopsy.

Histomorphometric analysis

Histological sections from each biopsy were captured through a video camera (Leica DC300F; Leica Microsystems, Heerburgg, Switzerland) joined to a stereomicroscope (Leica MZFL III). The images were analyzed using the Image J Program to determine the following area measurements (mm²): total area (TA), new bone area (NBA), recently formed bone (RFB) and fibrous tissue and marrow spaces (MS). In the test groups (ADM plus ABM/P-15) the amount of residual graft particles (RGP) was measured in the total area.

Statistical analysis

To compare the results obtained in the control and test groups after treatment, Wilcoxon signed-rank test was applied. For all statistical analyses, a significance level of 5% (P<0.05) was used.

RESULTS

Clinical findings

The surgical procedures were well tolerated by all 18 patients (5 males and 13 females, mean age 44 – 8.10 years; age range 33 to 58 years) with no postoperative

complications. No sockets presented exfoliation of the bone graft, indicating that the use of ADM was appropriate for graft retention at the healing phase.

Histological observations

It was possible to observe the presence of newly formed bone (NB), most recently formed bone (RFB) and fibrous tissue plus marrow spaces (FT+MS) in the sections from both groups (Fig. 1A, 1B). Besides, in the test group, residual graft particles (RGP) of ADM/ P-15 were present in the center and in the border of the biopsy (Fig. 1B). The control and test groups showed an osteoid matrix (OM) that was also identified in some areas on the external surfaces of the newly formed bone (Fig. 2A, 2B), and it was paved with osteoblasts (OB) both in

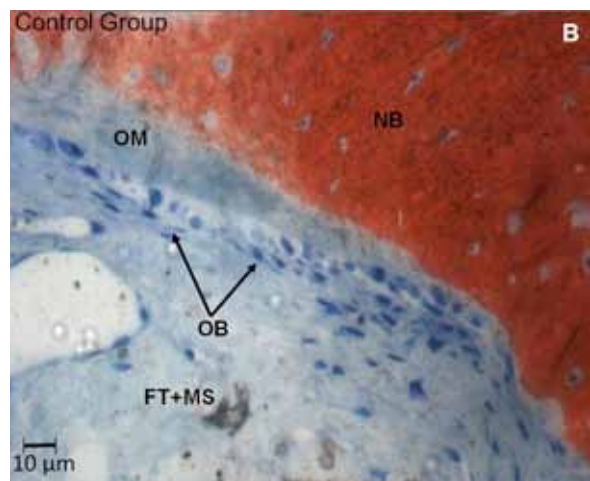
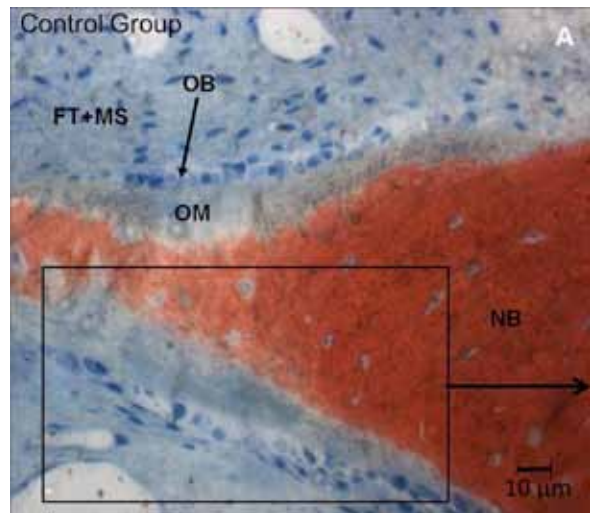


FIG. 2A The presence of the fibrous tissue and marrow spaces (FT+MS), osteoid matrix (OM), osteoblast (OB) and newly formed bone (NB) in the control and test groups (Mallory trichromic stain; original magnification, x40).

FIG. 2B The evidence of these structures and cells with another image (Mallory trichromic stain; original magnification, x40).

the interior and exterior of the lamellae depositing unmineralized osteoid matrix (Fig. 2A, 2B). Interrupted/partially resorbed lamellae and incremental lines were observed in the newly formed bone, indicating regions of new bone formation (Fig. 3, 4). Besides, in some areas, lamellae circumscribed by concentric bone matrix were present representing new bone formation (Fig. 4). The most recently formed bone (RFB) was partly fibrous and partly cellular and immature (Fig. 3, 4, 5B). The bone with this characteristic was present on the surface of the newly formed bone overlapping this structure. This RFB was depositing at the moment of the biopsy, representing the remodeling process of the newly formed bone, which was deposited during the healing period (figures 3, 4 and 5B). A layer of osteoblasts on the external surfaces of the most recently formed bone

was present depositing osteoid matrix (Fig. 4). Amongst the newly formed bone, it was possible to observe the presence of ABM/P-15 residual graft particles (RGP), in the test group (Fig. 5A, 5B). These particles were dispersed in the region corresponding to the area of new bone formation, in some areas, it was present with immature bone formation around and circumscribing the residual particles (Fig. 5A, 5B). Sometimes, these particles were lined by the newly formed bone representing the direct contact between the structures (Fig. 5B).

Histomorphometric findings

At 6 months, the histomorphometric analysis showed 38.66% of new bone tissue, 6.84% of recently formed bone (total amount of 45.5% of mineralized tissue) and

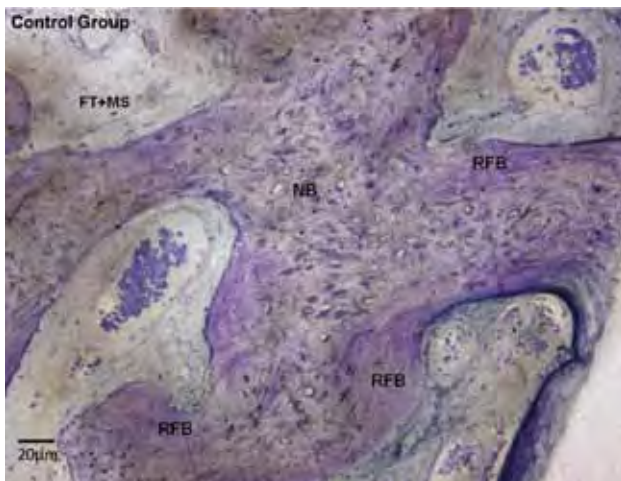


FIG. 3 In the control group: the fibrous tissue and marrow spaces (FT+MS), newly formed bone (NB) and the recently formed bone (RFB) overlapping the new bone in the extremity of the structure (Toluidine blue stain; original magnification, x20).

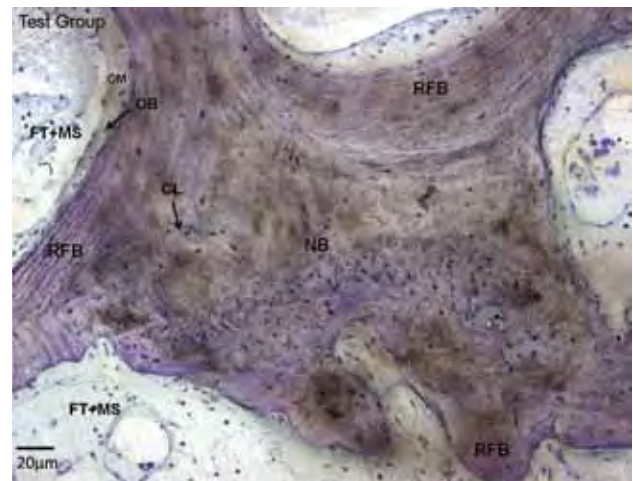


FIG. 4 In the test group: the fibrous tissue and marrow spaces (FT+MS), new bone formed (NB) and the recently formed bone (RFB) formation overlapping the new bone in the extremity of the structure. The osteoid matrix (OM) and osteoblasts (OB) in the external surface of the newly bone formed and the presence of the concentric lamellae (CL) in the center (Toluidine Blue stain; original magnification, x20).

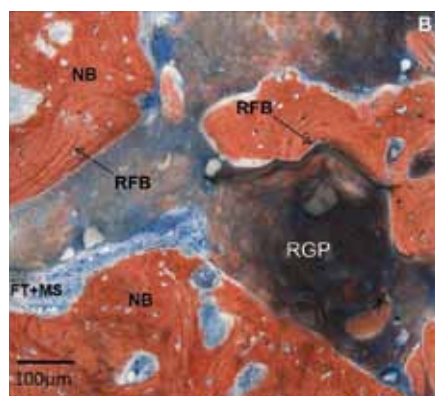



FIG. 5A In the test group the residual particles (RGP) of ABM/P-15 were observed as well as fibrous tissue and marrow spaces (FT+MS) in the center of the biopsy. The new bone formation (NB) and recently formed bone (RFB) was observed on the border of the biopsy (Toluidine blue stain; original magnification, x10).

FIG. 5B The recently formed bone (RFB) is present in the extremity of the new bone (NB). The new bone was formed around and is circumscribing the residual graft particles (RGP) (Mallory trichromic stain; original magnification, x10).



54.5% of fibrous tissue and marrow spaces in the control group. The test group presented 29.13% of new bone area, 7.8% of recently formed bone area (total amount of 36.93% of mineralized tissue), 42.4% of fibrous tissue plus marrow space and 20.67% of residual graft particles. The results showed no statistically significant differences ($p > 0.05$) between the test and control groups (TG and CG) for the recently formed bone (RFB) area ($p > 0.05$). However, the new bone area parameter (NBA) showed higher values to the control group, and statistically significant differences when compared with the test group ($p = 0.03$). Additionally, the percentage of fibrous tissue plus marrow space areas was higher in the control group, and showed statistically significant differences in comparison with the test group ($p = 0.03$). Additionally, in the test group, we found particles of ABM/P-15 (bone graft) corresponding to 20.67% of the total area (Table 1).

DISCUSSION

The presence of tooth and the functional supporting tissues (cementum, periodontal ligament, and bone) play a crucial role in maintaining the dimensions of the alveolar process. Alveolar deformities resulting from tooth loss can cause esthetic and functional problems, especially in the anterior maxilla. During alveolar wound healing, most changes occur during the first 4 months (7, 28). Therefore, preservation of the ridge is important to avoid alveolar bone and soft tissue collapse, which could impair and compromise the prosthetic rehabilitation with implants or conventional prostheses (6,20,29,30). GBR has been used successfully to prevent alveolar ridge deformities (7,31-34). A number of materials, non-absorbable and absorbable, have been used as membranes, with similar results in terms of bone formation (27,35-39). The ideal barrier should be made of material less susceptible to membrane exposure or that cannot be significantly colonized by periodontopathogenic bacteria when exposed to the oral cavity.

The present study shows that the GBR technique using ADM was able to reduce initial bone resorption. ADM has been used for numerous purposes and clinical studies have also used the ADM as a membrane for GBR in edentulous ridges and in association with immediate implants, suggesting that this material may be able to act as a barrier (11,34,40-42). Different studies showed that ADM can be used as a membrane for ridge preservation procedures in GBR, minimizing bone remodeling after tooth extraction (11,12,14,17).

This study evaluated the use of ADM in post-extraction alveoli (control group - CG) to reduce ridge deformities and to induce bone formation within the alveoli. The histomorphometric analysis showed 38.66% of new bone tissue, 6.84% of recently formed bone and 54.5% of fibrous tissue and marrow spaces. These results are similar to those obtained by Borges et al. (12) that observed in dogs 58.99% of bone fill into the defect area and to those obtained by Schenk et al. (43), who reported that the newly formed bone occupied 55% of the defect volume. In our study, we found a total of 40.9% of mineralized tissue that corroborated with the results of Schenk et al. (43) and Borges et al. (12) who observed approximately 38% and 42.47% of mineralized tissue. Jovanovic et al. (44), on the other hand, reported a bone density that varied from 50% to 57% in control sites or in sites treated with GBR.

The basic principle of GBR is the isolation of epithelium and connective tissue cells from the bone defects (8). However, it is necessary that the available space for bone regeneration be maintained under the membranes or ADM, which have a tendency to collapse into larger bone defects. To maintain space and to act as a scaffold for cell migration, proliferation and differentiation, an association of bone grafts and GBR is suggested. As a result some bone substitutes have emerged with a promising outcome.

In the present study, ABM/P-15 was used as bone graft in association with ADM. ABM/P-15 emerged in studies that focused on cell adhesion, which can influence the function and metabolism of various cell types during biologic processes. Qian and Bhatnagar (21) developed a synthetic peptide composed of a defined sequence of 15 amino acids, identical to a potent domain of cell alpha-1 chain receptor of type I collagen. They used particles of hydroxyapatite of bovine origin as carriers for this peptide. This combination allows the stimulation of fibroblast adhesion and the formation of three-dimensional colonies of extracellular collagen matrix, with mineralization foci, forming a structure similar to bone; in this way, it improves the efficacy of conventional replacement grafts in the treatment of intrabony defects.

Krauser et al. (45) observed histologically that the sites treated with ABM/P-15 showed new bone around the graft particles, whereas sites treated with ABM remained encapsulated by a fibrous tissue. Smiler et al.

	TA	NBA	RFB	FT+MS	RGP
CG	100	38.66 ± 6.9*	6.84 ± 2.4	54.5 ± 6.5†	-
TG	100	29.13 ± 6.6*	7.8 ± 1.9	42.4 ± 4.2†	20.67%
P	-	0.03*	0.62	0.03*	-

Legend:
 TA: total area;
 NB: new bone area;
 RFB: recently formed bone;
 FT+MS: fibrous tissue and marrow spaces;
 RGP: residual graft particles.
 Wilcoxon signed-rank test;
 *†Statistically significant difference between the groups ($P < 0.05$)

TABLE 1.

(46) compared two groups, ABM/ P-15 and ABM plus demineralized freeze-dried bone allograft, in sinus-lifting procedures. They observed after 4 months that there was 45% vital bone when ABM/P-15 was used, compared to 13% of the association to the allograft alone.

To our knowledge, the present study is the first to evaluate the influence of ABM/P-15 associated with ADM in the prevention of ridge deformities after tooth extraction. The data show that the graft (ABM/P-15) efficiently promoted the maintenance of the buccal-palatal dimension (27). In the experimental group, the histomorphometric analysis showed 29.13% of new bone area, 7.8% of recently formed bone area, 42.4% of fibrous tissue plus marrow space and 20.67% of residual graft particles.

The histological examination revealed that the central portions of the specimens were mainly occupied by regenerated bone and bone marrow. The biopsy showed mature bone with lamellar configuration throughout the specimens. The percentage of bone tissue was 37% and this value was comparable with the 6- to 8-month results from Froum et al. (47) (41.7%), who used nonabsorbable anorganic bovine bone mineral and ADM. Neiva et al. (48) found similar results to this study using Putty P15 and bioabsorbable collagen in post-extraction alveoli and 29.92% of new bone was observed. In accordance, Fotek et al. (32) reported a range of 27% to 32% of new bone formation 16 weeks after ridge preservation.

In comparison with other bone grafts, the ABM/P-15 shows slightly increased bone formation into the socket. Norton et al. (49) used xenograft and porcine collagen membrane and reported that the mean percentage area of new bone formation was 25.6% after a mean of 26 weeks. Carmagnola et al. (50) filled the extraction sockets only with deproteinized bovine bone mineral and made undecalcified specimens after 7 months. The sections were comprised of $26.0 \pm 23.7\%$ lamellar bone and $8.4 \pm 8.0\%$ woven bone. Comparing with the present study, Carmagnola et al. (50) and Norton et al. (49) showed lower percentage of bone formation (about 10%).

In this study, 20.67% of graft residual particles remained after 24 weeks of healing. This result was similar to numerous studies showing that full graft resorption was never observed. In fact, these data were superior to those of Artzi et al. (51) who reported 30% of graft residual particles. Two major differences were noted between this study and the one by Artzi et al. (51); they used a xenograft and allowed a longer healing period (9 months). Yet, even with the longer healing periods, a major component of the particulate xenograft remained. Similarly, Carmagnola et al. (50) found a significant proportion of xenograft particles (21.1%) remaining. This slower resorption rate could hinder new bone formation as shown by Vance et al. (25), in which bone was found in 61% of the sites grafted with an allograft versus 26% of sites grafted with a bovine

hydroxyapatite. Fotek et al. (32) reported an average of 14% to 15% of residual bone graft particles with a range of 27% to 32% of new bone formation 16 weeks after ridge preservation.

CONCLUSION

In conclusion, ADM acted as a membrane and led to new bone formation within the alveoli. Also, the addition of ABM/P-15 resulted in the new bone formation within the alveoli. Although the ABM/P-15 showed satisfactory results at the 6-month observation period, the results were not considered relevant when used in this indication.

ACKNOWLEDGMENTS

The authors want to thank BioHorizons, Inc. Birmingham, Alabama for donating the acellular dermal matrix used in this study. The authors report no conflicts of interest related to this study.

REFERENCES

1. Amler MH. The time sequence of tissue regeneration in human extraction wounds. *Oral Surg Oral Med Oral Pathol* 1969;27(3):309-318.
2. Atwood DA, Coy WA. Clinical, cephalometric, and densitometric study of reduction of residual ridges. *J Prosthet Dent* 1971;26(3):280-95.
3. Araújo MG, Lindhe J. Ridge alterations following tooth extraction with and without flap elevation: an experimental study in the dog. *Clin Oral Implants Res* 2009;20(6):545-9.
4. Seibert JS. Treatment of moderate localized alveolar ridge defects. Preventive and reconstructive concepts in therapy. *Dent Clin North Am* 1993;37(2):265-80.
5. Lekovic V, Camargo PM, Klokkevold PR et al. Preservation of alveolar bone in extraction sockets using bioabsorbable membranes. *J Periodontol* 1998;69(9):1044-9.
6. Lekovic V, Kenney EB, Weinlaender M et al. A bone regenerative approach to alveolar ridge maintenance following tooth extraction. Report of 10 cases. *J Periodontol* 1997;68(6):563-70.
7. Iasella JM, Greenwell H, Miller RL et al. Ridge preservation with freeze-dried bone allograft and a collagen membrane compared to extraction alone for implant site development: A clinical and histologic study in humans. *J Periodontol* 2003;74(7):990-9.
8. Dahlin C, Linde A, Gottlow J, Nyman S. Healing of bone defects by guided tissue regeneration. *Plast Reconstr Surg* 1988;81(5):672-6.
9. de Andrade PF, de Souza SL, de Oliveira Macedo G, Novaes AB Jr, de Moraes Grisi MF, Taba M Jr, Palioto DB. Acellular dermal matrix as a membrane for guided tissue regeneration in the treatment of Class II furcation lesions: A histometric and clinical study in dogs. *J Periodontol* 2007;78(7):1288-99.
10. Novaes AB Jr, Souza SLS. Acellular dermal matrix graft as a membrane for guided bone regeneration: A case report. *Implant Dent* 2001; 10(3):192-6.
11. Novaes AB Jr, Papalexou V, Luczyszyn SM, Muglia VA, Souza SLS,

- Taba M Jr. Immediate implant in extraction socket with acellular dermal matrix graft and bioactive glass: A case report. *Implant Dent* 2002;11(4):343-8.
12. Borges GJ, Novaes AB Jr, Grisi MFM, Palioto DB, Taba M Jr, de Souza SL. Acellular dermal matrix as a barrier in guided bone regeneration: a clinical, radiographic and histomorphometric study in dogs. *Clin Oral Implants Res* 2009;20(10):1105-15.
 13. Wainwright DJ. Use of an acellular allograft dermal matrix (AlloDerm) in the management of full-thickness burns. *Burns* 1995;21(4):243-8.
 14. Batista EL Jr, Batista FC, Novaes AB Jr. Management of soft tissue ridge deformities with acellular dermal matrix. Clinical approach and outcome after 6 months of treatment. *J Periodontol* 2001;72(2):265-73.
 15. Novaes AB Jr, Marchesan JT, Macedo GO, Palioto DB. Effect of in vitro gingival fibroblast seeding on the in vivo incorporation of acellular dermal matrix allografts in dogs. *J Periodontol* 2007;78(2):296-303.
 16. Gapski R, Parks CA, Wang HL. Acellular dermal matrix for mucogingival surgery: a meta-analysis. *J Periodontol* 2005;76(11):1814-22.
 17. Luczyszyn SM, Papalexiou V, Novaes AB Jr, Grisi MFM, Souza SLS, Taba M Jr. Acellular dermal matrix and hydroxyapatite in prevention of ridge deformities after tooth extraction. *Implant Dent* 2005;14(2):176-84.
 18. Sottosanti JS. Aesthetic extractions with calcium sulfate and the principles of guided tissue regeneration. *Pract Periodontics Aesthet Dent* 1993;5(5):61-9, quiz 69.
 19. Buser D, Brägger U, Lang NP, Nyman S. Regeneration and enlargement of jaw bone using guided tissue regeneration. *Clin Oral Implants Res* 1990;1(1):22-32.
 20. McAllister BS, Haghghat K. Bone augmentation techniques. *J Periodontol* 2007;78(3):377-96.
 21. Qian JJ, Bhatnagar RS. Enhanced cell attachment to anorganic bone mineral in the presence of a synthetic peptide related to collagen. *J Biomed Mater Res* 1996;31(4):545-54.
 22. Barboza EP, de Souza RO, Caúla AL, Neto LG, Caúla FdeO, Duarte ME. Bone regeneration of localized chronic alveolar defects utilizing cell binding peptide associated with anorganic bovine-derived bone mineral: A clinical and histological study. *J Periodontol* 2002;73(10):1153-9.
 23. Beck TM, Mealey BL. Histologic analysis of healing after tooth extraction with ridge preservation using mineralized human bone allograft. *J Periodontol* 2010;81(12):1765-72. Epub 2010 Jul 27.
 24. Wang HL, Tsao YP. Mineralized bone allograft-plug socket augmentation: rationale and technique. *Implant Dent* 2007;16(1):33-41.
 25. Vance GS, Greenwell H, Miller RL, Hill M, Johnston H, Scheetz JP. Comparison of an allograft in an experimental putty carrier and a bovine-derived xenograft used in ridge preservation: a clinical and histologic study in humans. *Int J Oral Maxillofac Implants* 2004;19(4):491-7.
 26. Fowler EB, Breault LG, Rebitski G. Ridge preservation utilizing an acellular dermal allograft and demineralized freeze-dried bone allograft: Part I. A report of 2 cases. *J Periodontol* 2000;71(8):1353-9.
 27. Fernandes PG, Novaes AB Jr, Queiroz AC, Souza SLS, Taba M Jr, Palioto DB, Grisi MFM. Ridge preservation with Acellular Dermal Matrix and anorganic bone matrix cell-binding peptide P-15 after tooth extraction in humans. *J Periodontol* 2011;82(1):72-9.
 28. Johnson K. A study of the dimensional changes occurring in the maxilla following tooth extraction. *Aust Dent J* 1969;14(4):241-4.
 29. Zubillaga G, Von Hagen S, Simon BI, Deasy MJ. Changes in alveolar bone height and width following post-extraction ridge augmentation using a fixed bioabsorbable membrane and demineralized freeze-dried bone osteoinductive graft. *J Periodontol* 2003;74(7):965-75.
 30. Simon BI, Von Hagen S, Deasy MJ, Faldut M, Resnansky D. Changes in alveolar bone height and width following ridge augmentation using bone graft and membranes. *J Periodontol* 2000;71(11):1774-91.
 31. Kirkland G, Greenwell H, Drisko C, Wittwer JW, Yancey J, Rebitski G. Hard tissue ridge augmentation using a resorbable membrane and a particulate graft without complete flap closure. *Int J Periodontics Restorative Dent* 2000;20(4):382-9.
 32. Fotek PD, Neiva RF, Wang HL. Comparison of dermal matrix and polytetrafluoroethylene membrane for socket bone augmentation: a clinical and histologic study. *J Periodontol* 2009;80(5):776-85.
 33. Pinho MN, Roriz VL, Novaes AB Jr et al. Titanium membranes in prevention of alveolar collapse after tooth extraction. *Implant Dent* 2006;15(1):53-61.
 34. Fowler EB, Breault LG, Rebitski G. Ridge preservation utilizing an acellular dermal allograft and demineralized freeze-dried bone allograft: Part II. Immediate endosseous implant placement. *J Periodontol* 2000;71(8):1360-4.
 35. Hockers T, Abensur D, Valentini P, Legrand R, Hammerle CH. The combined use of bioresorbable membranes and xenografts or autografts in the treatment of bone defects around implants. A study in beagle dogs. *Clin Oral Implants Res* 1999; 10(6):487-98.
 36. Polimeni G, Koo KT, Pringle GA, Agelan A, Safadi FF, Wikesjo UM. Histopathological observations of a polylactic acid-based device intended for guided bone/tissue regeneration. *Clin Implant Dent Relat Res* 2008;10(2):99-105.
 37. Thomaidis V, Kazakos K, Lyras DN, Dimitrakopoulos I, Lazaridis N, Karakasis D, Botaitis S, Agrogiannis G. Comparative study of 5 different membranes for guided bone regeneration of rabbit mandibular defects beyond critical size. *Med Sci Monit* 2008;14(4):BR67-73.
 38. Trombelli L, Farina R, Marzola A, Itró A, Calura G. GBR and autogenous cortical bone particulate by bone scraper for alveolar ridge augmentation: a 2-case report. *Int J Oral Maxillofac Implants* 2008;23(1):111-6.
 39. Schwarz F, Rothamel D, Herten M, Wüstefeld M, Sager M, Ferrari D, Becker J. Immunohistochemical characterization of guided bone regeneration at a dehiscence-type defect using different barrier membranes: an experimental study in dogs. *Clin Oral Implants Res* 2008;19(4):402-15.
 40. Griffin TJ, Cheung WS, Hirayama H. Hard and soft tissue augmentation in implant therapy using acellular dermal matrix. *Int J Periodontics Restorative Dent* 2004;24(4):352-61.
 41. Novaes AB Jr, Pontes CC, Souza SL, Grisi MF, Taba M Jr. The use of acellular dermal matrix allograft for the elimination of gingival melanin pigmentation: case presentation with 2 years of follow-up. *Pract Proced Aesthet Dent* 2002;14(8):619-23; quiz 624.
 42. Novaes AB Jr, Grisi DC, Molina GO, Souza SL, Taba M Jr, Grisi MF. Comparative 6-month clinical study of a subepithelial connective tissue graft and acellular dermal matrix graft for the treatment of gingival recession. *J Periodontol* 2001;72(11):1477-84.
 43. Schenk RK, Buser D, Hardwick WR, Dahlin C. Healing pattern of bone regeneration in membrane-protected defects: a histologic study in the canine mandible. *Int J Oral Maxillofac Implants* 1994;9(1):13-29.
 44. Jovanovic SA, Hunt DR, Bernard GW, Spiekermann H, Wozney JM, Wikesjo UM. Bone reconstruction following implantation of rhBMP-2 and guided bone regeneration in canine alveolar ridge defects. *Clin Oral Implants Res* 2007;18(2):224-30.
 45. Krauser JT, Rohrer MD, Wallace SS. Human histologic and histomorphometric analysis comparing OsteoGraf/N with PepGen P-15 in the maxillary sinus elevation procedure: a case report. *Implant Dent* 2000;9(4):298-302.
 46. Smiler DG, Johnson PW, Lozada JL, et al. Sinus lift grafts and endosseous implants. Treatment of the atrophic posterior maxilla. *Dent Clin North Am* 1992;36(1):151-86; discussion 187-8.

47. Froum S, Cho SC, Eliam N, et al. Extraction sockets and implantation of hydroxyapatites with membrane barriers. A histologic study. *Implant Dent* 2004;13(2):153-64
48. Neiva RF, Tsao YP, Eber R, Shotwell J, Billy E, Wang HL. Effects of a putty-form hydroxyapatite matrix combined with the synthetic cell-binding peptide P-15 on alveolar ridge preservation. *J Periodontol* 2008;79(2):291-9.
49. Norton MR, Odell EW, Thompson ID, Cook RJ. Efficacy of bovine bone mineral for alveolar augmentation: A human histologic study. *Clin Oral Implants Res* 2003;14(6):775-83.
50. Carmagnola D, Adriaens P, Berglundh T. Healing of human extraction sockets filled with Bio-Oss®. *Clin Oral Implants Res* 2003;14(2):137-43.
51. Artzi Z, Tal H, Dayan D. Porous bovine bone mineral in healing of human extraction sockets. Part 1: Histomorphometric evaluations at 9 months. *J Periodontol* 2000;71(6):1015-23.