

Improving osseous conditions around teeth and implants utilizing high frequency vibration

> **G.M. KURTZMAN¹, R.A. HOROWITZ², M.B. HALLAS³, T. EL-BIALY⁴**

¹Private dental practice, Silver Spring, Maryland, USA

²Clinical Assistant Professor, Ashman Departments of Periodontology and Implant Dentistry, Oral Surgery, Biomimetics and Biomaterials, New York University College of Dentistry, New York, New York; Private Practice in Periodontics and Implant Dentistry, Scarsdale, New York, United States

³Private dental practice, Green Bay, Wisconsin, USA

⁴Professor, Department of Dentistry, Division of Orthodontics, University of Alberta, Edmonton AB, Canada

TO CITE THIS ARTICLE

Kurtzman GM, Horowitz RA, Hallas MB, El-Bialy T. Improving osseous conditions around teeth and implants utilizing high frequency vibration. *J Osseointegr* 2020;12(4):35-42.

DOI 10.23805 /JO.2021.13.01.6

KEYWORDS Low magnitude high frequency vibration, LMHFV, peri-implantitis, mobile teeth, osseous graft enhancement

ABSTRACT

Aim The aim of this work is to review the applications of LMHFV in improving bone density around implants and teeth.

Results Low magnitude high frequency vibration (LMHFV) has been actively used in orthopedics to improve bone density, osseous healing via stimulation of osteogenic cells, release of growth factors and stimulation of angiogenesis. Those concepts have been carried over to dental treatment. A common clinical challenge in dental practice relates to bone loss associated with periodontal disease, tooth loss or other causes as well as treating tooth mobility and peri-implantitis.

Conclusion LMHFV provides similar positive results as reported in orthopedics, to improve osteo-stimulatory affects improving bone quality and density around both natural teeth and dental implants.

INTRODUCTION

Common clinical challenges in dental practice relate to treating bone loss associated with periodontal disease, tooth loss or other causes as well as treating tooth mobility and peri-implantitis. High frequency vibration treatment shows promise for improving the care of these patients. The applications of low magnitude high frequency vibration (LMHFV) have extended from orthopedic use into dental treatment to decrease tooth mobility by improvement in the surrounding bone density as well as fibroblast stimulation of cells within the periodontal ligament. Additionally, LMHFV stimulation has a positive effect on osteoblasts and growth

factors with improvement in osseous grafting through angiogenesis stimulation with a resulting increase in bone density. Bone density, when LMHFV is utilized at implant placement either in non-loading or immediate loading clinical situations, demonstrates more rapid improvement compared to non-use of LMHFV. When treating peri-implantitis, LMHFV can improve the clinical situation over a shorter time frame than when it is not utilized as part of the treatment whether grafting is part of that treatment or not.

Bone is a dynamic material. Healthy bone to maintain a balance between the osteoclastic and osteoblastic activity requires good osseous circulation, thus maintaining mineralization and osseous density (1). When stimulated within physiological limits bone maintains volume and density (1). Osseous stimulation below the physiological limits, results in atrophy with density and ultimately volume diminishing (2). Stimulation exceeding those physiological limits leads to bone loss, which may be related to hyper-occlusion or decreased osseous support (1). The biological environment for osteogenic potential is influenced by several factors which include: blood supply (3), osseous-forming cells and growth factors (4,5), as well as the localized mechanical environment at the affected site (6). These have been determined as the key for the healing of a fracture (7). Additionally, proper loading conditions have been shown to be crucial for bone repair and remodeling (8).

Literature in orthopedics has long reported the use of LMHFV has a stimulatory effect on osseous healing. LMHFV, is a form of biophysical intervention providing cyclic loadings that has in animal models proven its osteogenic potential (9,10). Bone mineral density (BMD)

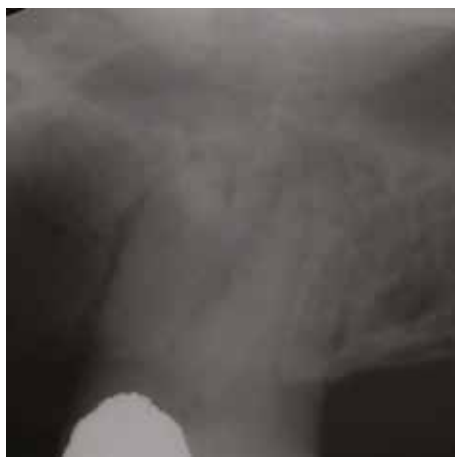

FIG. 1 Maxillary molar exhibiting grade 2+ mobility that has widened PDL space surrounding the tooth and a possible lesion on the distal buccal apical area.

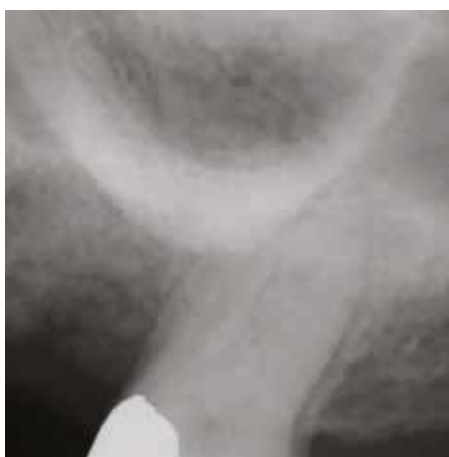

FIG. 2 Following use of the LMHFV for 5 minutes daily for 4 months mobility has resolved and apical area has disappeared with a normal PDL space radiographically.

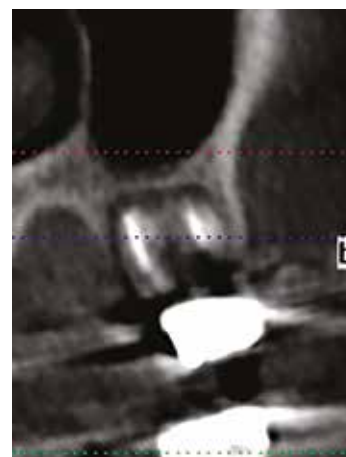


FIG. 3 CBCT cross section of the maxillary molar area pretreatment demonstrating periapical pathology associated with failed endodontics that will necessitate extraction of the molar.

(11,12) and blood circulation (13) are also reported to demonstrate positive effects related to use of LMHFV. LMHFV has carried over into dental clinical applications to improve bone density, the mineral content of the bone either around teeth, implants or in grafted sites with an increase in BMD and localized osseous circulation improvement. The increase in bone density, improving the periodontal status of involved teeth leads to a subsequent decrease in tooth mobility. This correlates to implant applications with improvement in the BMD and circulation when utilized after implant placement or with sites that are being grafted in anticipation of later implant placement. Growth factor release (i.e. BMP2, PDGF α , TGF β 1 etc.) as well as increasing osteoblast and PDL cell proliferation stimulation from LMHFV results (14,15). Additionally, evidence has been reported that LMHFV regulates gene expression enhancing callus formation, mineralization, and remodeling of bone (16). Thereby bone remodeling is enhanced and accelerated (17,18). The aim of this work is to review the applications of LMHFV in improving bone density around implants and teeth.

Mobile teeth

Mobility in natural teeth may be related to occlusal factors, such as higher load or off-axis loading than can be accommodated within the available osseous support of the tooth (19). This results in widening of the periodontal ligament and loss of bone crestally, thus accelerating the decrease in load handling that the tooth can manage (20). Bone density plays a factor in the tooth's ability to manage loads. The higher the bone density the better load transfer to the surrounding alveolar structure via the PDL and the greater the periodontal stability of the tooth within the bone housing it. With regard to BMD, age has a contributory factor and it is well documented that as age increases BMD decreases, leading to osteoporosis and osteopenia

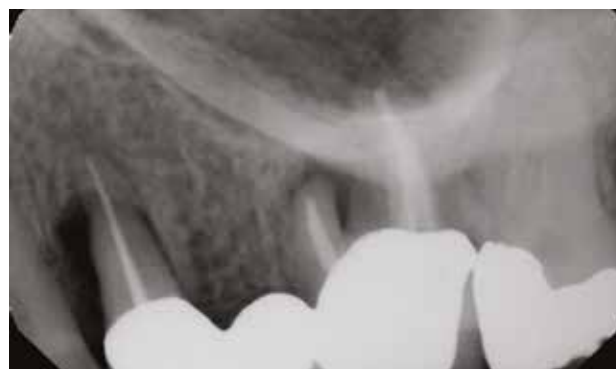

FIG. 4 Periapical radiograph demonstrating failed endodontics with associated osseous destruction that will necessitate extraction of the bridge abutment teeth.

(21). Those changes are also observed in the maxilla and mandible, with a higher frequency and degree in females. This correlates with their higher incidence of osteoporotic changes than observed in males (22). Occlusal adjustment to eliminate off-axis contacts with opposing teeth allows for better direction of loading. But this may not eliminate the mobility that was present initially. Improving the bone density surrounding the tooth will aid in preservation of the bone level and support for the tooth. Mechanical stimulation contributes to alveolar bone health as previously discussed. HFV (high frequency vibration) is a noninvasive safe treatment that can be used to prevent alveolar bone loss, accelerate bone healing and improve alveolar bone quality and quantity under both physiological and pathological conditions (23). When high-frequency vibration is applied to teeth exhibiting less than moderate mobility when sufficient bone levels are present, have demonstrated significant increases in BMD with alveolar bone formation and improvement in

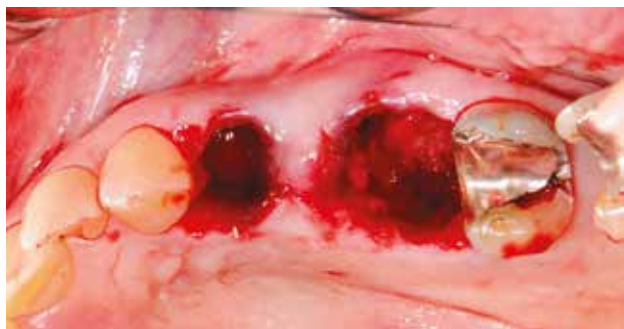

FIG. 5 Extraction sockets following curettage prior to socket grafting.

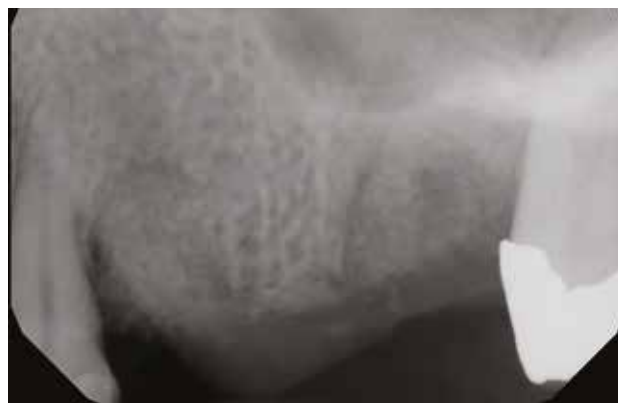

FIG. 6 Radiograph following extraction of the bridge abutments, socket curettage and socket grafting demonstrating a granular appearance of the graft material.

the initial mobility. These effects were not restricted to the area of application (mobile teeth) and improvement in BMD is reported to extend throughout the maxilla and mandible, as bone is an excellent conductor of vibration (24). Maxillary bone is lower density than bone found in the mandible with the anterior presenting with higher density than observed typically in the posterior in either arch (25). Thus, the maxilla is more prone to tooth mobility due to its lower osseous density compared to the mandible. The maxilla additionally has a higher resorption potential than the mandible when challenged by periodontal disease or occlusal trauma (26).

Radiographically, teeth presenting with mobility have a widened PDL space and lower dense bone surrounding that tooth (Fig. 1). Utilization by the patient of LMHFV (PerioTech device, PerioTech LLC, Milpitas, CA) for 5 minutes daily, stimulates the bone increasing its density with a decrease in the PDL space and associated improvement in the mobility returning to a health periodontal state (Fig. 2).

Graft site improvement

Extraction of teeth either related to periodontal issues, endodontic problems or structural failure of the tooth creates osseous voids that may require grafting of the socket to allow implant placement when the void is larger than the intended implant planned for placement. Significant and rapid bone loss frequently occurs following tooth extraction (27,28). High-frequency vibration has an osteogenic effect, stimulating an increase in vascularization of the clot in the socket when no site grafting is being performed or grafting material that had been placed (29).

LMHFV has been reported to increase bone volume in the extraction site and surrounding alveolar bone by 44% when compared to no use of LMHFV (29). This counteracts the socket resorption that typically is observed following extraction, while fully preserving alveolar bone height and width in the long term. These effects are accompanied by increased expression of osteogenic markers and intramembranous bone formation and by decreased expression of osteoclastic markers and bone resorption activity. A decreased inflammatory marker expression

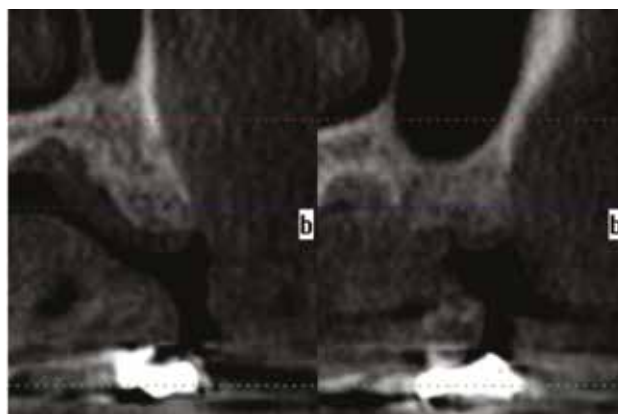


FIG. 7 CBCT cross section of the grafted sockets 4 months post treatment following 5 minutes of LMHFV usage demonstrating increased density of the grafted sites.

has also been reported adding to the positive effects of LMHFV.

Clinically, teeth that will require extraction related to clinical issues that will not permit long-term maintenance have less dense bone surrounding them or defects related to negative biological affects (infection) (Fig. 3, 4).

Following extraction of the problematic teeth, curettage of the sockets is performed to remove any residual pathologic tissue (Fig. 5). The extraction sockets are filled with an appropriate graft material and the site closed with or without a membrane.

A radiograph taken at graft placement will demonstrate a granular appearance of the graft material with lower density within the socket than the host's adjacent native bone (Fig. 6).

The patient is instructed to use the PerioTech LMHFV device 5 minutes daily over a 4-month period. When radiographically examined after the 4-month healing period, the grafted site typically shows more rapid conversion of the graft particles to blend with the surrounding host bone with similar radiographic density

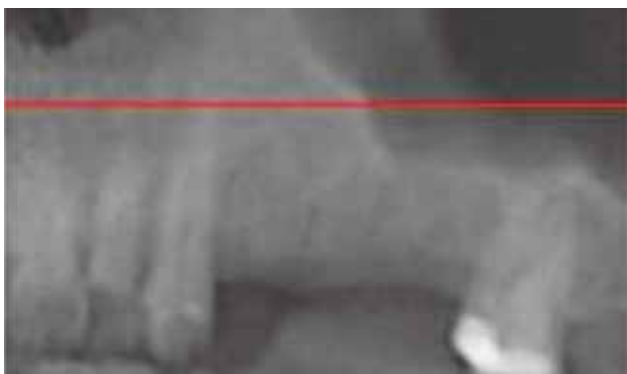

FIG. 8 Panoramic CBCT view demonstrating osseous graft maturation at 4 months and ready for implant placement.

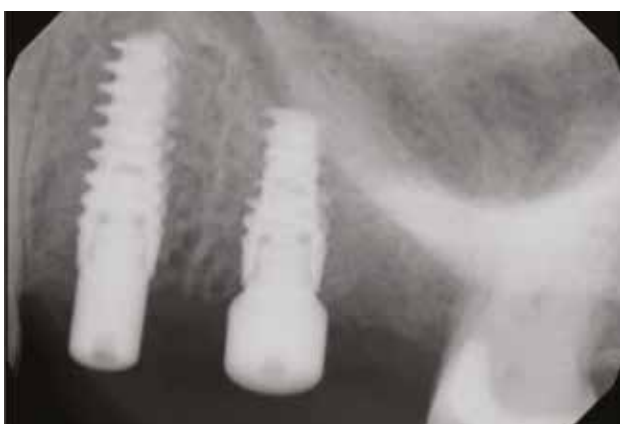

FIG. 10 Implant placement at 4 months post-grafting.

and trabeculation, appearing ready for implant placement (Fig. 7, 8). Flapping of the previously grafted site will demonstrate voids and bone filled earlier than what would be observed if LMHFV was not utilized (Fig. 9). The addition of vibration, as has been reported in orthopedics, improved shear strength of the grafted areas when compared with grafted areas without vibration use. Osseous graft particles exposed to vibration within a confined space have been reported to move into a denser, tighter configuration, with a 40% increase in particle interlocking (30,31). The resulting healed grafted area is denser providing a better bed for implant placement to achieve higher bone to implant contact (BIC) and insertion torque at implant placement. These principles can be applied to other dental grafting applications in addition to socket grafting. Biologically, this results in improved angiogenesis (circulation) into the graft, improving its density sooner and yielding higher quality healed bone than without the use of LMHFV.

Osseous improvement following implant placement

Bone density at implant recipient site has a prevailing influence on primary implant stability (32). This has an influence, whether the protocol calls for immediate loading or allowing the implant to integrate unloaded (delayed loading), with bone density affecting the long-

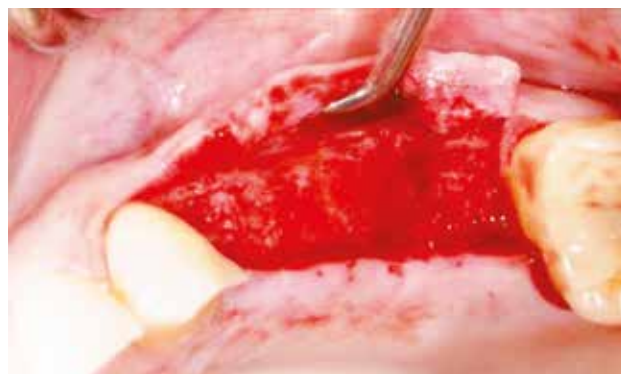


FIG. 9 Following flapping of the grafted area at 4 months post-extraction and socket preservation with daily use of the LMHFV the osseous graft has organized to blend with the surrounding host bone.

term success of the implant once restored (33, 34). Biophysical stimulation, as provided by LMHFV, has been reported to enhance the mineralized component in the bone volume adjacent to implants (35).

Peri-implant bone healing is positively influenced by LMHFV in the early healing period (36). Findings reveal the potential of high-frequency vibration loading to accelerate and enhance implant osseointegration. Such mechanical signals may be incorporated to optimize treatment for improving implant osseointegration in compromised bone (37) with LMHFV stimulating peri-implant bone healing and formation (38). When applied in immediate implant loading, LMHFV can accelerate bone density surrounding the implants improving the expected clinical outcome in a shorter period than traditionally observed. It also has osseous stimulatory effects in cases where the implant will not be immediately loaded and allowed to heal before initiation of the restorative phase. The positive effects of LMHFV on implant osseointegration have been demonstrated. Stimulation of mesenchymal stem cells (BMSCs) in the bone marrow by LMHFV results in the expression of $\beta 1$ integrin, vinculin and paxillin with resulting higher cell numbers and more extracellular matrix attached to the implant surface. Significant elevation of alkaline phosphatase activity as well as the expression of osteogenic-specific genes, (Runx2, osterix, collagen I and osteocalcin) is reported in the LMHFV group. In addition, after exposure to LMHFV protein expression of Wnt10B, β -catenin, Runx2 and osterix was increased. Findings indicate that LMHFV promotes adhesion and osteogenic differentiation of BMSCs that may directly induce osteogenesis. This suggests that LMHFV may enhance the osseointegration of bone to the implant surface, providing a foundation for improving bone-implant osseointegration (35). Early controlled stimulation of peri-implant bone has been reported to provide an increase in bone mass around early loaded implants (39).

LMHFV, as indicated, may be utilized immediately following implant placement when insertion torque dictates (sufficient torque to immediately load) or clinical circumstances will not permit immediate loading

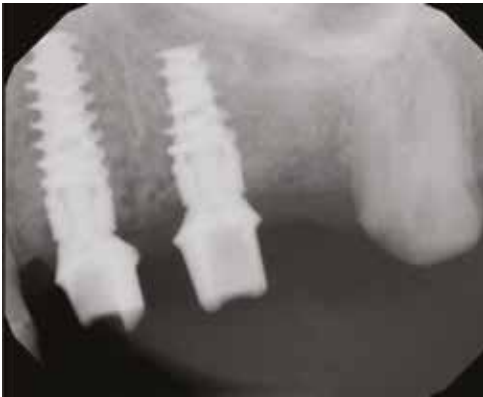

FIG. 11 Implants following 4 months of integration with use of the LMHFV for 5 minutes daily to improve the density of the bone to implant (BIC) during the integration period and placement of custom abutments demonstrating blending of the graft with the surrounding host bone.

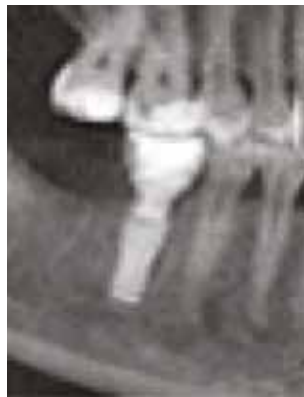

FIG. 12 Mandibular implant with a radiolucent area on the mesial aspect (as noted on CBCT PAN view) with no clinical mobility or sensitivity reported by the patient.

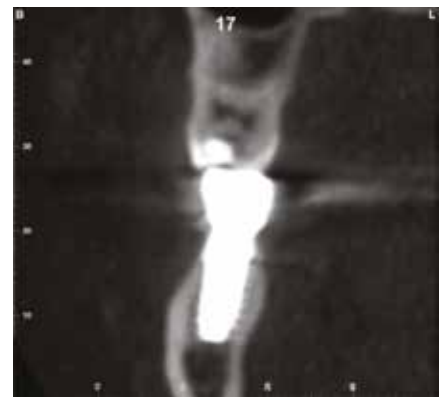

FIG. 13 CBCT cross section before treatment demonstrating bone level on buccal/lingual side of the implant and the density of the cancellous bone in contact with it.

(insufficient insertion torque) (Fig. 10). The use of LMHFV with the PerioTech, utilizing the device for 5 minutes daily (at home by the patient) accelerates bone density improvement and osseous healing through osteogenic cell stimulation, with increased growth factor expression and angiogenesis stimulation, permitting earlier loading (Fig. 11). Once loading is initiated, continued use of LMHFV will further continue to increase bone density around the implants, improving their long-term prognosis through better load handling (40). This may be considered a long-term at home therapy to preserve BIC and potentially prevent peri-implantitis.

Peri-implantitis treatment

Peri-implantitis a pathological condition occurring in hard and soft tissues around dental implants, characterized by inflammation in the peri-implant connective tissue with progressive loss of the supporting bone. Strong evidence exists of an increased risk of developing peri-implantitis in those patients with a history of chronic periodontitis, poor plaque control skills, no regular maintenance care after implant restoration, certain implant surfaces and other risk factors (41). Peri-implantitis is a common problem with reported prevalence rates up to 56% and may lead to the loss of the implant without timely intervention (42). Marginal gingival inflammation may be the initial presentation or radiographically identified during a routine recall appointment with or without concurrent gingival inflammation. Initial presentation may be crestal bone loss either horizontal or angular in nature and a radiographic decrease in bone density at the bone-implant interface. The presence of mobility with an implant, unlike with teeth, indicates a failed implant and explantation is indicated. But bone loss in the absence of mobility when minimal, may benefit from LMHFV in improving the density of the surrounding bone and salvaging the implant without the need to intervene

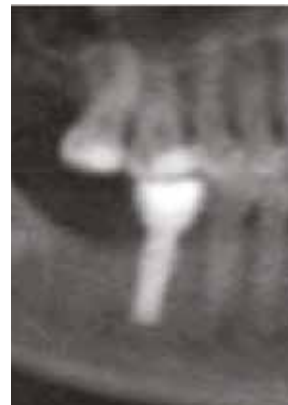

FIG. 14 Following 4 months of daily use of the LMHFV, the radiolucency has resolved and increased osseous density is noted on the CBCT PAN view.

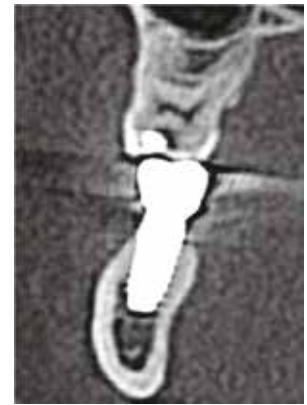

FIG. 15 CBCT cross section after treatment with LMHFV shows bone level on buccal/lingual side of the implant and increase in density of the cancellous bone in contact with it.

with surgery and subsequent grafting. LMHFV may be beneficial in those clinical situations wherein, osseous grafting will be required to cover exposed threads on the implant's length, to improve graft conversion to host bone as with socket grafting by stimulation of osteoblastic activity, growth factors and angiogenesis. LMHFV, in the absence of implant mobility, may increase peripheral bone density around the implant at the bone to implant interface that signifies early peri-implantitis (Fig. 12, 13). At home daily 5-minute utilization stimulates growth factors to potentially fill minor defects at the interface while increasing bone density. Following the use for 4 months, the clinical situation has improved to aid in elimination of early peri-implantitis when first identified radiographically and surgical intervention did not become a clinical necessity (Fig. 14, 15). LMHFV may also be used to supplement surgical intervention when peri-implantitis

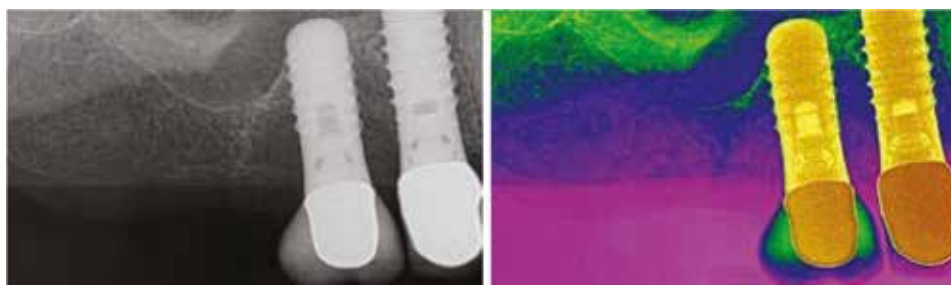


FIG. 16 Patient presented with bone loss as evidenced by decreased bone density adjacent to the implant in the absence of mobility. (purple = very low density, blue = low density, green = high density, yellow = very high density)

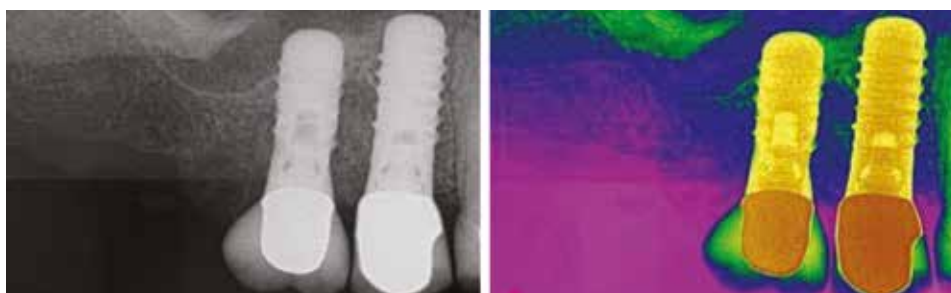


FIG. 17 Immediately following graft placement demonstrating the graft material filling the osseous void that resulted by periimplantitis.

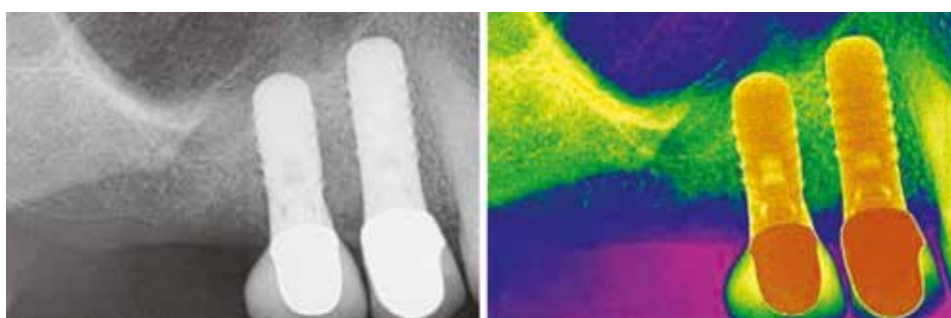


FIG. 18 Two months post graft repair of periimplantitis associated bone loss with daily use of LMHFV by the patient demonstrating increased density of the grafted area to blend with the native bone adjacent to it and an increase in adjacent bone density related to vibration transfer throughout the maxilla.

requires grafting as part of the treatment. Loss of density as observed radiographically of bone adjacent to the implant resulting from peri-implantitis (Fig. 16), shows fill following graft placement into the osseous void (Fig. 17). After two months of LMHFV home use the radiographic density of the graft blends with the native bone (Fig. 18). An added benefit, transference of the vibration increases bone density through the entire arch, providing distant benefits to the patient.

DISCUSSION

Mechanical stimulation delivered by adjunctive vibration has been utilized in orthodontics for a number of years to accelerate tooth movement and improve the bone supporting the dentition (43). Applications of this technology have extended to other areas of dentistry such as dental pain, extraction healing, implant dentistry and prosthodontics.

Two vibration frequencies are available: high (120 Hz) and low (30 Hz) (43). High-frequency vibration has been reported to yield superior results in stimulating osteoblast and fibroblast cell proliferation than reported with low-frequency (44). Maximum osteostimulatory

benefit thus will be found with use of 120 Hz with regard to decreasing tooth mobility, improved graft healing and improved bone density around implants, whether during the integration phase of treatment or as part of treatment for peri-implantitis. When Judex compared non-vibrated controls and LMHFV 120 Hz (PerioTech) with regard to PDL fibroblast and osteoblasts over a 3-day period, a statistically significant increase with the LMHFV was demonstrated with both fibroblasts and osteoblasts. This demonstrates the benefits to cells associated with teeth and bone surrounding both teeth and implants as well as osseous grafts.

The bone healing response at the bone-implant interface is negatively influenced by lower density bone surrounding the implant and osteoporotic bone conditions (45). This becomes more problematic in those patients who have been administered bisphosphonates in the past or are currently being prescribed these drugs. LMHFV (120 Hz) has demonstrated positive effects on bone quality and quantity in this specific bone micro-environment (15). LMHFV (120 Hz) may have applications to support extraction socket healing when no implant is planned to mitigate the risk of osteonecrosis of the jaw (ONJ) associated with any invasive procedure involving bone among bisphosphonate patients.

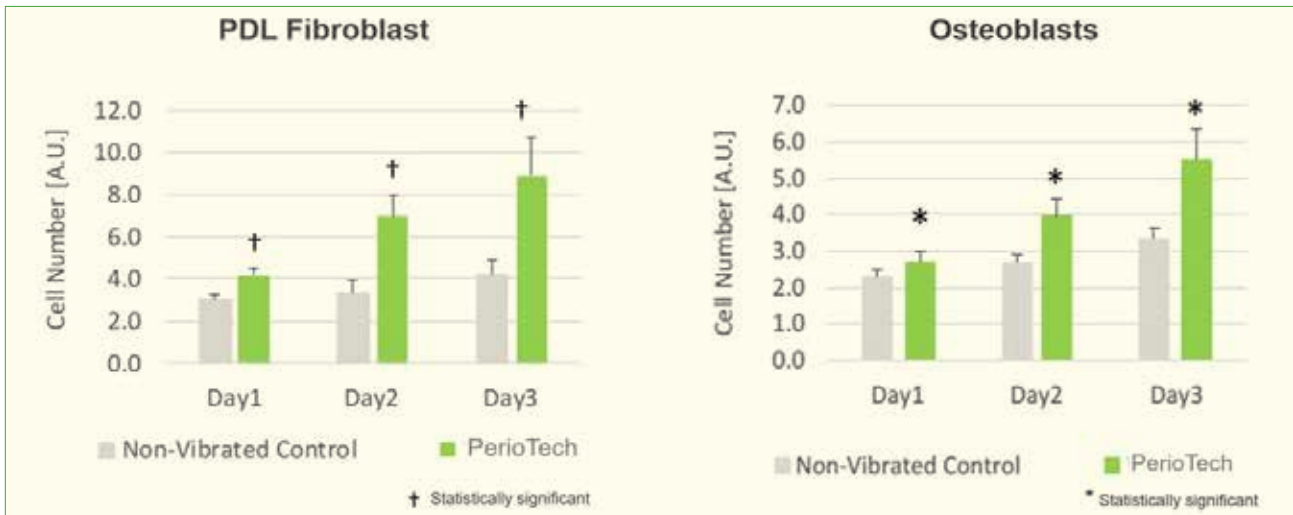


FIG. 19 Comparison of PDL fibroblast and osteoblasts between non-vibrated control and LMHFV 120 Hz (PerioTech) over a 3-day period demonstrating statistically significant increases with the LMHFV (41).

When 120 Hz HFV is prescribed 5 minutes daily at the time of implant placement with either a delayed or immediate load protocol, an increase in the density of the bone-implant interface yields higher quality bone to support the implant and improve load handling under function. This also is an adjunct to treatment of peri-implantitis, improving bone density, which will improve load handling and stabilize the bone level and potentially increase the bone level around the implant. In those situations where grafting is part of the peri-implantitis treatment, LMHFV aids in accelerating graft conversion and improvement of bone density via stimulation of growth factors, osteogenic cells and angiogenesis.

Patients presenting with tooth mobility (grade I and I+) following elimination of contributory occlusal factors, benefit from adjunctive HFV to improve bone density and PDL fibroblast proliferation. This accelerated PDL remodeling supported by decreased PDL width and increased alveolar bone density reduces mobility in a non-invasive home-based treatment that reduces office visits and has the potential to save teeth otherwise condemned to extraction (46).

CONCLUSION

LMHFV has been utilized in orthodontics for a number of years to accelerate tooth movement and improve the bone housing those teeth. Applications of this technology have extended to other areas of dentistry. Under normal conditions osseous healing is affected by a multitude of factors, which include the patient's age, gender, medical health, and what medications they are currently taking or have taken in the recent past. Periodontal health affects the teeth, bone and PDL with decreases in bone density of the maxilla and mandible leading to tooth mobility or

challenges to implant placement that may necessitate grafting.

LMHFV has demonstrated an ability to increase bone density, stimulate growth factors increasing osteoblastic activity and angiogenesis accelerating graft conversion to host bone to allow earlier implant placement. Utilization with teeth presenting with mobility (grade I and I+) following elimination of contributory occlusal factors, with improvement in bone density and PDL space width will decrease, and mobility will be eliminated by stimulation of PDL fibroblasts. LMHFV is currently the only method that has demonstrated an ability to improve tooth mobility yielding a decrease in PDL width and an increase in bone density surrounding the tooth in question.

When utilized at implant placement with either a delayed or immediate load protocol, an increase in the density of the bone-implant interface yields higher quality bone to support the implant and improve load handling under function. This also is an adjunct to treatment of peri-implantitis, improving bone density, which will improve load handling and stabilize the bone level and potentially increase the bone level around the implant. In those situations where grafting is part of the peri-implantitis treatment, LMHFV aids in accelerating graft conversion and improvement of bone density via stimulation of growth factors, osteogenic cells and angiogenesis.

In summary, LMHFV (120 Hz) can be used in patients with tooth mobility to accelerate PDL remodeling, to prevent bone loss and improve bone quantity and quality. Additionally, LMHFV (120 Hz) allows earlier implant placement following extraction based on upregulated endogenous growth factors, accelerated new blood vessel formation and significantly increased bone density. It has also been shown to improve primary and secondary stability allowing earlier implant loading

through accelerated graft conversion to mature bone, increased trabecular thickness and decreased alveolar space resulting in an improved bone to implant contact. In those patients with dental implants diagnosed as ailing due to the complications of peri-implantitis LMHFV (120 Hz) will prevent further bone loss and improve bone quantity and quality, allowing rescue of the ailing implant.

REFERENCES

- Crockett JC, Rogers MJ, Coxon FP, Hocking LJ, Helfrich MH. Bone remodelling at a glance. *J Cell Sci* 2011 Apr 1;124(Pt 7):991-8.
- Noble WH, Martin LP. Tooth mobility changes in response to occlusal interferences. *J Prosthet Dent* 1973 Oct;30(4 Pt 1):412-7.
- Carter DR. Mechanical loading histories and cortical bone remodeling. *Calcif Tissue Int* 1984;36 Suppl 1:S19-24.
- Glowacki J. Angiogenesis in fracture repair. *Clin Orthop Relat Res* 1998;(355 Suppl):S82-S89.
- Hulth A. Current concepts of fracture healing. *Clin Orthop Relat Res* 1989;(249):265-284.
- Caplan AI. Mesenchymal stem cells. *J Orthop Res* 1991;9(5):641-650.
- Claes LE, Heigele CA, Neidlinger-Wilke C et al. Effects of mechanical factors on the fracture healing process. *Clin Orthop Relat Res* 1998;(355 Suppl):S132-S147.
- Phillips AM. Overview of the fracture healing cascade. *Injury*.2005;36 Suppl 3:S5-S7.
- Chao EY, Inoue N. Biophysical stimulation of bone fracture repair, regeneration and remodelling. *Eur Cell Mater* 2003;6:72-85.
- Xie L, Jacobson JM, Choi ES et al. Low-level mechanical vibrations can influence bone resorption and bone formation in the growing skeleton. *Bone* 2006;39(5):1059-1066.
- Garman R, Gaudette G, Donahue LR, Rubin C, Judex S. Low-level accelerations applied in the absence of weight bearing can enhance trabecular bone formation. *J Orthop Res* 2007;25(6):732-740.
- Judex S, Rubin CT. Is bone formation induced by high-frequency mechanical signals modulated by muscle activity? *J Musculoskelet Neuronal Interact* 2010;10(1):3-11.
- Gilsanz V, Wren TA, Sanchez M, Dorey F, Judex S, Rubin C. Low-level, high-frequency mechanical signals enhance musculoskeletal development of young women with low BMD. *J Bone Miner Res* 2006;21(9):1464-1474.
- Rubin C, Recker R, Cullen D, Ryaby J, McCabe J, McLeod K. Prevention of postmenopausal bone loss by a low-magnitude, high-frequency mechanical stimuli: a clinical trial assessing compliance, efficacy, and safety. *J Bone Miner Res* 2004;19(3):343-351.
- Alikhani M, Alikhani M, Alansari S et al. Therapeutic effect of localized vibration on alveolar bone of osteoporotic rats. *PLoS One* 2019;14(1):e0211004.
- Shi HF, Cheung WH, Qin L, Leung AH, Leung KS. Low-magnitude high-frequency vibration treatment augments fracture healing in ovariectomy-induced osteoporotic bone. *Bone* 2010;46(5):1299-1305.
- Chung SL, Leung KS, Cheung WH. Low-magnitude high-frequency vibration enhances gene expression related to callus formation, mineralization and remodeling during osteoporotic fracture healing in rats. *J Orthop Res* 2014;32(12):1572-1579.
- Chow DH, Leung KS, Qin L, Leung AH, Cheung WH. Low-magnitude high-frequency vibration (LMHFV) enhances bone remodeling in osteoporotic rat femoral fracture healing. *J Orthop Res* 2011;29(5):746-752.
- Wei FY, Chow SK, Leung KS, et al. Low-magnitude high-frequency vibration enhanced mesenchymal stem cell recruitment in osteoporotic fracture healing through the SDF-1/CXCR4 pathway. *Eur Cell Mater* 2016;31:341-354.
- Fan J, Caton JG. Occlusal trauma and excessive occlusal forces: Narrative review, case definitions, and diagnostic considerations. *J Periodontol* 2018;89.
- Branschofsky M, Beikler T, Schäfer R, Flemming TF, Lang H. Secondary trauma from occlusion and periodontitis. *Quintessence Int* 2011;42(6):515-522.
- Singh A, Sharma RK, Tewari S, Narula SC. Correlation of tooth mobility with systemic bone mineral density and periodontal status in Indian women. *J Oral Sci* 2012;54(2):177-182.
- Pepelassi E, Nicopoulou-Karayianni K, Archontopoulou AD et al. The relationship between osteoporosis and periodontitis in women aged 45-70 years. *Oral Dis* 2012;18(4):353-359.
- Alikhani M, Sangsuwon C, Alansari S, Nervina JM, Teixeira CC. High Frequency Acceleration: A new tool for alveolar bone regeneration. *JSM Dent Surg* 2017;2(4):1026.
- Alikhani M, Khoo E, Alyami B et al. Osteogenic effect of high-frequency acceleration on alveolar bone. *J Dent Res* 2012;91(4):413-419.
- Hao Y, Zhao W, Wang Y, Yu J, Zou D. Assessments of jaw bone density at implant sites using 3D cone-beam computed tomography. *Eur Rev Med Pharmacol Sci* 2014;18(9):1398-1403.
- Horowitz R, Holtzclaw D, Rosen P. A review on alveolar ridge preservation following tooth extraction. *J Evid Base Dent Pract* 2012; 12(3); 149-160.
- Araujo MG, Lindhe J. Dimensional ridge alterations following tooth extraction. An experimental study in the dog. *J Clin Periodontol* 2005; 32(2): 212-218.
- Alikhani M, Lopez JA, Alabdullah H et al. High-Frequency Acceleration: Therapeutic tool to preserve bone following tooth extractions. *J Dent Res* 2016;95(3):311-318 [published correction appears in *J Dent Res* 2016 Jul;95(8):956].
- Becker W, Huijoe PP, Becker BE, Willingham H. Osteoporosis and implant failure: an exploratory case-control study. *J Periodontol* 2000;71(4):625-31.
- Jaffin RA, Berman CL. The excessive loss of Branemark fixtures in type IV bone: a 5-year analysis. *J Periodontol* 1991; 62(1):2-4.
- Brennan SA, Brabazon D, O'Byrne JM. Effect of vibration on the shear strength of impacted bone graft in revision hip surgery. *J Bone Joint Surg Br* 2011;93(6):755-759.
- Bolland BJ, New AM, Madabhushi SP, Oreffo RO, Dunlop DG. Vibration-assisted bone-graft compaction in impaction bone grafting of the femur. *J Bone Joint Surg Br* 2007;89(5):686-692.
- Turkylmaz I, McGlumphy EA. Influence of bone density on implant stability parameters and implant success: a retrospective clinical study. *BMC Oral Health* 2008;8:32. Published 2008 Nov 24.
- Akca K, Sarac E, Baysal U, Fanuscu M, Chang TL, Cehreli M. Micro-morphologic changes around biophysically-stimulated titanium implants in ovariectomized rats. *Head Face Med* 2007;3:28. Published 2007 Jul 16.
- Wang S, Ogawa T, Zheng S et al. The effect of low-magnitude high-frequency loading on peri-implant bone healing and implant osseointegration in Beagle dogs. *J Prosthodont Res* 2018;62(4):497-502.
- Ogawa T, Vandamme K, Zhang X et al. Stimulation of titanium implant osseointegration through high-frequency vibration loading is enhanced when applied at high acceleration. *Calcif Tissue Int* 2014;95(5):467-475.
- Ogawa T, Possemiers T, Zhang X, et al. Influence of whole-body vibration time on peri-implant bone healing: a histomorphometrical animal study. *J Clin Periodontol* 2011;38(2):180-185.
- Chen B, Lin T, Yang X, et al. Low-magnitude, high-frequency vibration promotes the adhesion and the osteogenic differentiation of bone marrow-derived mesenchymal stem cells cultured on a hydroxyapatite-coated surface: The direct role of Wnt/ β -catenin signaling pathway activation. *Int J Mol Med* 2016;38(5):1531-1540.
- De Smet E, Jaecques SV, Jansen JJ, Walboomers F, Vander Sloten J, Naert IE. Effect of constant strain rate, composed of varying amplitude and frequency, of early loading on peri-implant bone (re)modelling. *J Clin Periodontol* 2007;34(7):618-624.
- Schwarz F, Derks J, Monje A, Wang HL. Peri-implantitis. *J Periodontol* 2018;89 Suppl 1:S267-S290.
- Smeets R, Henningsen A, Jung O, Heiland M, Hammächer C, Stein JM. Definition, etiology, prevention and treatment of peri-implantitis--a review. *Head Face Med* 2014;10:34. Published 2014 Sep 3.
- Shipty T, Farouk K, El-Bialy T. Effect of high-frequency vibration on orthodontic tooth movement and bone density. *J Orthod Sci* 2019;8:15.
- Judex S, Pongkitwitoon S. Differential efficacy of 2 vibrating orthodontic devices to alter the cellular response in osteoblasts, fibroblasts, and osteoclasts. *Dose Response* 2018;16(3):1559325818792112. Published 2018 Aug 16.
- Zhang X, Vandamme K, Torcasio A et al. In vivo assessment of the effect of controlled high- and low-frequency mechanical loading on peri-implant bone healing. *J R Soc Interface* 2012;9(72):1697-1704.
- Chatterjee M, Hatori K, Duyck J, Sasaki K, Naert I, Vandamme K. High-frequency loading positively impacts titanium implant osseointegration in impaired bone. *Osteoporos Int* 2015;26(1):281-290.