

The use of grafting material biphasic calcium sulfate for the treatment of osseous defects resulting from radicular cysts. Clinical study and six-month follow up

➤ **D. DUDEK^{1,2}, E. REICHMANN-WARMUSZ², G. M. KURTZMAN³, L. MAHESH⁴**

¹Ambulatory Oral Surgery and Implantology, Thorn, Poland

²Department of Histology and Cell Pathology in Zabrze, School of Medicine with the Division of Dentistry, Medical University of Silesia in Katowice, Poland

³Private practice, Silver Spring, Maryland, USA

⁴Bds, Mba, Private practice, New Delhi, India

TO CITE THIS ARTICLE

Dudek D, Reichmann-Warmusz E, Kurtzman GM, Mahesh L. The use of grafting material biphasic calcium sulfate for the treatment of osseous defects resulting from radicular cysts. Clinical study and six-month follow up. *J Osseointegr* 2020;12(4):716-721.

DOI 10.23805 /JO.2020.12.02.18

KEYWORDS Biphasic calcium sulfate; Bone graft; Odontogenic cyst; Wound dehiscence.

ABSTRACT

Aim Surgical treatment of odontogenic cysts of the jaws accounts for a significant percentage of dental surgery procedures. Additionally, a wide range of procedures and augmentation materials are used in the reconstruction of these osseous defects. The authors present a study including histology of surgical treatment of odontogenic cysts using a biphasic calcium sulfate composite bone graft.

Materials and methods Two groups, study and control, of 30 patients each with odontogenic cyst were treated for radicular cyst removal with reconstructive surgery using a deproteinized bovine bone graft (xenograft). A modified surgical procedure was performed in the control group, with different types of graft placed in the osseous defects. In the study group wound site closure was performed without periosteum cutting to allow stretching of the flap to attempt primary site closure, whereas in the control group primary wound closure was achieved to protect the xenograft material.

Results In the study group complete wound healing and suture maintenance was reported in 29 patients (96.6%); in 1 case (3.4%), a postoperative wound dehiscence (I°) occurred on day 5. In the control group no wounds dehiscences were observed in 24 patients (80%), in 4 cases (12%) a wound dehiscence (I°) occurred on day 3 and 5 and in 2 cases (8%), II° wound dehiscence over 10 mm with secondary inflammatory features were observed which required graft removal.

Conclusions The use of the Bond Apatite® preparation proved to be a simple, inexpensive and effective reconstructive treatment of osseous defects after enucleation of odontogenic cysts.

INTRODUCTION

It has been estimated that radicular cysts may constitute on average 40–80% of pathological lesions in maxilla and mandible in the general population (1–5). A large number of patients with confirmed odontogenic cysts are treated surgically to remove identified radicular cysts. There are various procedures, such as decompression, marsupialization and of course enucleation that require the use of various biomaterials for the reconstruction of the resulting osseous defect. Reconstructive techniques may present different levels of required technical skill: those requiring flap elevation/extension, using various membranes (resorbable and non-resorbable), pins or screws to fixate the membranes and complicated suture techniques often can represent a challenge for the surgeon. Intra and postoperative complications may also result. Surgical procedures aim to minimize invasiveness while maximizing effectiveness for the patient (6). Therefore, the authors have attempted to assess the clinical efficacy of Bond Apatite® (Augma Biomaterials, USA) in the regeneration of maxillary bone defects following surgical removal of radicular cysts.

MATERIALS AND METHODS

Thirty consecutive patients who were referred for planned oral surgery were enrolled in the study. All patients had a clinical examination and standard radiographs confirming the initial diagnosis of odontogenic cyst. The exclusion criteria included: lack

of patient consent for use of Bond Apatite® preparation (Augma Biomaterials®). A control group of 30 patients was selected, who were also treated for radicular cyst removal with reconstructive surgery using deproteinized bovine bone grafts (xenograft). All surgical procedures were performed under local anesthesia (4% Articaine with 1:200,000 epi) or intravenous sedation.

In the study group, following flap elevation, a drilling hole was created and the cyst was removed atraumatically, then sent for histopathological examination. In addition, resection of the apical 3 mm of the affected root was performed or the root was atraumatically extracted. Based on previous experience, following root resection a 3 mm retrograde root canal preparation was created and a retrograde fill was placed with MTA® (Mineral Trioxide Aggregate®). The residual osseous defect was then filled with Bond Apatite® graft material in accordance with the manufacturer's instructions. Bond Apatite® is composed of a biphasic calcium sulfate and synthetic hydroxyapatite granules. The material consists of micro needle-shaped crystals of calcium sulfate and macro hydroxyapatite grains. When the graft is activated, there is a strong reaction between hydroxyapatite and calcium sulfate. This graft material goes through setting as it encounters saline and setting results within a few minutes, resulting in a cement-like material. The wound site closure was performed without periosteum cutting to allow stretching of the flap to attempt primary site closure in the study group.

In the control group primary wound closure was achieved to protect the xenograft material. Sites were fixated with single sutures of resorbable (polydioxanone, a biodegradable synthetic polymer) or non-resorbable (nylon) sterile monofilament 4-0 to 6-0 sutures. The resorbable suture was on a round ½ circle needle and the non-resorbable suture was on a reverse 3/8 circle cutting needle. A total of 33 cysts were enucleated in the study group, including 28 root resections and 12 root extractions (Table 1).

A modified surgical procedure was performed in the control group, with different types of graft placed into the osseous defects (Table 3). Furthermore, the surgical technique included flap extension with periosteum cutting for a vertical releasing incision and covering the grafted area with a collagen membrane prior to site closure. Different grafting materials were used and when deproteinized bovine bone particles (xenograft) were

Quantity of patients	n = 30
Age (years) Mean age (years)	28 – 68 55.6
Gender F/M	16/14
Range of diameter of the cyst min/max (mm) Mean (mm)	9-35 13.8
Topography maxilla/mandible	19/14
Front segment of the maxilla	10
Lateral segment of the maxilla	9
Front segment of the mandible	3
Lateral segment of the mandible	11
Resection of the root	28
Extraction of the root	12
Quantity of graft (cc)	40

TABLE 1 Patient characteristics of the study group.

Quantity of patients	n = 30
Age (years) Mean age (years)	27 – 65 61.1
Gender F/M	16/14
Range of diameter of the cyst min/max (mm) Mean (mm)	10-40 14.6
Topography maxilla/mandible	17/14
Front segment of the maxilla	12
Lateral segment of the maxilla	5
Front segment of the mandible	7
Lateral segment of the mandible	7
Extraction of the root	42
Quantity of graft (cc)	47

TABLE 2 Patient characteristics of the control group.

used, they were mixed with either blood at the surgical site or PRF (Platelet Rich Fibrin). The membrane was stabilized with titanium pins. A total of 31 cyst enucleations were carried out, with 42 root extractions (Table 2).

Clindamycin, with a loading dose of 1.2 g per os, was administered to all patients 2 hours before surgery and followed by 7 days oral administration. Patients were also prescribed a non-steroidal anti-inflammatory drug (Ketoprofen or Paracetamol). Local status of the surgical area was evaluated at recall post-surgically using a three-point scale as follows.

- 0: wound healing and maintaining sutures proceeds

Type	Sum of cases	Maxilla	Mandible	Quantity of graft(cc)
Putty®Osteobiol®a	10	6	4	12
MP3®Osteobiol®b	7	8	9	10
Gen-os® Osteobiol®c	10	4	6	15
Cerabone®Botiss Dental®d	3	1	2	10

TABLE 3 Grafts used in the control group (a= heterologous <80%> 300 micron prehydrated bone in a collagen gel, b= heterologous 600-1,000 micron prehydrated cortico-cancellous granules in a collagen gel, c= autogenous bone and d= xenograft)

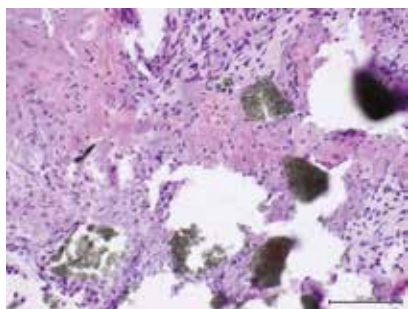


FIG. 1 Histology after 3 months shows visible new young bone formation (dark purple spots) and residual Bond Apatite (dark areas) that is converting to bone without inflammatory reaction (100x).

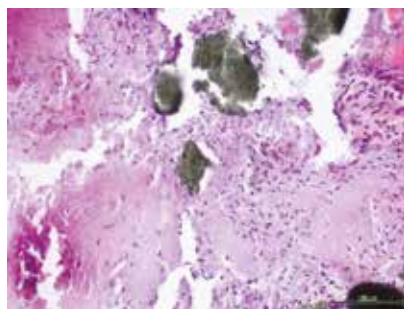


FIG. 2 Another histology sample demonstrating Bond Apatite (dark areas) and new bone (dark purple spots) (Hematoxylin and eosin staining, 100x).

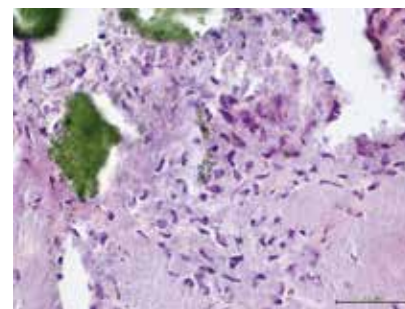


FIG. 3 At higher magnification (200x), new bone (dark purple spots) and residual Bond Apatite (green areas) is observed without any inflammatory cells.

correctly.

- I°: wound dehiscence up to 10 mm without second inflammatory features, use of local pharmacology.
- II°: wound dehiscence over 10 mm and second inflammatory features, leaving the wound healed by granulation or need for additional surgery and removal of the graft.

Discomfort and postoperative pain were tested using the VAS scale (100 mm long where 0 mm means no pain and 100 mm the strongest possible pain). Control visits were carried out at 1, 3, 5 and 7 days post-surgically. Sutures were removed at 7 days post-surgery. Control radiographs were performed 7 days, 3 months and 6 months after surgical treatment.

RESULTS

In 29 patients, 96.6% (16 women and 13 men) complete wound healing and suture maintenance was reported. In 1 case, 3.4% (1 men) a postoperative wound dehiscence (I°) occurred on day 5, which was allowed to heal by granulation (secondary intention) and was supported by local pharmacology (chlorhexidine rinses 3 times daily). The wound closed after 3 weeks without any graft loss. In the control group, no wounds dehiscences were observed in 24 patients, 80% (14 women and 10 men). But, in 4 cases, 12% (2 men and 2 women), a wound dehiscence (I°) occurred on day 3 and 5, which was left to heal by granulation and was supported by local pharmacology for the subsequent 3 weeks. The wounds also closed after 2-3 weeks without loss of the graft material. In 2 cases, 8% (2 men), II° wound dehiscence over 10 mm with secondary inflammatory features were observed. In both of these cases, it was necessary to remove the graft. In the assessment of post-operative discomfort and pain, VAS values in the range of 20-40 mm (mean 33) were recorded (1-3 day after surgery), while in the control group the values given by the patients were a little higher, in the range of 30-60 mm

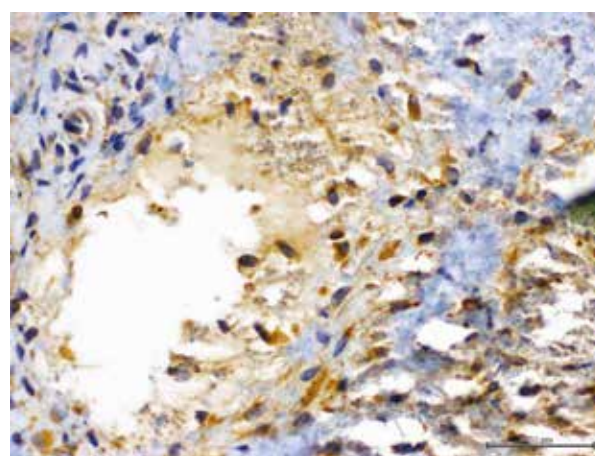


FIG. 4 Immunohistochemical study CD 68, a surface antigen used for detection of bone cells, demonstrates active osteoblasts in the tissue and little remaining Bond Apatite® (green).

(mean 42), 1-7 day after surgery. Moreover, radiographic images taken after 7 days, three and six months showed normal osseous remodeling and graft consolidation in the study group. Also, in the control group osseous tissue remodeling was slightly slower when examined radiographically at the same time points.

Regarding what happened to the Bond Apatite® graft material and its replaced by host bone over time, histologically, in the specimens in the study group over time the particles of Bond Apatite® wereresorbed and replaced with new bone. Samples examined at 3 months found that at 100x magnification some residual particles of Bond Apatite® remained (dark areas), but they were connected to active bone (dark purple spots) with absence of inflammatory reaction (Fig. 1). Hematoxylin and eosin staining of the histological samples clearly demonstrates new bone in contact with the residual Bond Apatite® particles (Fig. 2).

At higher magnification (200x) a lack of inflammatory cells was noted with direct contact between the new

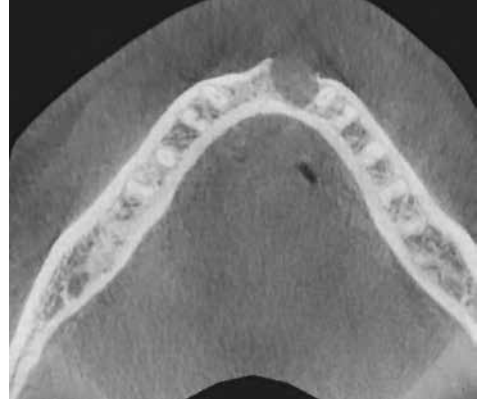
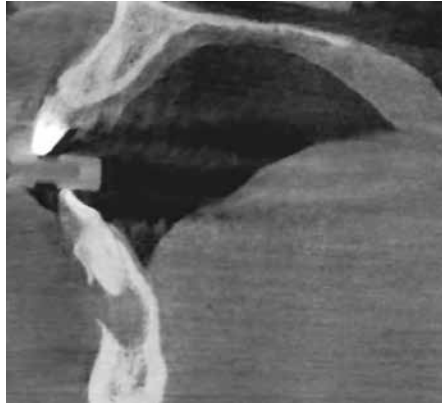
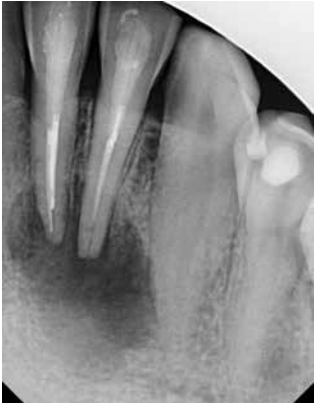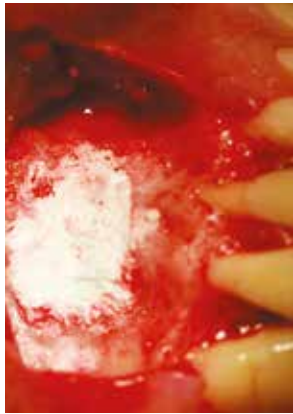

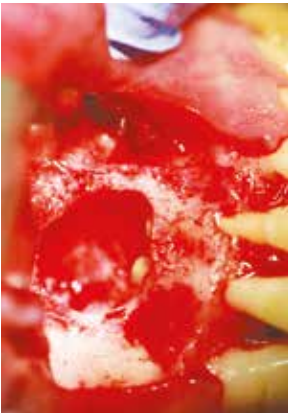
FIG. 5 Periapical radiograph with lesion associated with prior endodontic treatment on the left mandibular lateral and central incisors.

FIG. 6 CBCT cross section demonstrating the size of the odontogenic cyst associated with the failing endodontic teeth in the mandibular anterior, with lack of facial plate noted.

FIG. 7 CBCT axial slice demonstration destruction of the facial plate related to the odontogenic cyst present.



bone and Bond Apatite® residual particles (Fig. 3). At 6 months post-surgery, an immunohistochemical CD 68 study, which is a surface antigen used for detection of bone cells, demonstrated active osteoblasts in the grafted osseous tissue, with little remaining Bond Apatite® (green) (Fig. 4). This supports previously reported studies that although Bond Apatite® forms a cement-like material upon setting, the graft material is replaced over several months with new active bone that contains osteoblasts with few particles remaining at about 6 months.

FIG. 8: Size of the defect following enucleation of the odontogenic cyst, root resection and retrograde filling.

FIG. 9 Bond Apatite® placement to fill the large osseous defect.

CASE REPORT

A 40-year old healthy male patients, with a cyst in the anterior mandible with a fistula, reported daily pain

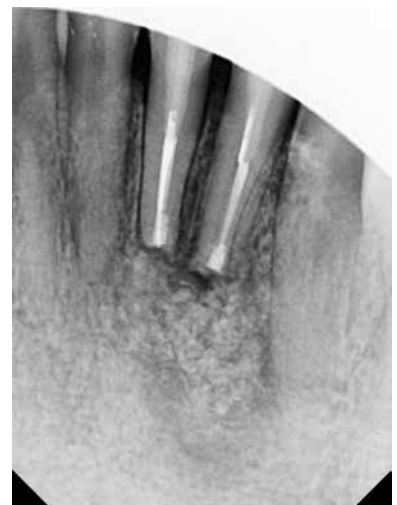
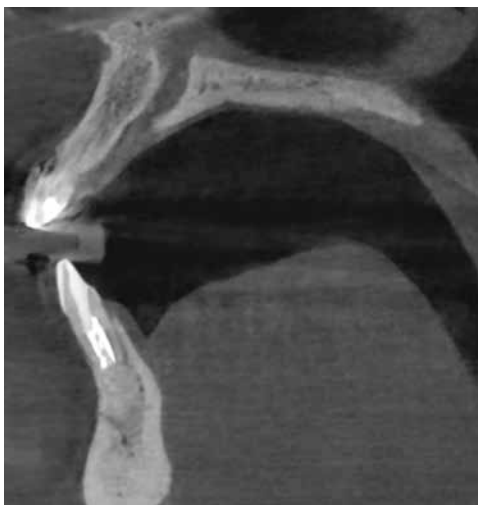
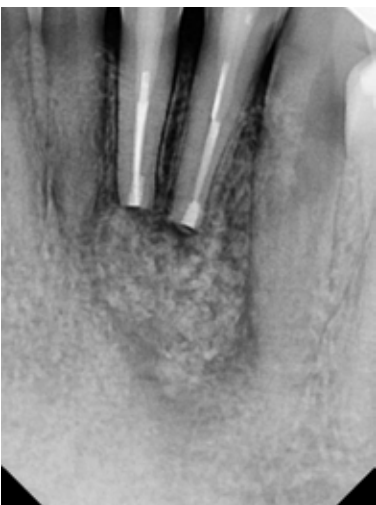
FIG.10 Periapical radiograph immediately following surgery to document the retrograde fillings in the two roots and the defect filled with Bond Apatite®.

FIG. 11 CBCT cross section at 7 days post surgery to document the fill of the defect and restoration of the osseous contour of the facial plate with the graft .

FIG.12 Periapical radiograph at 3 months post surgery.

and discomfort. A periapical radiograph showed a large bone defect associated with two failing endodontically treated teeth. Both teeth presented insufficient obturation leading to the lesion and subsequent fistula (Fig. 5). CBCT showed loss of a large area of the facial plate of the anterior mandible related to the ongoing enlargement of the cyst (Fig. 6). The axial slice of the CBCT, demonstrated destruction and loss of the facial plate at the large cyst (Fig. 7).

Following flap elevation to expose the cyst, the latter was enucleated and sent for histopathological examination. The apical side of both teeth involved was resected and a retro preparation was made and filled with MTA in both root apices (Fig. 8). Bond Apatite® was activated within its syringe and the defect was filled with approximately 1 cc of graft material, filling the defect to the facial contour of the adjacent unaffected bone (Fig. 9). The flap was closed and sutures placed. A periapical radiograph was taken to document the apical retro fillings and defect filled with graft material (Fig. 10).

The patient returned 7 days post-surgery for suture removal and a CBCT was taken. The cross section view demonstrated the defect to be filled with graft material and the contour had been restored (Fig. 11). Re-evaluation at 3 months post-surgery demonstrated on a periapical radiograph a blending of the graft material and new bone replacing it (Fig. 12). At the 6 month evaluation, a new CBCT cross section showed that the facial contour remained with the adjacent unaffected bone and the graft was replaced with bone similar in radiographic appearance to the native bone (Fig. 13). The axial slice view demonstrated reconstruction of the prior lost facial plate with replacement with new host bone (Fig. 14).

DISCUSSION

This study demonstrates that using Bond Apatite® preparation in the group with odontogenic cysts is safe and effective in this cohort of patients. In addition, clinical efficacy is comparable to other osseous grafts in the control group. Various biomaterials are used in procedures for the reconstruction of the maxilla and mandible. However, the biochemical structure of the Bond Apatite® and its simple application procedure minimizes the risk of secondary wound infection and graft loss (7,8).

Similarly to our study, Baranes and Kurtzman, have also reported good clinical effectiveness of Bond Apatite® in various jaw bone defects. They recommended that Bond Apatite® provides added benefits clinically. The current findings are comparable to those reported by Turri and Dahlin in an experimental study in the rabbit (10). The aim of their study was to histologically compare dynamics of bone healing with calcium sulfate and deproteinized bovine bone in 18 rabbit maxillae

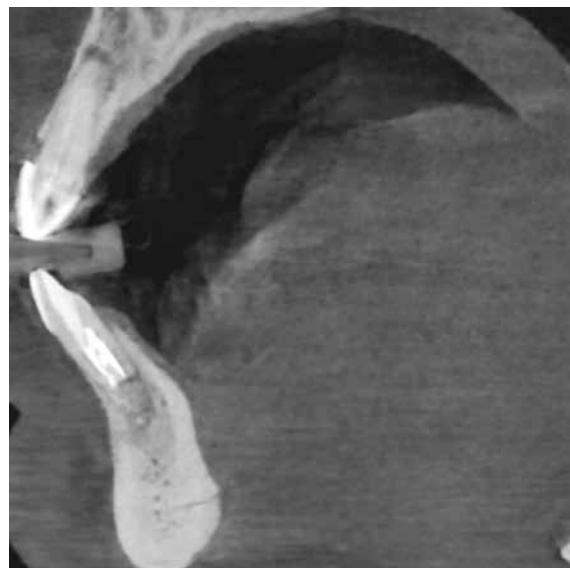


FIG. 13 CBCT cross section at 6 months demonstrating replacement of the Bond Apatite® with new host bone maintaining the facial contour of the mandible that was affected by the lesion.

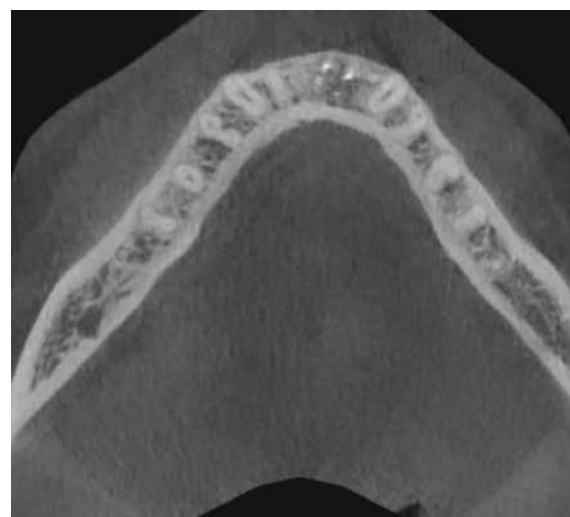


FIG. 14 CBCT axial view demonstrating at 6 months the facial contours restored by osseous grafting of the large defect with Bond Apatite®.

with healing evaluated at 2, 4 and 8 weeks by histology. They reported that the group with calcium sulfate demonstrated significantly more bone regeneration at all healing periods compared to the bovine bone group. Moreover, the authors concluded that calcium sulfate in combination with an extracellular matrix membrane provided synergistic effects of bone regeneration, seemingly due to stimulating angiogenesis in the early healing process.

Furthermore, in a clinical study by Schindler et al. calcium sulfate combined with hydroxyapatite in orthopedic surgery was used (11) on 13 patients, treated due to large aneurysmal bone cysts (6 cases) and giant

cell tumors (7 cases) located in the epi- or meta-physeal areas of the lower limbs. According to the authors, composite bioceramic osteoconductive grafts, which combine porous hydroxyapatite with calcium sulphate, provided a framework for human osteogenesis and avoided donor-site morbidity, frequently found with autologous bone graft harvesting.

CONCLUSION

The data presented in this study and a few previous reports support the continuation of use of Bond Apatite® formulation for reconstructive oral surgery procedures. Such use, reduces the time and cost of osseous grafting of the resulting defect, but also increases patient comfort related to the elimination of flap mobilization that would be required with wound closure by primary intention. Moreover, the use of biphasic calcium sulfate combined with hydroxyapatite preserves the overall goal to maintain the shape of the osseous contours following cyst enucleation in those patients. As demonstrated by our observations, mastering local inflammatory complications is most effective in an outpatient setting. In addition, the widespread use of such materials in other areas of surgery, such as in orthopedics, also speaks for the use of Bond Apatite® graft in the reconstruction of large bone defects.

Finally, use of Bond Apatite® preparation is a simple, inexpensive and effective reconstructive treatment of osseous defects after enucleation of odontogenic

cysts. With long-term observations of the study group it might also be possible to evaluate the efficacy of the Bond Apatite® in the reconstruction of large osseous defects.

REFERENCES

1. Nakamura T et al. A study of cysts in the oral region. Cysts of the jaw. *J Nihon Univ Sch Dent* 1995 Mar;37(1):33-40.
2. Oji C. Statistical observations on jaw cysts in Enugu, Nigeria, 1987-1996. *Odontostomatol Trop* 1999 Mar;22(85):33-6.
3. Johnson NR, Gannon OM, Savage NW, Batstone MD. Frequency of odontogenic cysts and tumors: a systematic review. *J Investig Clin Dent* 2014 Feb;5(1):9-14.
4. Tortorici S, Amodio E, Massenti MF, Buzzanca ML, Burruano F, Vitale F. Prevalence and distribution of odontogenic cysts in Sicily: 1986-2005. *J Oral Sci* 2008 Mar;50(1):15-8.
5. Grossman SM et al. Demographic profile of odontogenic and selected nonodontogenic cysts in a Brazilian population. *Oral Surg Oral Med Oral Pathol Oral Radiol Endod* 2007 Dec;104(6):e35-41. Epub 2007 Oct 17.
6. Maiorana C, Poli PP, signorino F, runza I, Beretta M. are dental implants the first option in case of severely compromised teeth associated with radicular cyst? a critical case report. *J Osseointegr* 2020;12(2).
7. Machtei EE, Mayer Y, Horowitz J, Zigdon-Giladi H. Prospective randomized controlled clinical trial to compare hard tissue changes following socket preservation using alloplasts, xenografts vs no grafting: Clinical and histological findings. *Clin Implant Dent Relat Res*. 2019; 21: 14-20.
8. Atilgan S et al. An experimental comparison of the effects of calcium sulfate particles and β -tricalcium phosphate/hydroxyapatite granules on osteogenesis in internal bone cavities. *Biotechnol & Biotechnol EQ* 2007; 21: 205-210.
9. Baranes D, Kurtzman GM. Biphasic Calcium Sulfate as an alternative grafting material in various dental applications. *J Oral Implantol* 2019 May 1. doi: 10.1563/aid-joi-D-18-00306.
10. Turri A, Dahlin C. Comparative maxillary bone-defects healing by calcium-sulfate or deproteinized bovine bone particles and extra cellular matrix membranes in a guided bone regeneration setting: an experimental study in rabbits. *Clin Oral Impl Res* 2014; 0: 1-6.
11. Schindler OS, Cannon RS, Briggs TWR, Blunn GW. Composite ceramic bone graft substitute in the treatment of locally aggressive benign bone tumors. *J Orthop Surg* 2008; 16(1): 66-74.