

> F.S. MARCHIONNI<sup>1-2</sup>, F. ALFONSI<sup>1</sup>, S. SANTINI, S. MARCONCINI, U. COVANI, A. BARONE<sup>1-2</sup>

Tuscan Stomatologic Institute, Versilia General Hospital, Lido di Camaiore, Italy

<sup>1</sup>Department of Surgical, Medical, Molecular and of the Critical Area Pathology, University of Pisa, Italy

<sup>2</sup>Unit of Dentistry and Oral Surgery, University-Hospital of Pisa, Italy

## Maxillary sinus augmentation: collagen membrane over the osteotomy window. A pilot study

### TO CITE THIS ARTICLE

Marchionni FS, Alfonsi F, Santini S, Marconcini S, Covani U, Barone A. Maxillary sinus augmentation: collagen membrane over the osteotomy window. A pilot study. *J Osseointegr* 2015;7(1):15-20.

### ABSTRACT

**Aim** Implant rehabilitation has become a very reliable and safe procedure. However, in some cases, a small amount of bone could make implant surgery extremely difficult or even impossible. Hence, a surgical technique to augment sinus floor has been developed and improved. Nevertheless, there is still controversy over the use of a membrane over the osteotomy window. Therefore, the aim of this study was to investigate whether the use of a membrane could be beneficial in sinus floor augmentation.

**Materials and methods** A group of 12 patients requiring sinus floor lift were recruited. The patients were randomly allocated to either control group (membrane) or test group (no membrane) and only one sinus for patient was augmented. After 6 months, a bone biopsy was harvested from the lateral window to be processed for histological analysis.

**Results** The mean amount of newly formed bone in test group was  $28.0 \pm 19.5\%$ , the connective tissue accounted for a mean value of  $59.2 \pm 15.6\%$ , while  $12.8 \pm 12.6\%$  was the amount of residual graft particles. In the membrane group the newly formed bone counted for a mean value of  $30.4 \pm 15.8\%$ , the mean quantity of connective tissue was  $50.3 \pm 18.9\%$  and about residual graft particles a mean value of  $18.2 \pm 20.4\%$  was registered.

**Conclusion** According to our data, the use of a membrane over the lateral bone wall in sinus lift surgery does not significantly influence healing. However, the membrane could influence the residual particles resorption rate as well as soft tissue ingrowth.

**KEYWORDS** Sinus; Floor; Augmentation; Lift; Membrane; Xenograft.

### INTRODUCTION

Following tooth extraction, alveolar ridge undergoes marked changes both in width and in height (1). This could make the prosthetic implant rehabilitation

extremely hard for the oral surgeon, especially in posterior maxillary regions in which great care must be taken to avoid maxillary sinus lesions (2).

In order to overcome this problem, in the '80s some authors described different methods for bone augmentation of the sinus floor (3, 4) and since the modified Cadwell-Luc technique by Tatum (1986), several modifications have been proposed in the literature (5, 6, 7, 8).

Regarding graft materials, autologous bone and bone substitutes are the two types of available materials with the strongest literature support in sinus augmentation. However, there is not a clear evidence on the superiority of one over the other (9, 10). In fact, autologous bone grafts have excellent osteoinductive, osteoconductive and osteogenic properties, but also some limitations such as graft availability, risk of infection, the possibility of morbidity of the donor site, sensitivity disturbances and unpredictable resorption rate (11, 12, 13). On the other hand, bone substitutes such as bovine bone and porcine bone, seem to fulfill many of the properties of autologous bone (e.g. remarkable osteoconductivity and ability to allow revascularization) without having its disadvantages (14, 32), thereby gaining clinicians' attention. Very interesting results have been obtained also with a mix of autologous bone and bone substitutes in different ratio in sinus augmentation procedures (15). Moreover, in the literature, the need of a membrane as a barrier over the osteotomy window is still controversial and difficult to analyze due to the different protocols used in the studies. Some authors described a better implant survival rate in patients whose osteotomy windows were covered by a membrane as compared to patients whose lateral wall defects were left uncovered (16), whilst other studies did not find such evidence reporting that implant survival rate is influenced by many factors, but not by the presence of a membrane lying over the lateral window (17). In addition, according to some authors, the presence of a membrane covering the access to the maxillary sinus would guarantee a better healing, especially in terms of higher percentage of trabecular bone volume (18), higher vital bone formation (19) and prevention of soft tissue encrustation (20). Conversely, there is some evidence claiming that the use of membrane does not improve implant survival rate and mean mineralized volume, but causes a decrease in mean osteoid volume (21). Finally,

the possible exclusion of the vascular supply from the healing area is the main criticism arisen from the use of a membrane over the lateral window in maxillary sinus augmentation procedures.

Therefore, the aim of the present study was to investigate whether a resorbable membrane could be advantageously used for a better healing after sinus floor lift procedures via a lateral approach.

## MATERIALS AND METHODS

Patients who could benefit from a maxillary sinus augmentation procedure, who had a residual bone height under the maxillary sinus lower than 5 mm and who were 18 years or older and able to sign an informed consent form were eligible for inclusion in the trial. Patients were not included in the study if any of the following exclusion criteria were present: systemic medical contraindications to implant surgery; history of irradiation in the head and neck area; poor oral hygiene and motivation; uncontrolled diabetes; current pregnancy and lactation; acute or chronic pathologies of the maxillary sinuses; smoking more than 20 cigarettes per day.

Ethical committee of Versilia Hospital, Lido di Camaiore (Italy) approved the study. Patients who were referred to the Versilia Hospital from April 2009 to January 2010, were asked to participate in the present study. All patients received thorough explanations and were requested to fill a written informed consent form prior to being enrolled in the trial. After the informed consent was signed, all patients underwent at least one session of oral hygiene prior to the augmentation procedures to provide an oral environment more favorable to wound healing. Each case

was accurately evaluated examining diagnostic casts to assess the inter-arch relationship; moreover, panoramic radiographs and computed tomography were taken.

Maxillary sinuses were allocated to either a control (membrane) or test (no membrane) group using a computerized random allocation process. Only one maxillary sinus was elevated for each patient.

A computer generated restricted randomization list was created. Only one (PT) of the investigators, not involved in the selection and treatment of the patients, was aware of the randomization sequence and could have access to the randomization list. The randomized codes were enclosed in sequentially numbered, identical, opaque, and sealed envelopes. All patients received prophylactic antibiotic therapy of 2 g of amoxicillin (or clindamycin 600 mg if allergic to penicillins) and 4 mg dexamethasone 1 h before the augmentation procedure and continued to take the antibiotic postoperatively, 1 g amoxicillin (or 300 mg clindamycin) twice a day for 7 days. All patients rinsed for 1 min with chlorhexidine mouthwash 0.2% prior to the surgery (and twice a day for the following 3 weeks), and were treated under local anesthesia using lidocaine with adrenaline 1 : 50,000. All surgeries were undertaken by the surgeons (A.B. and U.C.) and their surgical teams. All the patients were treated with the same surgical technique consisting of sinus floor augmentation via a lateral approach (22).

Briefly, a mucoperiosteal flap was elevated exposing the lateral bone wall of the maxillary sinus, a modification of the conventional lateral wall approach was used to perform the osteotomy to access the sinus membrane (23) (Fig. 1, 2). A bone scraper (Safe scraper®; Meta corp. Reggio Emilia, Italy) was used to harvest autologous cortical bone and to reduce the lateral bone thickness,

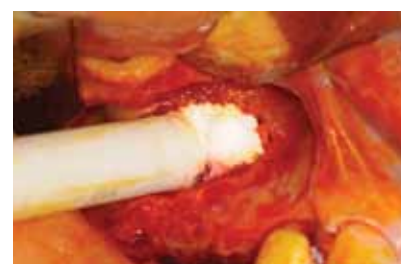
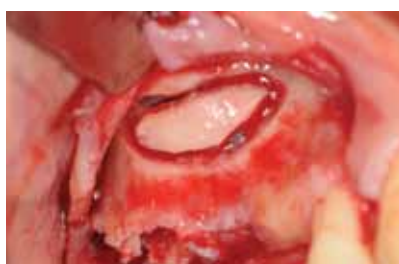
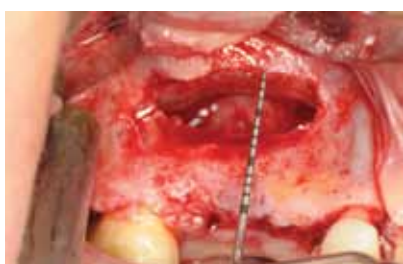FIG. 1 Direct view of the osteotomy window in a patient belonging to the test group. FIG. 2 Lateral bone wall at osteotomy. FIG. 3 Graft procedure.

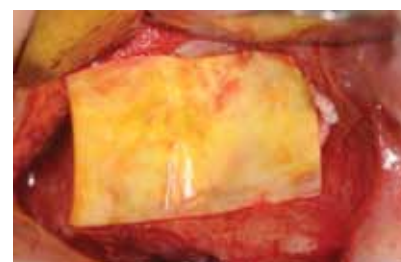
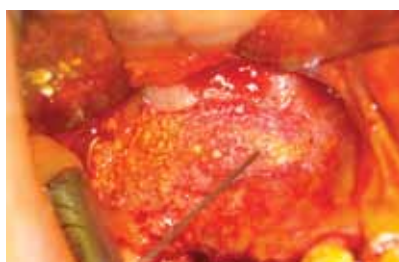
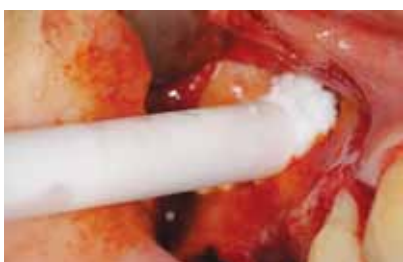
FIG. 4 Grafting. FIG. 5 At the end of grafting. FIG. 6 After placing the resorbable collagen membrane.

allowing an easy access to the sinus membrane with ultrasound (Piezosurgery, Mectron, Genova, Italy). Subsequently, large flat curettes were used to raise the sinus membrane exposing the sinus bone wall up to the medial wall. Once the sinus membranes were elevated, all the sinuses were grafted with a mixture of autogenous bone, harvested from the lateral bone wall, and collagenated corticocancellous porcine bone (MP3®; Osteobiol-Tecnoss, Coazze - TO, Italy) (Fig. 3, 4) in a 1:1 ratio. After maxillary sinus grafting, the randomization envelope was opened and indicated to the blindfolded surgeons to include the sinus as a test or a control site according to the randomization list. As a result, the treatment allocation was concealed to the investigators who were involved in enrolling and treating the patients. Sinuses in the test group did not receive any membranes over the osteotomy window (Fig. 5), while sinuses in the control group were covered with a reabsorbable collagen membrane (Evolution®; Osteobiol-Tecnoss) (Fig. 6). The mucoperiosteal flaps were sutured with 3-0 reabsorbable sutures. Patients were instructed to continue with prophylactic antibiotic therapy, and naproxen sodium 550 mg tablets were prescribed as an anti-inflammatory to be taken twice a day as long as required. Removable prosthesis, if present, was not permitted for use until they had been adjusted and refitted no sooner than 3 weeks after surgery. Patients were instructed to avoid blowing their nose and advised to administer corticosteroids, nasal drops, three times a day in both nasal cavities for 4 weeks. Patients were seen 1 week after surgery for suture removal and thereafter for regular follow-up visits. After 6 months of graft healing, radiographic examinations (orthopantomography and CT scan) were taken to evaluate the outcome of the surgical procedure. Immediately prior to the implant placement, at least one bone biopsy from each augmented maxillary sinus was harvested from the lateral window, using a trephine bur with an inner diameter of 2 mm and an outer diameter of 3 mm. Lateral window was identified by the surgeon observing the healed area in comparison with the surrounding bone. After fixation, the bone samples were forwarded to the Institute of Biomedicine, Sahlgrenska Academy Gothenburg University (Sweden) for histological examination. After the retrieval, the functional implants were inserted in the augmented maxillary sinuses.

The following outcome evaluations were considered in this study.

1. Surgical complications during maxillary sinus augmentation procedures, in particular, hemorrhage during lateral bone wall osteotomy or perforations of the sinus membrane.
2. Dimensions of osteotomy windows to access the sinuses were evaluated such as bony window length (L), bony window height (H), and lateral bone wall thickness (T).
3. Early or late postoperative complications such as

wound dehiscence and acute/chronic sinusitis.

4. Histomorphometric parameters such as trabecular bone volume, soft tissues, and residual graft particles percentages.

### Specimen processing and analysis

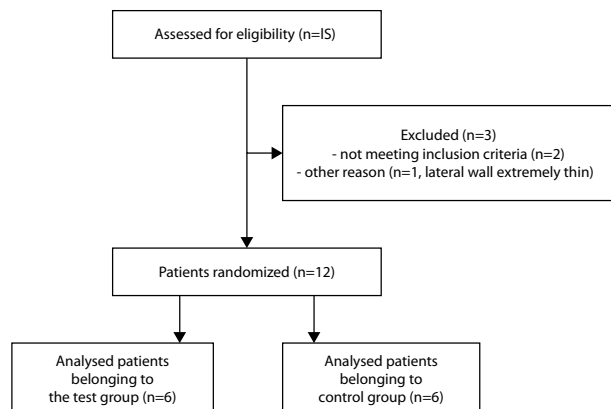
Specimens were decalcified in EDTA (15%) for a period of 2 weeks. Specimens were again X-rayed to verify the decalcification procedure. After dehydration in graded series of ethanol, the specimens were embedded in paraffin, sectioned (3–5 µm sections), and stained with hematoxyline and eosine and modified Mallory aniline blue. Examinations were performed in a Nikon Eclipse 80i microscope (Teknooptik AB, Huddinge, Sweden) equipped with an easy image 2000 system (Teknooptik AB) using X1.0 to X40 objectives for descriptive evaluation and morphometrical measurements. Histomorphometric measurements were performed in order to calculate the percentages (i.e., area fraction) of mineralized bone, residual graft materials, and soft tissue components (i.e., connective tissue and/or bone marrow) 6 months after the sinus augmentation procedure. All measurements were determined by point counting directly in the light microscope, using an optically superimposed eyepiece test square grid (distance between 6 × 6 test lines ¼ 255 mm) at a magnification of 160 X. The number of points of intersection between the test lines and the outlines of mineralized bone, bone substitute particles, and non mineralized tissue were recorded.

### Statistical analysis

The Mann–Whitney nonparametric test was used for comparing the differences between the two groups. Statistical significance was set at 5%.

## RESULTS

A total of 15 patients were assessed for eligibility for the study; 3 patients were excluded for not having met the inclusion criteria. Going into detail, one patient was being treated with oral bisphosphonate, another patient showed signs of chronic sinusitis, while the last one excluded presented a very thin lateral bone wall that would make the harvest of the bone impossible. As a consequence, 12 patients, 4 females and 8 males with an average age of 59.1 years, were recruited and randomly allocated to the two study groups: 6 patients in the test group (no membrane) and 6 patients to the control group (with membrane) (Table 1). Only a maxillary sinus was augmented. None of the patients left the study for the following 6 months of follow-up, which means, in this case, the period of time from the augmentation surgery to implant placement. For each patient the healing phase was uneventful, except for a patient who presented a mild hematoma which resolved spontaneously.

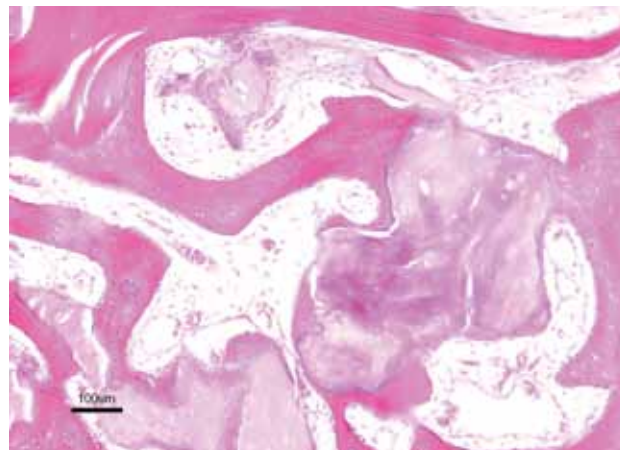


**TABLE 1** Flow diagram showing the recruitment and randomization of patients.

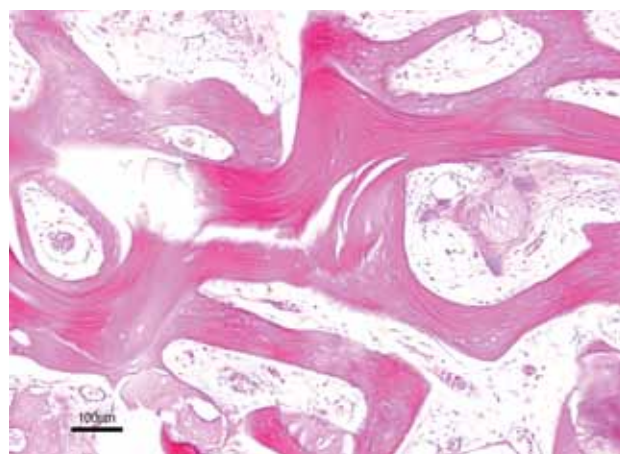
The mean dimensions of the lateral window were similar in both groups. In the non-membrane group (test group) the mean height (H) was  $10.0 \pm 1.3$  mm, the mean length (L) was  $18.1 \pm 1.6$  mm while the mean bone wall thickness was  $0.7 \pm 0.2$  mm; in the membrane group (control) the mean height was  $9.8 \pm 1.2$  mm, the mean length was  $17.7 \pm 1.8$  mm while  $0.6 \pm 0.5$  mm was the mean bone wall thickness (Table 2).

As far as the histological examination is concerned, newly formed bone, connective tissue and osteoblasts were detected around graft particles in both groups (Fig. 7, 8). In addition, in the analyzed specimens the presence of osteoclasts close to the grafted material was observed.

Moreover the histomorphometric measures showed that in the membrane group, the mean amount of newly formed bone was  $30.4 \pm 15.8\%$  (median 28.2%), the connective tissue counted for a mean value of  $50.3 \pm 18.9\%$  (median 46.7%), while  $18.2 \pm 20.4\%$  (median 8.8%) was the amount of residual graft particles; on the other hand, in the non-membrane group,  $28.0 \pm 19.5\%$  (median 17.3%) was the mean amount of newly formed bone, the mean quantity of connective tissue was  $59.2 \pm 15.6\%$  (median 50.8%) and about residual graft particles a mean value of  $12.8 \pm 12.6\%$  (median 17.1%) was registered (Table 3). This data show that no significant difference was detected in the histomorphometrical evaluation between the two groups ( $p=0,85$ ).



**FIG. 7** Histologic section of a biopsy taken from the control group 6 months after augmentation. Corticocancellous porcine bone particles are surrounded by woven bone. The marrow spaces are rich in cells and blood vessels. Magnification: bar = 100  $\mu$ m



**FIG. 8** Histologic section of a biopsy taken from the test group 6 months after augmentation. Residual porcine bone particles were covered with new bone, showing ongoing bone formation, i.e., osteoblastic seams. The soft tissues were without signs of inflammation and showing a high density of newly formed vessels. Magnification: bar = 100  $\mu$ m.

## DISCUSSION

The aim of this study was to assess whether covering the lateral window with a reabsorbable collagenous barrier membrane during augmentation of the maxillary sinus

Clinical parameters	Test group (no membrane) (mean $\pm$ SD)	Control Group (membrane) (mean $\pm$ SD)
Osteotomy window length(L)	$18.1 \pm 1.6$ mm	$17.7 \pm 1.8$ mm
Osteotomy window height (H)	$10.0 \pm 1.3$ mm	$9.8 \pm 1.2$ mm
Lateral bone wall width	$0.7 \pm 0.2$ mm	$0.6 \pm 0.5$ mm

**TABLE 2** Clinical parameters (mean  $\pm$  standard deviation) in test group and in control group.

Histomorphometric measures	Test Group (no membrane) (mean + SD, %) (median, %)	Control Group (membrane) (mean + SD, %) (median, %)
Newly formed bone	28.0 ± 19.5% (17.3%)	30.4 ± 15.8% (28.2%)
Connective Tissue	59.2 ± 15.6% (50.8%)	50.3 ± 18.9% (46.7%)
Residual graft particles	12.8 ± 12.6% (17.1%)	18.2 ± 20.4% (8.8%)

TABLE 3 Histomorphometric measurements showing the mean values and variations in the test and the control group.

floor with a mixture of porcine bone and autologous bone in 1:1 ratio is beneficial for bone regeneration. Considerable controversy exists regarding the use of membrane in terms of benefits to implant survival and treatment success. Some researchers found no differences in implant survival rates between membrane covered and uncovered groups(17,24), while others reported higher implant survival rates when the lateral walls is covered by a membrane(16,19,25). However, as stated previously, a direct comparison among different studies is extremely hard due to the multiplicity of used protocols.

Moreover, some authors stated that an unfavorable healing is obtained if a sinus lift surgery is performed without covering the lateral wall with a membrane(26). Indeed, the main adverse consequence of non using a membrane is the graft particle displacement and the enclavation (i.e. the proliferation of connective tissue into the sinus cavity), which would hamper the new bone formation thereby ensuring a minor bone to implant contact due to a minor amount of osseointegration.

Our data showed that the mean amount of newly formed bone was  $30.4 \pm 15.8\%$  for the patients whose lateral wall was covered with a membrane, whilst in the non-membrane group the mean amount of newly formed bone was  $28.0 \pm 19.5\%$ . As far as the amount of connective tissue is concerned, we found that in the membrane group it counted for a mean value of  $50.3 \pm 18.9\%$ , while in the test group the mean amount was  $59.2 \pm 15.6\%$ . Finally, about residual graft particles, we registered in the non-membrane group a value of  $12.8 \pm 12.6\%$  and on the other hand in the membrane group a value of  $18.2 \pm 20.4\%$ .

These data are not statistically significant because of the small number of patients recruited but, despite it, they underline a trend which shows a little influence of the membrane upon the formation of new bone. However, the lack of a membrane seems to lead to a higher soft tissues penetration in the lateral bone defect, thereby facilitating a major resorption of the residual graft particles.

In addition, the results of the histomorphometric evaluation could be influenced by the harvest technique of the bone biopsy (i.e from the lateral bone wall or from the bone crest) (27) and this could explain the great heterogeneity of observed data in the literature.

Regarding the membrane, some authors compared the use of a resorbable collagen membrane with the use of a resorbable PRF membrane, finding no substantial differences in terms of better healing and/or amount of vital bone formation (27). A recent study in dogs

compared the effectiveness of a membrane employed in two different ways. In one study group, the membrane was placed over the lateral bone window while in the other group (experimental) it was placed at the areas of the lateral osteotomy window, extending over the apex of implants to the posterior bone wall. The authors found that 24 weeks after implant placement, in the experimental group the amount of lamellar bone had increased and the biomaterial particles were significantly fewer, claiming that the pressure of the Schneider's membrane could play a key role in bone resorption (28). Many papers analyzed the resorption of graft material, showing that an important amount of graft particles could be found in patients' augmented maxillary sinus even after 11 years (29, 30). However, porcine-derived bone has a slightly higher resorption rate as confirmed by our data and by other studies (31, 33). This study found no difference in vital bone formation between membrane covered and uncovered group, contrasting with Tarnow et al. (19), who found a higher amount of vital bone in sites covered with membrane with respect to sites left uncovered. In our opinion, data emerging from this study can be explained in part with a lack of revascularization in the area of the membrane. In fact, branches of maxillary artery, which are the main source of blood for the maxillary bone, are included in the elevated flap and, during its repositioning, blood supply may not be able to reabsorb the grafted material; this could explain the higher value of residual graft particles found in the membrane group. On the other hand, membrane could prevent soft tissues from leaking into the grafted area, allowing a major bone formation to occur without soft tissues interference.

## CONCLUSION

Although further studies with strict and accepted protocols are needed in order to improve our knowledge on bone regeneration and sinus lift augmentation, data emerging from this study show that the use of a membrane does not substantially improve the healing of the surgical area, yet highlighting a higher amount of graft particles resorption and amount of connective tissue in uncovered areas as compared to covered ones. In the end, our study has several strengths such as a very rigorous protocol ensuring no bias during the randomization procedure, the results analysis and during the harvest of bone biopsies. This work has also some

limitations such as paucity of sample size who could have been the reason of a low significance of our results.

## REFERENCES

- Tallgren A. The continuing reduction of the residual alveolar ridges in complete dentures wearers: a mixed-longitudinal study covering 25 years. *J Prosthet Dent* 1972;27:120-132.
- Satwalekar P, Reddy BA, Chander KS, Reddy GR, Agarwal T, Chowdary SG. Endoscopic retrieval of dental implant from maxillary sinus. *J Contemp Dent Pract* 2013;14(4):759-61.
- Boyne PJ, James RA. Grafting of the maxillary sinus floor with autogenous marrow and bone. *J Oral Surg* 1980;38:613-616.
- Tatum H Jr. Maxillary and sinus implant reconstructions. *Dent Clin North Am* 1986;30:207-229.
- Misch CE. Maxillary sinus augmentation for endosteal implants organized alternative treatment plans. *Int J Oral Implantol* 1987;4:49.
- Vercellotti T, De Paoli S, Nevins M. The piezoelectric bony window osteotomy and sinus membrane elevation: introduction of a new technique for simplification of the sinus augmentation procedure. *Int J Periodontics Restorative Dent* 2001;21:561.
- Soltan M, Smiler DG. Antral membrane balloon elevation. *J Oral Implantol* 2005;31:85.
- Emtiaz S, Carames JMM, Pragosa A. An alternative sinus floor elevation procedure: trephine osteotomy. *Implant Dent* 2006;15:171.
- Pjetrusson BE, Tan WC, Zwahlen M, Lang NP. A systematic review of the success of sinus floor elevation and survival of implants in combination with sinus floor elevation. *J Clin Periodontol* 2008;35 (8 Suppl.):216-240.
- Nkenke E, Stelzle F. Clinical outcomes of sinus floor augmentation for implant placement using autogenous bone or bone substitutes: a systematic review. *Clin Oral Implants Res* 2009;20(Suppl. 4):124-133.
- Cordaro L, Amadé DS, Cordaro M. Clinical results of alveolar ridge augmentation with mandibular block bone grafts in partially edentulous patients prior to implant placement. *Clin Oral Implants Res* 2002;13:103-111.
- Schlegel KA, Eppeneder S, Wiltfang J. Soft tissue findings above submerged titanium implants- a histological and spectroscopic study. *Biomaterials* 2002;23:2939-2944.
- Oppenheimer AJ, Tong L, Buchman SR. Craniofacial bone grafting: Wolff's law revisited. *Craniofacial Trauma Reconstr* 2008;1:49-61.
- Galindo-Moreno P, Padial-Molina M, Fernandez-Barbero JE, Mesa F, Rodriguez-Martinez D, O'Valle F. Optimal microvessel density from composite graft of autogenous maxillary cortical bone and anorganic bovine bone in sinus augmentation: influence of clinical variables. *Clin Oral Implants Res* 2010b;21:221-227.
- Galindo-Moreno P, Moreno-Riestra I, Avila G, Padial-Molina M, Paya JA, Wang H-L, O'Valle F. Effect of anorganic bovine bone to autogenous cortical bone ratio upon bone remodeling patterns following maxillary sinus augmentation. *Clin Oral Implants Res* 2011;22:857-864.
- Tawil G, Mawla M. Sinus floor elevation using a bovine mineral (Bio-Oss) with or without the concomitant use of a bilayered collagen barrier (Bio-Gide): a clinical report of immediate and delayed implant placement. *Int J Oral Maxillofac Implants* 2001;16(5):713-721.
- Torres Garcia-Denche J, Wu X, Martinez P-P, Eimar H, Ikbal DJ-A, Hernandez G, et al. Membrane over the lateral window in sinus augmentation procedures: a two-arm and split-mouth randomized clinical trials. *J Clin Periodontol* 2013;40:1043-1051.
- Wallace SS, Froum SJ, Tarnow DP. Histologic evaluation of sinus elevation procedure: a clinical report. *Int J Periodontics Restorative Dent* 1996;16:47.
- Tarnow DP, Wallace SS, Froum SJ, Rohrer MD, Cho SC. Histologic and clinical comparison of bilateral sinus floor elevations with and without barrier membrane placement in 12 patients: part 3 of an ongoing prospective study. *Int J Periodontics Restorative Dent* 2000;20:117-125.
- Jensen OT, Greer RO jr, Johnson L, Kassebaum D. Vertical guided bone-graft augmentation in a new canine mandibular model. *Int J Oral Maxillofac Implants* 1995;10:335-344.
- Schulten EAJM, Prins H-J, Overman JR, Helder MN, Ten Bruggenkate CM, Klein-Nulend J. A novel approach revealing the effect of a collagenous membrane on osteoconduction in maxillary sinus floor elevation with  $\beta$ -tricalcium phosphate. *Eur Cell Mater* 2013;25:215-228.
- Barone A, Crespi R, Aldini NN, Fini M, Giardino R, Covani U. Maxillary sinus augmentation: histologic and histomorphometric analysis. *Int J Oral Maxillofac Implants* 2005;20:519-525.
- Galindo-Moreno P, Avila G, Fernandez-Barbero JE, Aguilar M, Sanchez-Fernandez E, Cutando A, Wang HL. Evaluation of sinus floor elevation using a composite bone graft mixture. *Clin Oral Implants Res* 2007;18:376-382.
- Choi K, Kan J, Boyne PJ, Goodacre CJ, Lozada JL, Rungcharassaeng K. The effects of resorbable membrane on human maxillary sinus graft: a pilot study. *Int J Oral Maxillofac Implants* 2009;24:73.
- Wallace SS, Froum SJ. Effect of maxillary sinus augmentation on the survival of endosseous dental implants. A systematic review. *Ann Periodontol* 2003;8:328-343.
- McAllister BS, Margolin MD, Cogan AG, Taylor M, Wollins J. Residual lateral wall defects following sinus grafting with recombinant human osteogenic protein-1 or Bio-Oss in the chimpanzee. *Int J Periodontics Restorative Dent* 1998;18:227-239.
- Gassling V, Purcz N, Braesen J-H, Will M, Gierloff M, Behrens E et al. Comparison of two different absorbable membranes for the coverage of lateral osteotomy sites in maxillary sinus augmentation: A preliminary study. *J Craniomaxillofac Surg* 2013;41:76-82.
- Li X, Chen S-I, Zhu S-x, Zha G-q. Guided bone regeneration using collagen membranes for sinus augmentation. *Br J Oral Maxillofac Surg* 2012;50:69-73.
- Hallman M, Sennerby L, Zetterqvist L, Lundgren S. A 3-year prospective follow-up study of implant-supported fixed prostheses in patients subjected to maxillary sinus floor augmentation with a 80:20 mixture of deproteinized bovine bone and autogenous bone. Clinical, radiographic and resonance frequency analysis. *Int J Oral Maxillofac Surg* 2005;34:273-280.
- Mordenfeld A, Hallman M, Johansson CB, Albrektsson T. Histological and histomorphometrical analyses of biopsies harvested 11 years after maxillary sinus floor augmentation with deproteinized bovine and autogenous bone. *Clin Oral Implants Res* 2010;21:961-970.
- Barone A, Ricci M, Covani U, Nannmark U, Azarmehr I, Calvo-Guirado JL. Maxillary sinus augmentation: histologic and histomorphometric analysis. *Int J Oral Maxillofac Implants* 2010;20:519-525.
- Torres J, Tamimi F, Martinez PP, Alkhraisat MH, Linares R, Hernández G, Torres-Macho J, Lopez-Cabarcos E. Effect of platelet-rich plasma on sinus lifting: a randomized-controlled clinical trial. *J Clin Periodontol* 2009 Aug;36(8):677-8.
- Perrotti V, Nicholls BM. Resorption pattern of a porcine derived bone substitute. *J Osseointegr* 2009;1(1):22-28.