

# The role of occlusion on full mouth rehabilitations with adhesive partial crowns. A systematic review

> **A. BIAGIONI, M. PECCIARINI, N. DISCEPOLI, M. FERRARI**

Department of Medical Biotechnologies, Division of Fixed Prosthodontics, University of Siena, Siena, Italy

## TO CITE THIS ARTICLE

Biagioni A, Pecciarini M, Discepoli N, Ferrari M. The role of occlusion on full mouth rehabilitations with adhesive partial crowns. A systematic review. *J Osseointegr* 2020;12(2):161-166.

DOI 10.23805 /JO.2020.12.01.06

## ABSTRACT

**Aim** In the dental literature there are many studies about full mouth rehabilitation. They are mainly focused on the reestablishment of esthetics and function in edentulous patients, or in complex cases in which a multidisciplinary approach is needed. The aim of this study was to systematically review the role of occlusion reported in the literature when full mouth rehabilitations by adhesive partial crowns are made.

**Methods** This report followed the PRISMA Statement. A database search in Medline/PubMed, Cochrane and Researchgate, in addition to other sources and manual searches was conducted, using appropriate key words to identify all kind of studies reporting on occlusion in full mouth rehabilitation with adhesive partial crowns. No language or time limitation was applied.

**Results** Only three papers were selected but no randomized clinical trials were found.

**Conclusion** No randomized clinical trial is available on full mouth rehabilitation with adhesive partial crowns and on the role of occlusion.

**KEYWORDS:** Adhesive partial crowns; Full mouth rehabilitation; Occlusion.

## INTRODUCTION

Nowadays full mouth rehabilitations are requested for edentulous patients treated with full dentures or implant therapy, or patients who have still their complete dentition but with loss or alterations of dental structure. The pathological wear of tooth structure may be caused by a single causative factor or, more commonly, by an interplay of factors, namely the following.

- Erosion: the progressive loss of tooth substance by chemical processes that do not involve bacterial action.
- Abrasion: an abnormal wearing of the tooth substance by causes other than mastication.
- Attrition: the mechanical wear resulting from mastication or parafunction, limited to contacting surfaces of the teeth.
- Abfraction: the pathologic loss of hard tooth substance caused by biomechanical loading forces due to flexural and chemical fatigue degradation of enamel and/or dentine at some location distant from the actual point of loading; it may cause loss of tooth structure in cervical regions (1).

The most common causes of loss of tooth structure are: bruxism or other parafunctions, bulimia and other eating disorders, dentinogenesis and amelogenesis imperfecta. These factors can have a significant impact on the structure of the teeth: they dissolve enamel and dentin causing a progressive deterioration of dental health, which leads to functional esthetic and biological consequences (2).

A key step in the management of patients with tooth structure loss, is to determine the primary causative factor and set appropriate preventive measures to check further deterioration of the dentition: any treatment without prevention is likely to fail (3). Due to a lack of awareness of the problem among patients, as well as clinicians' hesitation to address it, the extent of these diseases is often underestimated, and the treatment postponed (4). If erosion is not intercepted at an early stage, full mouth rehabilitation may be required (5).

However full mouth rehabilitations are time consuming and costly. Reducing the cost of the therapy, simplifying the clinical steps, and proposing noninvasive adhesive techniques may promote patient acceptance (6).

According to the literature and the concepts of restorative dentistry, the rehabilitation of such cases involves numerous full crowns and root canal treatments, a process which is expensive both financially and biologically, time-consuming, and may be too aggressive considering that the population affected by erosion is generally very young (2,5).

Since the 1990s, adhesive techniques and materials have been greatly improved. The development of resin composite and adhesive systems has made it possible, today, to reconstruct teeth with minimal dental preparation (7), without the need to prepare a retentive cavity. Moreover, adhesive techniques simplify both the clinical and the laboratory procedures, so the indications for crowns have decreased and more conservative approaches are proposed (5).

The adhesive approach is followed to respect the principle of minimally invasiveness, but it is commonly used only for anterior esthetic rehabilitations, because when the loss of tooth structure is localized both in the posterior and anterior region, restoring such patients becomes a challenge due to the great amount of tooth destruction (8).

In some cases, the loss of tissue is so important that the occlusion is very compromised. Occlusion, in a dental context, means simply the contact between teeth. More technically, it is the relationship between the upper and the lower teeth when they contact each other, as occurs during chewing, parafunction or at rest.

Static occlusion refers to contact between teeth when the jaw is closed and still, while dynamic occlusion refers to occlusal contacts made when the jaw is moving. In a full mouth rehabilitation, the health of the entire stomatognathic system has to be assessed: both in static and dynamic situations.

This review has the purpose to analyze when the rehabilitation of patients with tooth structure loss with adhesive partial crowns is indicated, and what is the role of occlusion on the decision-making process.

In keeping with the Preferred Reporting Items for Systematic reviews and Meta-Analyses (PRISMA) guidelines for systematic reviews, the research question was then formulated with reference to participants (patient with complete dentition), intervention (full mouth rehabilitation with adhesive partial crowns), and study design (all), parameters of the PICOS method (9).

## METHODOLOGY

### Search strategies

An electronic search of the literature was conducted through PubMed, Cochrane Library and Research gate,

entering the query terms "full mouth rehabilitation" AND "adhesive partial crowns" AND "occlusion".

No language or time limitation was applied, in order not to leave any study out.

In this way only two results were found: Yip, Chow, Chu "Rehabilitating a patient with bruxism-associated tooth tissue loss: a literature review and case report" (10); Groten "Complete esthetic and functional rehabilitation with adhesively luted all-ceramic restorations. Case report over 4.5 years" (11). The first paper of Yip was excluded from the abstract because treatment with ceramo-metal crowns and fixed partial dentures were included. The second paper was excluded from the full text because treatments with full crowns were used instead of adhesive partial crowns.

A second search was conducted entering the query terms "full mouth rehabilitation" AND "occlusion", and 110 results were found. Then 105 papers were added from the references of the studies, read completely in order to identify other potentially relevant articles.

The web was browsed by entering in the Google search box the same query terms as those used in the PubMed. The papers were examined in different steps. For inclusion in the review, studies had to meet the following criteria based on the PICO (Participants, Interventions, comparators, outcome measures) system (9).

Participants were patient with complete dentition. The intervention searched was a full mouth rehabilitation by adhesive partial crowns. Every kind of articles was considered: cohort studies, non-randomized clinical trials, randomized clinical trials, case reports, case series, case-control studies, descriptive studies, retrospective studies, cross-sectional studies, pilot studies, and review.

### Selection of studies

Only papers about both anterior and posterior restorations were considered.

Firstly, all the 215 titles obtained from the research (Figure 1) were read and 111 titles that evidently did not refer to adhesive procedures were excluded.

Secondly the 104 abstracts of the selected titles were screened and 65 papers with cases of edentulism, implantology, traditional prosthetic workflows, surgery, multidisciplinary cases or procedures other than adhesive measures were excluded.

The reason for excluding articles that address the topic of interest, but fail to fulfil one or more of the eligibility criteria, was recorded. Then full-text articles were carefully read. Only the studies that were relevant to the objectives of the review and satisfied the requirements of the Quality Assessment of Diagnostic Accuracy Studies (QUADAS) checklist (12, 13) were included in the review. Different papers about adhesive direct rehabilitations were excluded.

At the end, only 3 of the 39 papers read completely werenot excluded.



**RESULTS**

Of the 215 articles found, only 3 papers about full mouth rehabilitation with adhesive partial crowns met the criteria of the review. No randomized clinical trial was found (Table 1).

**DISCUSSION**

Diagnosis, treatment plane, occlusion, materials, techniques, follow up were some aspects repeated as relevant by different papers.

Diagnosis and preventive treatment are important in

order to not start treating patients in an already advanced state, when a full mouth rehabilitation is really needed. Bruxism can cause different patterns of tooth wear: sometimes it is widespread and sometimes it is mainly in the anterior region (due to protrusive movements) and does not require a full mouth rehabilitation. The primary prevention is the removal of the cause. In cases of abrasion, this is usually straightforward removal of the exogenous "agent" (3). For attrition, it is difficult to stop parafunction (such as bruxism habit), because it is often a centrally mediated response to life stressors (15-19) and the use of cognitive behavioral therapy and alternative therapies (such as hypnosis) have shown some benefits (20-22). Following Primary

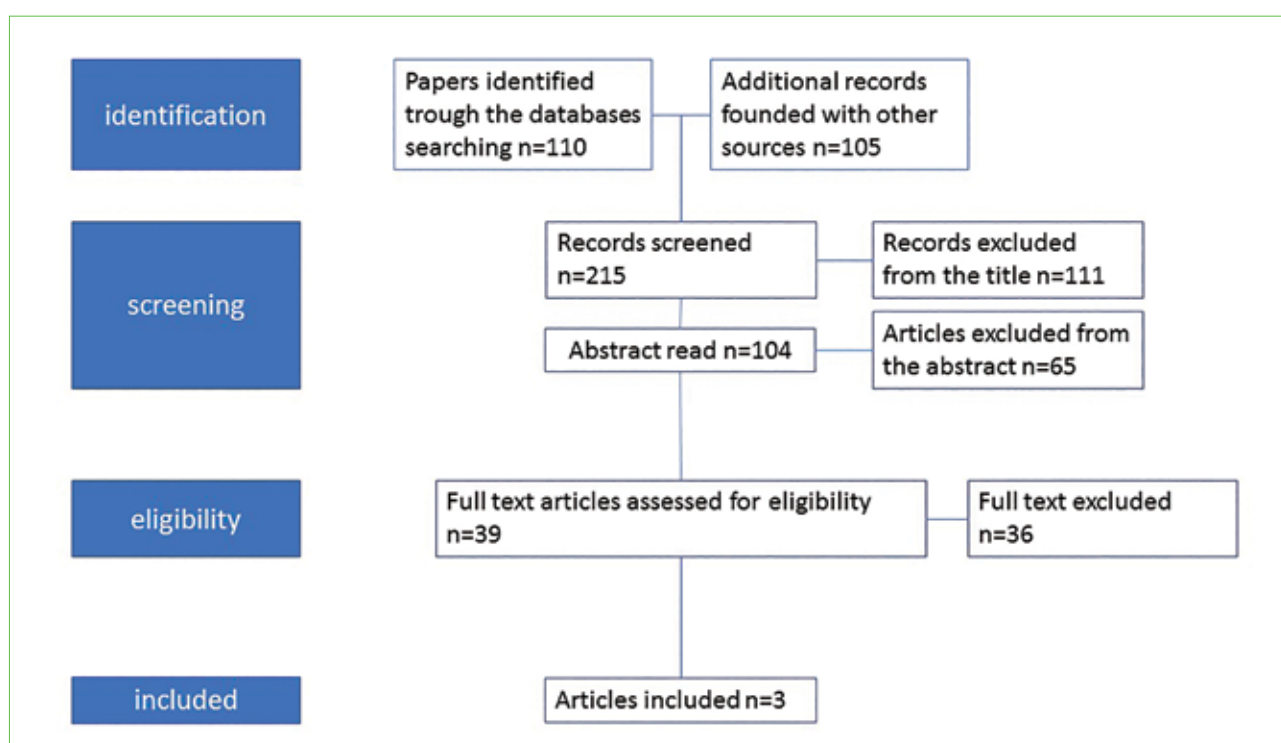


FIG. 1 Selection of studies.

Author	Title	Paper	Type of occlusion	Patient	Follow up
Vailati Belser 2008 (5)	Full mouth adhesive rehabilitation of a severely eroded dentition: the three step technique. Part 1	Overview	Maximum intercuspation position	Severe dental erosion	Clinical trial in progress
Vailati Belser 2008 (8)	Full mouth adhesive rehabilitation of a severely eroded dentition: the three step technique. Part 2				
Vailati Belser 2008 (14)	Full mouth adhesive rehabilitation of a severely eroded dentition: the three step technique. Part 3				

TABLE 1 The 3 papers that met the criteria of the review.

and Secondary Factors on determining the wear is of paramount importance (23); it is also important to bear in mind that physiological wear normally exists and to understand when it becomes "pathological wear" compromising patient's quality of life, with esthetic and functional problems. In addition, it must be always considered that the pathological wear has "poussé" (23). However, in many cases, the "next best" approach is to provide a stabilization splint (24) and to delay as long as possible any restorative interventions (25).

In cases of erosion, more and more common due to the dietary habits, is very helpful to use a diet diary to identify which factors can be the cause of tooth erosion (26-29). Sometimes erosion depends on gastric problem such as esophageal reflux disorder or other eating disorders; in these cases, a collaboration with the patient's general medical practitioner is the best choice. In recent years, new strategies for the prevention and treatment of erosive lesions have been described (30,31). After diagnosis, the second key factor is the use of materials that allow to follow the concept of minimally invasive dentistry. In the literature, the opposition of a conservative approach instead of a traditional one was pointed out several times. Traditional fixed prosthesis is based on a total crown preparation with consequent sacrifice of sound tissue not directly linked to the pathology which led to the need for treatment (2). Therefore, adhesive procedures could be more suitable because they allow minimal or no preparation (32). Some reports that were excluded (2, 33-36) used also direct composite restorations in order to avoid teeth preparation and for economic reasons.

There is a lack of comparable long-term data on full mouth adhesive restorations, and the questions are whether a possibly less durable adhesive rehabilitation is preferable to longer-lasting but more aggressive conventional treatment (5) and if it is better to use resin (modifiable but consumable) or other more resistant materials as disilicate being equally aggressive.

Using direct composite or resin restorations can be useful as mock up (32), but especially in case of extended tooth wear these materials cannot guarantee long-term results (25).

The mock-up is very useful during the clinical procedures to control the thickness of tooth preparations in relation to the final restorative volumes (37-41). And in the case of complex, extensive rehabilitations with a VDO increase, the mock-up should be tested intraorally to properly check all the functional, esthetic, and phonetic parameters (32).

In the articles included, the ACE classification has been used (42). Sometimes the treatment plan is directed to a half and half choice: half direct and half indirect. It depends on the cost of the treatment, and on the nature of the materials. Resins and composites can be modified, if needed; however, in a full mouth rehabilitation the treatment plan should include a temporary modifiable

part, and a definitive part.

The central focus of the review was the role of occlusion. The more tissue is lost, the more treatment is complicated, needing an occlusal rehabilitation. In case of indirect adhesive prosthesis, which type of occlusion has to be chosen to rehabilitate the patient both esthetically and functionally? Different philosophies are available. In restorative treatment the options are a conformative occlusal approach (often advisable) or a reorganized approach (43). In the conformative approach (44), occlusion is restored based on the patient's existing maximum intercuspal position (MIP); it is suggested for limited loss of structure. In the reorganized approach, a new occlusal pattern is established around a suitable condylar position which is the centric relation position, if the existing intercuspal position is unacceptable and needs to be changed or when extensive treatment is to be undertaken to optimize the patient's occlusion. According to several articles on gnathology (45-47), the indications for reorganized approach are loss of vertical dimension, repeated fracture/failure of teeth or restorations, severe bruxism, lack of interocclusal space for restorations, trauma from occlusion, unacceptable function and esthetics, presence of temporomandibular disorders or developmental anomalies (43). Usually centric relation is recommended as the only acceptable position for full mouth rehabilitations, since it is considered the only reproducible one (8). An increase of vertical dimension of occlusion can be indicated in order to ensure appropriate function and esthetics, provide enough space for restorations and prevent sound tooth tissue loss.

Whenever indicated, the permanent increase of vertical dimension up to 5 mm is a safe and predictable procedure without detrimental consequences (48).

Follow up is another crucial point of the full mouth rehabilitation by adhesive partial crowns.

It has to be studied what are the clinical negative and positive aspects of the treatment plan. The risk of clinical failure is not related to the extension of each restoration (if it is an onlay/overlay etc.) when successfully luted using a resin composite material (11). Marginal discoloration is reported on adhesively luted ceramics and indirect composite restorations (49-52) but the long-term clinical impact of marginal discoloration on the prognosis of adhesively luted restorations still needs thorough investigation.

The rehabilitation with adhesive partial crowns offers interesting possibilities but also involves a high degree of technique sensitivity regarding the preparation (mainly in the enamel), adhesive bonding, and final fine-tuning of both static and dynamic occlusion (52-58). While numerous long-term clinical studies (52,57-60) of minimally invasive restorative treatment methods with ceramic materials are available, valid clinical data are still lacking on long-term behavior of minimally invasive final restorations made of CAD/CAM polymers

(34,60,61). The longest follow up found in the case reports was of only 2 years (35) and sometimes it was not mentioned at all.

The principles of treatment are universal, all the functional factors are interrelated, and all efforts should be made to obtain an occlusal interface so that dental periodontium, masticatory muscles, and TMJ's function are in mutual harmony (43). Chewing efficiency can exist over a wide range of occlusal forms and types of occlusal patterns, so no set rule can be applied to all patients in restorative treatment. A comprehensive study and practical approach must be directed towards reconstruction, restoration and maintenance of the health of the entire oral apparatus.

There is a need to investigate and develop adhesive materials and treatments that can satisfy biological, functional, and esthetic requirements and that are reliable and long lasting both in anterior and posterior areas (2).

Because of the lack of randomized clinical trials on full mouth adhesive reconstruction, they are usually selected based on the esthetic request of the patient, when no medical pathologies correlated to TMJ or muscles (62) are present. As long as there are no studies that demonstrate the importance of occlusion in determining the success of the treatment plan, only the need of patients related to aesthetics aspects can justify the full mouth rehabilitation made on worn dentitions.

## CONCLUSIONS

Randomized clinical studies to evaluate the role of occlusion in full mouth rehabilitations using adhesive partial crowns as an alternative to conventional prosthesis are needed, and also predictability and reliability of full mouth reconstructions with adhesive esthetic partial crowns still have to be defined. No randomized clinical trial is available on full mouth rehabilitation with adhesive partial crowns and on the role of occlusion.

## Clinical significance

In literature there are not randomized clinical trials about full mouth rehabilitations using adhesive partial crowns.

## Conflict of interests

The authors declare no potential conflict of interests.

## REFERENCES

1. The glossary of prosthodontic terms. *J Prosthet Dent* 2005;94:10–92.
2. Spreafico RC. Composite resin rehabilitation of eroded dentition in a bulimic patient: a case report. *Eur J Esth Dent* 2010;5(1):28–48.
3. Satterthwaite JD. Tooth surface loss: tools and tips for management. *Dent Update* 2012;39:86–96.

4. Vailati F, Vaglio G. Full mouth minimally invasive adhesive rehabilitation to treat severe dental erosion: a case report. *J Adhes Dent* 2012;14:83–92.
5. Vailati F, Belser C. Full mouth adhesive rehabilitation of a severely eroded dentition: the three step technique. Part1. *Eur J Esth Dent* 2008;3:30–44.
6. Vailati F, Carciofo S. CAD/CAM monolithic restorations and full-mouth adhesive rehabilitation to restore a patient with a past history of bulimia: the modified three-step technique. *Int J Esth Dent* 2016;1(1):1–22.
7. Van Meerbeek B, De Munck J, Yoshida Y, Inoue S. Memorial Lecture. Adhesion to enamel and dentin: current status and future challenges. *Oper Dent* 2003;28:215–235.
8. Vailati F, Belser C. Full mouth adhesive rehabilitation of a severely eroded dentition: the three step technique. Part2. *Eur J Esth Dent* 2008;3:128–146.
9. Liberati A, Altman DG, Tetzlaff J. The PRISMA statement for reporting systematic reviews and meta-analyses of studies that evaluate health care interventions: explanation and elaboration. *J Clin Epidemiol* 2009;62:e1–34.
10. Yip KH, Chow TW, Chu FC. Rehabilitating a patient with bruxism-associated tooth tissue loss: a literature review and case report. *Gen Dent* 2003Jan-Feb;51(1):70–4; quiz75–6.
11. Groten M. Complete esthetic and functional rehabilitation with adhesively luted all-ceramic restorations--case report over 4.5 years. *Quintessence Int* 2007 Oct;38(9):723–31.
12. Whiting P, Rutjes AW, Reitsma JB. The development of QUADAS: a tool for the quality assessment of studies of diagnostic accuracy included in systematic reviews. *BMC Med Res Methodol* 2003;3:25.
13. Whiting PF, Rutjes AW, Westwood ME. QUADAS-2 Group. QUADAS-2: a revised tool for the quality assessment of diagnostic accuracy studies. *Ann Intern Med* 2011;155:529–36.
14. Vailati F, Belser C. Full mouth adhesive rehabilitation of a severely eroded dentition: the three step technique. Part3. *Eur.J.Est.Dent.* 2008;3:236–257.
15. Manfredini D, Visscher C, Guarda-Nardini L, Lobbezoo F. Occlusal factors are not related with self-reported bruxism. *J Orofac Pain* 2012;26:163–7.
16. Manfredini D, Castroflorio T, Perinetti G, Guarda-Nardini L. Dental occlusion, body posture and temporomandibular disorders: where we are now and where we are heading for. *J Oral Rehabil* 2012;39:463–71.
17. Manfredini D, Lobbezoo F. Relationship between bruxism and temporomandibular disorders: a systematic review of literature from 1998 to 2008. *Oral Surg Oral Med Oral Pathol Oral Radiol Endod* 2010;109:e26–50.
18. Manfredini D, Bandettini di Poggio A, Cantini E, Dell'Osso L, Bosco M. Mood and anxiety psychopathology and temporomandibular disorder: a spectrum approach. *J Oral Rehabil* 2004;31:933–40.
19. Manfredini D, Winocur E, Guarda-Nardini L, Paesani D, Lobbezoo F. Epidemiology of bruxism in adults: a systematic review of the literature. *J Orofac Pain* 2013;27:99–110.
20. Ommerborn MA, Schneider C, Giraki M et al. Effects of an occlusal splint compared with cognitive-behavioral treatment on sleep bruxism activity. *Eur J Oral Sci* 2007;115:7–14.
21. Clarke DJH, Reynolds PJ. Suggestive hypnotherapy for nocturnal bruxism: a pilot study. *Am J Clin Hypn* 1991;33:248–253.
22. Goldberg G. The psychological, physiological and hypnotic approach to bruxism in the treatment of periodontal disease. *J Am Soc Psychosom Dent Med* 1973;20:75.
23. Wetselaar P, Lobbezoo F. The tooth wear evaluation system: a modular clinical guideline for the diagnosis and management planning of worn dentitions. *J Oral Rehabil* 2016;43:69–80.
24. Moufti MA, Lilico JT, Wassell RW. How to make a well-fitting stabilization splint. *Dent Update* 2007;34:398–408.
25. Loomans B, Opdam N, Attin T, Bartlett D, Edelhoff D, Frankenberger R. Severe tooth wear: European Consensus Statement on management Guidelines. *J Adhes Dent* 2017;19:111–119.
26. Davis WB, Winter PJ. The effect of abrasion on enamel and dentine and exposure to dietary acid. *Br Dent J* 1980;148:253–256.
27. Beyer M, Reichert J, Bossert J, Sigusch BW, Watts DC, Jandt KD. Acids with



- an equivalent taste lead to different erosion of human dental enamel. *Dent Mater* 2011;27:1017-1023.
28. Bartlett DW, Fares J, Shirodaria S, Chiu K, Ahmad N, Sherriff M. The association of tooth wear, diet and dietary habits in adults aged 18–30 years old. *J Dent* 2011;39:811-816.
  29. Jarvinen VK, Rytomaa, II, Heinonen OP. Risk factors in dental erosion. *J Dent Res* 1991;70:942-947.
  30. Lussi A, Hellwig E, Ganss C, Jaeggi T. Buonocore. Memorial Lecture. *Dental erosion. Oper Dent* 2009;34:251-262.
  31. Lussi A, Jaeggi T, Schaffner M. Prevention and minimally invasive treatment of erosions. *Oral Health Prev Dent* 2004;2(Suppl1):321-325.
  32. Fabbri, Cannistraro, Pulcini, Sorrentino. The full-mouth mock-up: a dynamic diagnostic approach (DDA) to test function and esthetics in complex rehabilitations with increased vertical dimension of occlusion. *Int. J. Esth. Dent.* 2018;13(4):2-16.
  33. Grutter L, Vailati F. Full-mouth adhesive rehabilitation in case of severe dental erosion, a minimally invasive approach following the 3-step technique. *Eur J. Esth. Dent* 2013;8(3):358-75.
  34. Pour, Edelhoff. Rehabilitation of a patient with amelogenesis imperfecta using a porcelain veneers and CAD/CAM polymer restorations: a clinical report. *Quintessence International* 2015;46(10):843-852.
  35. Stevens C.J.. A Segmented Approach to Full-Mouth Rehabilitation. *Dent Today.* 2012 Nov;31(11):106, 108-12
  36. Soliman. Treatment of an Adolescent Patient with Dentinogenesis Imperfecta Using Indirect Composite Restorations - A Case Report and Literature Review. *J Adhes Dent* 2018;20(4):345-354.
  37. Gürel G. Predictable, precise, and repeatable tooth preparation for porcelain laminate veneers. *Pract Proced Aesthet Dent* 2003;15:17-24.
  38. Magne P, Magne M. Use of an additive wax-up and direct intraoral mock-up for enamel preservation with porcelain laminate veneers. *Eur J Esthet Dent* 2006;1:10-19.
  39. Gurra J, Bruguera A. Waxup and mock-up. A guide for anterior periodontal and restorative treatments. *Int J Esthet Dent* 2014;9:146-162.
  40. Magne P, Belsler UC. Novel porcelain laminate preparation approach driven by a diagnostic mock-up. *J Esthet Restor Dent* 2004;16:7-16.
  41. Gürel G, Morimoto S, Calamita MA, Coachman C, Sesma N. Clinical performance of porcelain laminate veneers: outcomes of the aesthetic pre-evaluative temporary (APT) technique. *Int J Periodontics Restorative Dent.* 2012;32:625-635.
  42. Vailati F, Belsler C. Classification and Treatment of the Anterior Maxillary Dentition Affected by Dental Erosion: The ACE Classification. *Int J Periodontics Restorative Dent.* 2010 Dec;30(6):559-71.
  43. Tiwari. Occlusal concepts in full mouth rehabilitation: an overview. *J Indian prosthodont* 2014 soc14(4):344-351.
  44. Celenza FV, Litvak H. Occlusal management in conformational dentistry. *J Prosthet Dent.* 1976;36:164-170.
  45. Stuart CE, Golden IB. The History of Gnathology. *CE Stuart Gnatological Instruments.* 1981;13-32,113.
  46. Granger ER. *Practical Procedures in Oral Rehabilitation.* Philadelphia: Lippincott, 1962:66-74.
  47. McCollum BB. Fundamentals involved in prescribing restorative dental remedies. *Dental Items Interest*, 1939.
  48. J. Abduo. Safety of increase vertical dimension: a systematic review. *Quintessence Int.* 2012; 43:360.
  49. Frankenberger R, Petschelt A, Kramer N. Leucite reinforced glass ceramic inlays and onlays after six years: clinical behavior. *Oper Dent* 2000;25:459-465.
  50. Felden A, Schmalz G, Hiller K. Retrospective clinical study and survival analysis on partial ceramic crowns: results up to 7 years. *Clin oral investing* 200;4:199-205.
  51. Beier US, Kapferer I, Dumfahrt H. Clinical long-term evaluation and failure characteristics of 1,335 all-ceramic restorations. *Int J Prosthodont* 2012;25:70-78.
  52. Burke FJ. Survival rates for porcelain laminate veneers with special reference to the effect of preparation in dentin: a literature review. *J Esthet Restorative Dent* 2012;24:257-265.
  53. Frankenberger R, Reinelt C, Petschelt A, Kramer N. Operator vs. material influence on clinical outcome of bonded ceramic inlays. *Dent Mater* 2009;25:960-968.
  54. Van Dijken JW, Hasselrot L, Ormin A, Olofsson AL. Restorations with extensive dentin/enamel-bonded ceramic coverage. a 5-year follow-up. *Eur J Oral Sci* 2001;109:222-229.
  55. D'Arcangelo C, De Angelis F, Vadini M, D'Amario M. Clinical evaluation on porcelain laminate veneers bonded with light-cured composite: results up to 7 years. *Clin Oral Investig* 2012;16:1071-1079.
  56. Beier US, Kapferer I, Burtscher D, Giesinger JM, Dumfahrt H. Clinical performance of all-ceramic inlay and onlay restorations in posterior teeth. *Int J Prosthodont* 2012;25:395-402.
  57. Kern M, Sasse M. Ten-year survival of anterior all-ceramic resin-bonded fixed dental prostheses. *J Adhes Dent* 2011;13:407-410.
  58. Peumans M, van Meerbeek B, Lambrechts P, Vanherle G. Porcelain veneers: a review of the literature. *J Dent* 2000;28:163-177.
  59. Van Dijken JW, Hasselrot L. A prospective 15-year evaluation of extensive dentin- enamel-bonded pressed ceramic coverages. *Dent Mater* 2010;26:929-939.
  60. Fasbinder DJ, Dennison JB, Heys DR, Lampe K. The clinical performance of CAD/ CAM-generated composite inlays. *J Am Dent Assoc* 2005;136:1714-1723.
  61. Van Meerbeek S, Vandamme K, Lijnen I, Naert I. Computer-aided designed/ computer- assisted manufactured composite resin versus ceramic single-tooth restorations: a 3-year clinical study. *Int J Prosthodont* 2010;23:223-230.
  62. Sterenberg BA, Bronkhorst EM, Wetselaar P, Lobbezoo F, Loon BAC, Huysmans MC. The influence of management of tooth wear on oral health-related quality of life. *Clinical Oral Investigations*; Sept2018; 22(7):2567-2573.