

# Implant placement on bone granulation tissue: a case series

► **B. F. R. FERRAZ<sup>1</sup>, V. DE T. STUANI<sup>2</sup>, E. PASSANEZI<sup>3</sup>, C. A. DAMANTE<sup>4</sup>, S. L. A. GREGHI<sup>4</sup>, M. L. R. DE REZENDE<sup>4</sup>, M. S. R. ZANGRANDO<sup>5</sup>, A. C. P. SANT'ANA<sup>4</sup>**

Discipline of Periodontics, Department of Prosthodontics. School of Dentistry at Bauru, University of São Paulo, Brazil

<sup>1</sup> Assistant Professor. Discipline of Periodontics, Dentistry course. University of Marília, UNIMAR, Marília, SP, Brazil

<sup>2</sup> PhD student

<sup>3</sup> Retired head professor

<sup>4</sup> Associate Professor

<sup>5</sup> Assistant Professor

## TO CITE THIS ARTICLE

Ferraz BFR, Stuani VT, Passanezi E, Damante CA, Greghi SLA, de Rezende MLR, Zangrando MSR, Sant'Ana ACP. Implant placement on bone granulation tissue: a case series. *J Osseointeg* 2019;11(2):85-91

DOI 10.23805 /JO.2019.11.02.02

## ABSTRACT

**Aim** Some of the main challenges in immediate implant placement are the lack of remaining bone for anchorage and socket decontamination in cases of teeth extracted due to infection. The objective of this case series is to describe a surgical technique that is also capable of maintaining bone architecture after extraction, while promoting the decontamination of the area and use the maximum potential of bone cells regenerative capacity.

**Case report** Three cases were followed for periods ranging from 5 months to 5 years. An early implantation technique was used on all cases, with a waiting period of 21 days after tooth-extraction. This allows the implant placement on a new formed bone granulation tissue, rich in growth factors and osteoprogenitor cells.

**Results** This approach allowed sites decontamination, formation of vital bone contacting the implant surface, primary stability, good three-dimensional positioning, and satisfactory prosthetic outcomes in all cases.

**Conclusions** Implant placement on bone granulation tissue is a viable technique and should be considered as an option during treatment planning.

**KEY WORDS:** Case report, Decontamination, Early implant, Implant, Newly forming bone.

## INTRODUCTION

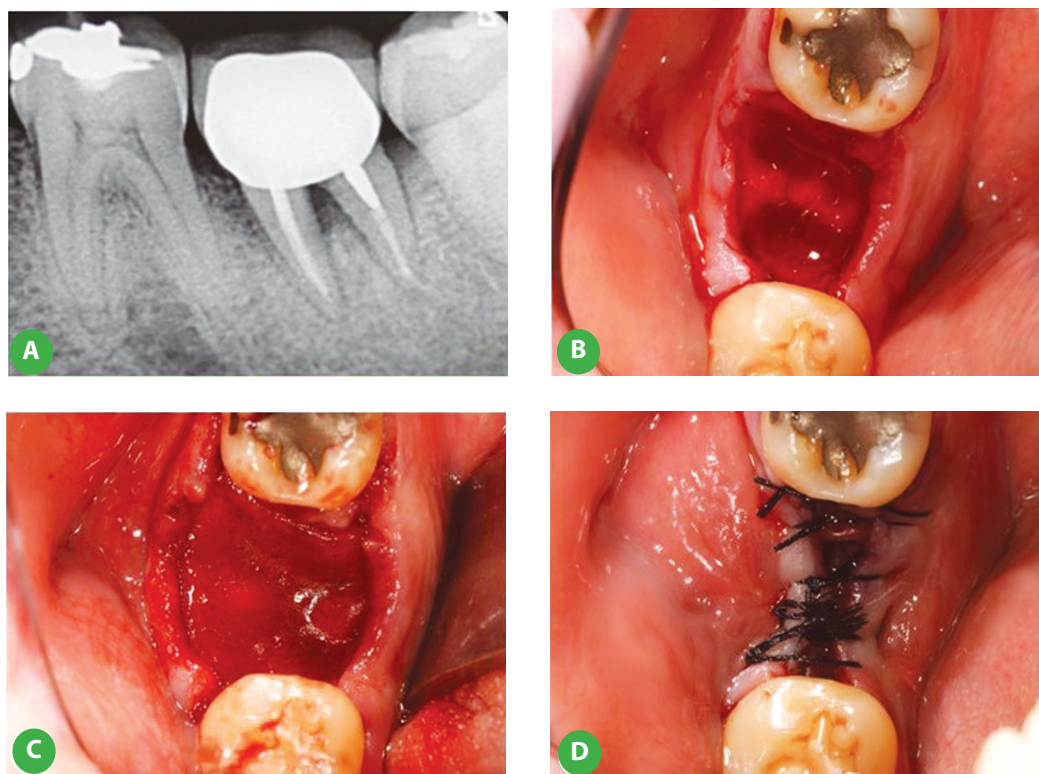
Currently, the use of endosseous implants for the rehabilitation of partially or totally edentulous subjects is well established in the literature (1). Several studies on surgical techniques, type of implants and repair process indicate prediction of the possible limitations and complications of each case (2-6). The technique of immediate implant placement has been increasingly investigated and used (1, 7, 8), since it provides more comfort to the patient and restricts bone resorption after extraction (9). However, its accomplishment demands greater operator skill, considering the need of implant placement in areas of compromised remaining bone due to the presence of an extraction socket. Thus, the primary stability may be impaired, with inadequate three-dimensional positioning for prosthetic rehabilitation (10). The ability of socket decontamination may also inhibit the immediate implant placement in cases of teeth extracted due to infection (11). There is a gap in the literature concerning the surgical techniques that may overcome these limitations of immediate implant placement and simultaneously keep its advantages regarding the dimensional maintenance of the tooth socket. Therefore, this paper describes a case series of implant placement in bone granulation tissue, which allowed maintenance of tissue originality, significantly reduced the surgical bias of inadequate implant positioning, and benefited from the maximum regenerative capacity of bone cells.

## CASE REPORTS

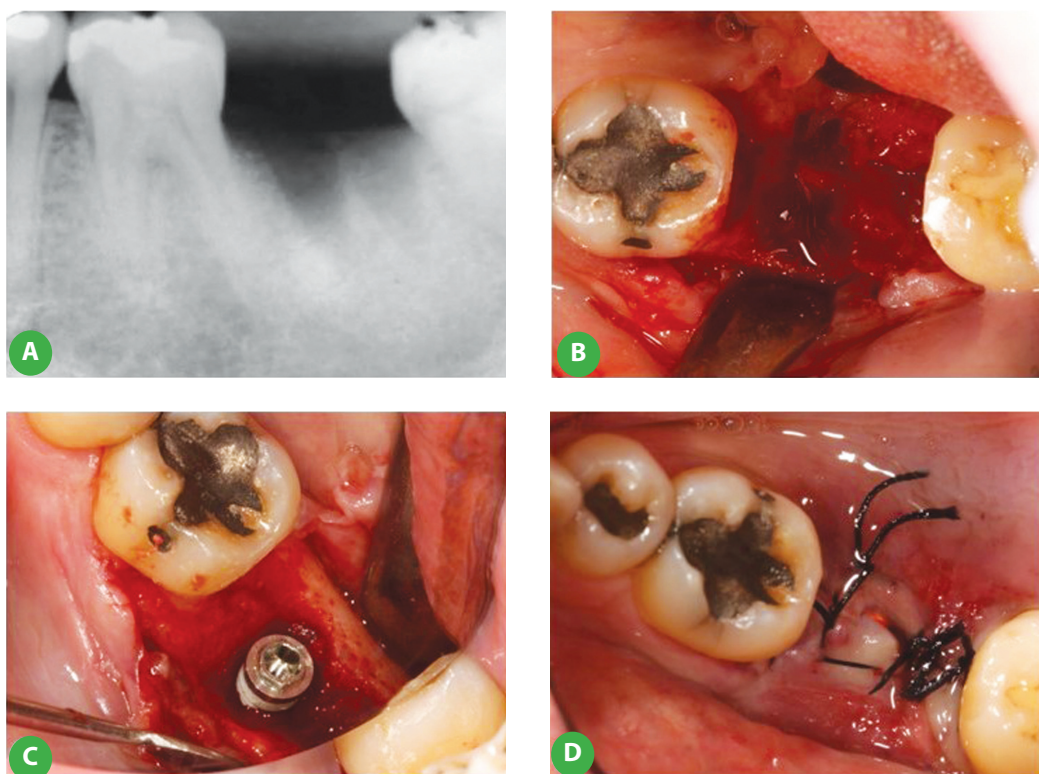
### Case 1

A 50-year-old male patient, systemically healthy, presented with complaint of pain due to endodontic abscess with a grade III furcation lesion in the mandibular left second molar, originated from a pulp chamber perforation (Fig. 1A).

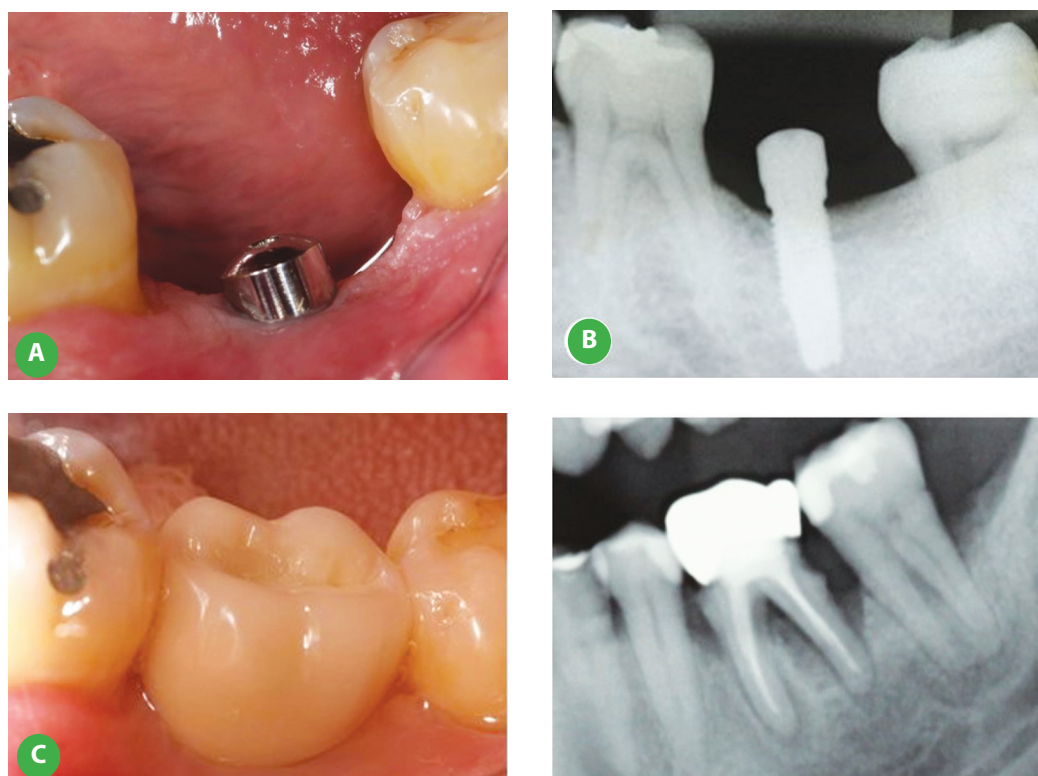
After extraction, the tooth socket was curetted to eliminate the granulation tissue and bone spiculae, and



**FIG.1** Initial radiographic image showing furcation involvement (A). Alveolus immediately after tooth extraction and removal of granulation tissue (B). Positioning of a bovine cortical membrane (GenDerm®, Baumer, Mogi Mirim, São Paulo, Brazil) to prevent soft tissue migration within the alveolar socket (C). Sutures (D).



**FIG. 2** Radiographic image after 21 days, indicating the presence of newly forming bone on the alveolar socket (A). Flap elevation and membrane removal, revealing the bone granulation tissue inside the alveolar socket (B). Placement of a 4.1-mm diameter and 13 mm long implant, in close contact with the bone granulation tissue (C). Sutures (D).



**FIG. 3** Clinical aspect after 6 months, showing a healthy peri-implant tissue (A). Radiographic image after 6 months, with signs of osseointegration and without the presence of bone loss (B). Two-year follow-up with a screwed implant-supported denture (C).

**FIG. 4** Initial radiographic image showing a compromised tooth with severe bone loss.

was decontaminated by irrigation with tetracycline hydrochloride diluted in saline at 50 mg/ml (Fig. 1B). To prevent soft tissue invagination, a bovine cortical membrane (GenDerm®, Baumer, Mogi Mirim, São Paulo, Brazil) was applied on the extraction socket (Fig. 1C). The flap was sutured (Fig. 1D) and amoxicillin 500 mg was prescribed three times a day for 7 days, besides nimesulide 100 mg twice a day for 3 days and 0.12% chlorhexidine digluconate mouthrinse every 12 hours. After 21 days, the region was reopened for placement of an external hex implant with double acid-etched surface (Strong®, SIN, São Paulo, Brazil), with 4.1-mm diameter and 13 mm length. The radiographic image indicated the presence of a still friable soft tissue on the alveolar socket, evidencing presence of newly forming bone (Fig. 2A). However, elevation of the flap was not more difficult than in mucogingival surgeries, and mature bone tissue was observed underlying the granulation tissue (Fig. 2B). Thus, the implant could be safely stabilized with a torque of 32 N/cm (Fig. 2C). The flap was sutured (Fig. 2D) and postoperative medication was prescribed according to the same protocol of the first intervention. After six months, clinical evaluation of the area revealed healthy peri-implant tissue, besides peri-implant sulcus and attached mucosa (Fig. 3A). Radiographic images indicated implant osseointegration and no bone loss (Fig. 3B). Then, the patient received a screwed implant-

supported denture with an UCLA castable abutment with Cr-Co base. At a two-year follow-up, it can be observed the maintained peri-implant health (Fig. 3C).

### Case 2

A systemically healthy 68-year-old male patient was diagnosed with acute marginal periodontal disease. His oral status with intense bone loss demanded extraction of the mandibular right first molar (Fig. 4). Since it was not possible to check the adequate decontamination of the region infected by periodontopathogens and filled with purulent secretion from a periodontal abscess, immediate implant placement was not indicated. Therefore, the tooth was extracted and the same steps described in case 1 for implant placement in bone granulation tissue were followed (Fig. 5, 6). After 5 months, the patient returned to our service with a clinical and radiographically satisfactory aspect (Fig. 7), proceeding to prosthetic rehabilitation.

### Case 3

A 77-year-old male patient with significant systemic conditions searched for treatment due to periodontal involvement of the mandibular right second premolar and first molar. Clinical evaluation revealed need of extraction of these teeth, followed by rehabilitation with implants. As for case 2, due to the local bacterial contamination,

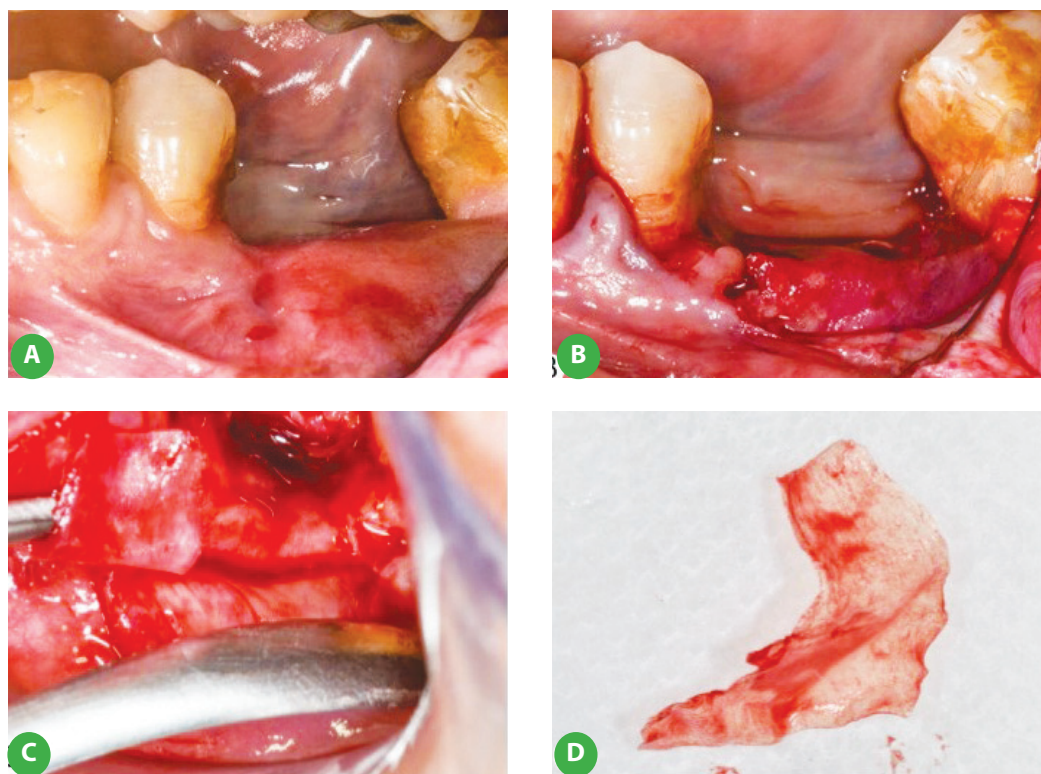


FIG. 5 Clinical aspect 21 days after extraction of the lower right first molar (A). Flap elevation, revealing the cortical membrane sealing the bone granulation tissue (B). Membrane removal (C). Cortical membrane aspect after removal (D).

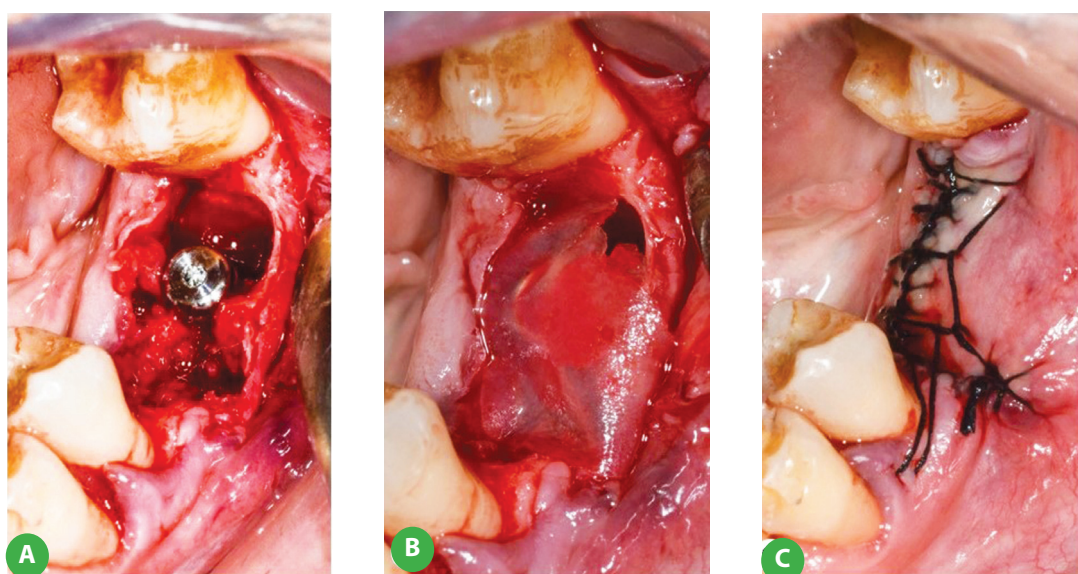


FIG. 6 Implant placement in contact with bone granulation tissue (A). The cortical membrane was reused to cover the healing socket (B). Sutures (C).

immediate implant placement was contraindicated, and the technique of implant placement in bone granulation tissue was selected. The clinical management followed the protocol described in case 1.

Prosthetic rehabilitation was performed 6 months after implant placement (Fig. 8A).

After 4 months, due to a crown fracture, a new crown

was made (Fig. 8B). The case was followed during 5 years (Fig. 8C).

#### Clinical outcomes

The cases were followed for periods ranging from 12 months to 5 years. The outcomes obtained on longitudinal follow-up revealed the relatively easy accomplishment

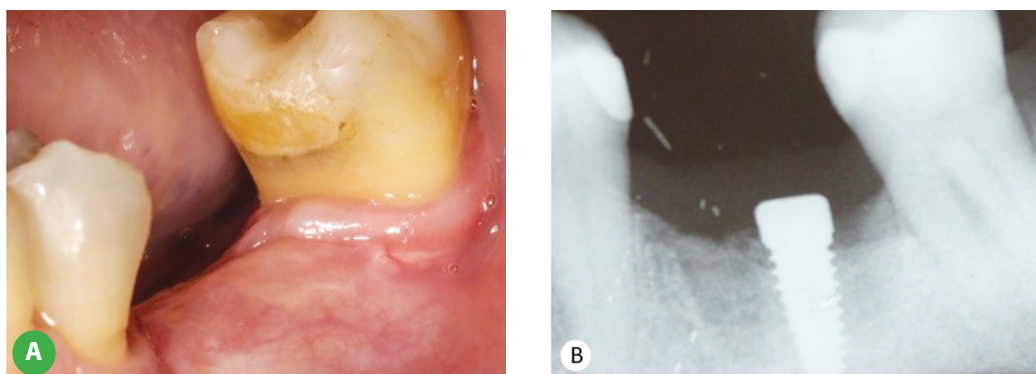


FIG. 7 Clinical aspect 5 months after implant placement (A). Radiographic image after implant placement, indicating osseointegration and no bone loss (B).

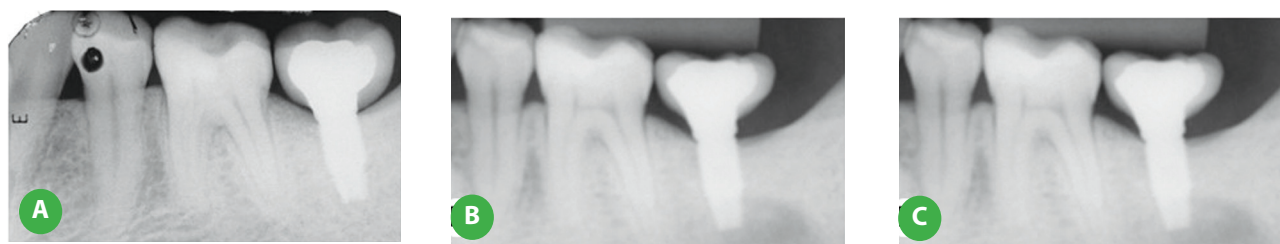


FIG. 8 Radiographic image after prosthetic rehabilitation, 6 months after implant placement with the bone granulation tissue technique (A). After 4 months, a new crown was made due to a fracture of the previous one (B). Five-year follow-up after implant placement, indicating the maintenance of surrounding bone (C).

of the technique, absolute decontamination of the area, formation of vital bone contacting the implant surface, primary stability and complete osseointegration in the expected period, with good three-dimensional positioning, satisfactory prosthetic outcomes, and predictable restorative esthetics.

## DISCUSSION

This paper describes an adaptation of the bone graft technique in area of newly forming bone or bone granulation tissue (12, 13) in implantology. It consists of placing the implant at the socket region 21 days after extraction. Within this period, the body manages to eliminate all infection and allows contact of the implant surface with a rich proliferating bone tissue. The three cases here presented demonstrate the long-term success of this technique.

The principles applied to this technique are based on studies that demonstrate that bone granulation tissue contains great quantity of osteogenic cells (12, 14-17) in several degrees of differentiation, and the healing socket contains a great number of undifferentiated cells, presenting greater regenerative potential compared to mature osteoblasts (12, 17). Bone granulation cells present proliferative characteristics compatible with osteoblasts, with slower growth rate compared to gingival fibroblasts, and are identified as osteoprogenitor

cells (18), participating in bone repair in the period from 21 to 25 days after extraction.

Most studies demonstrate that immediate and early implants present similar success rates as late implants (19, 20), indicating that the present technique may achieve similar success rates as reported in the literature for other techniques of implant placement in fresh sockets. The advantages described for placement of Types 1, 2 and 3 (immediate, early and early-delayed) implants (20-26) are also applicable to the technique of implant placement in bone granulation tissue, including the reduced treatment time and number of surgical procedures, higher bone availability for primary anchorage and ideal implant positioning, better interarch relationship, optimized esthetics of soft tissues and greater patient satisfaction. Immediate implants may present greater risk of infection and associated failures in case of socket infection (27), corroborating the main indication of the present technique, which comprises implant placement at a later moment, yet still early, to assure complete decontamination and avoid a possible late infection. Other disadvantages reported in the literature associated with immediate implants, such as presence of gaps between the implant surface and the socket wall and the need to raise flaps for primary wound closure in cases of two-stage implants (27), are also well managed by the present technique. After 21 days of healing process, soft tissue availability allows total wound closure, and the bone 'gaps' are filled with autogenous material already present

in the extraction socket, which avoids the gaps between bone and implant surfaces and also provides a graft full of undifferentiated cells, with greater regenerative potential compared to mature osteoblasts.

During surgery for implant placement, it is common to observe resorption of the socket bone walls due to the disease process itself, or even as a result of the surgical technique for extraction of the affected tooth, which may be overcome by implant placement in bone granulation tissue, while maintaining the advantages described for immediate implant placement. Regarding these problems, some observations from the literature are necessary to better understand the indication and dynamics of the present new technique.

The initial stages of socket healing are characterized by dimensional alterations (28), with osteoclastic activity on the buccal and lingual bone crests, leading several authors to indicate the immediate implant placement in an attempt to maintain the bone plates (29, 30). However, despite maintaining the bone architecture in general, the presence of an implant does not completely prevent bone remodeling after extraction, especially concerning the buccal plate (23, 25). According to the above mentioned biological process, placement of implants Types 1 and 2 (immediate and early implants) might cause esthetic failures after alveolar healing; since the degree of bone remodeling is unpredictable, unfavorable esthetic outcomes, especially in the anterior maxillary region, might occur due to undesirable implant exposure (27). Once again, the present technique might minimize such inadequate outcomes, since the implant is placed after the period of greater dimensional alteration, which enhances the predictability concerning its placement to avoid the exposure of implant threads.

## CONCLUSION

The follow-up of the case series presented show that the proposed treatment provided clinical success, and the presence of bone granulation tissue surrounding the implant surface assured both osseointegration and esthetic harmony of prosthetic reconstructions, indicating that this technique is a viable option within the dental implant armamentarium. However, further studies are necessary to better understand the biological factors involved in the technique, especially phenomena related to a possible modulation of bone resorption after extraction and formation of vital bone in shorter time.

## Conflict of interests

The authors declare no financial and non-financial competing interests.

## Consent

Written informed consent was obtained from the patient

for publication of this case report and accompanying images.

## Funding

The authors declare that they received no funding.

## REFERENCES

- Esposito M, Grusovin MG, Maghaireh H, Worthington HV. Interventions for replacing missing teeth: different times for loading dental implants. *Cochrane Database Syst Rev* 2013;CD003878.
- Dodson TB. Predictors of dental implant survival. *J Mass Dent Soc* 2006;54:34-38.
- French D, Larjava H, Ofec R. Retrospective cohort study of 4591 Straumann implants in private practice setting, with up to 10-year follow-up. Part 1: multivariate survival analysis. *Clin Oral Implants Res* 2015;26:1345-1354.
- Lin GH, Chan HL, Bashutski JD, Oh TJ, Wang HL. The effect of flapless surgery on implant survival and marginal bone level: a systematic review and meta-analysis. *J Periodontol* 2014;85:e91-103.
- Markose J, Suresh S, Eshwar S, Rekha K, Jain V, Manvi S. Comparison of platform switched and sloping shoulder implants on stress reduction in various bone densities: Finite Element Analysis. *J Contemp Dent Pract* 2017;18:510-515.
- Wallace SS, Froum SJ. Effect of maxillary sinus augmentation on the survival of endosseous dental implants. A systematic review. *Ann Periodontol* 2003;8:328-343.
- Schrott A, Riggi-Heiniger M, Maruo K, Gallucci GO. Implant loading protocols for partially edentulous patients with extended edentulous sites--a systematic review and meta-analysis. *Int J Oral Maxillofac Implants* 2014;29 Suppl:239-255.
- Stafford GL. Different loading times for dental implants - no clinically important differences? *Evid Based Dent* 2013;14:109-110.
- Malo P, Nobre M. Flap vs. flapless surgical techniques at immediate implant function in predominantly soft bone for rehabilitation of partial edentulism: a prospective cohort study with follow-up of 1 year. *Eur J Oral Implantol* 2008;1:293-304.
- Cobo-Vazquez C, Reininger D, Molinero-Mourelle P, Gonzalez-Serrano J, Guisado-Moya B, Lopez-Quiles J. Effect of the lack of primary stability in the survival of dental implants. *J Clin Exp Dent* 2018;10:e14-e19.
- Mengel R, Schroder T, Flores-de-Jacoby L. Osseointegrated implants in patients treated for generalized chronic periodontitis and generalized aggressive periodontitis: 3- and 5-year results of a prospective long-term study. *J Periodontol* 2001;72:977-989.
- Passanezi E, Janson WA, Nahas D, Campos Junior A. Newly forming bone autografts to treat periodontal infrabony pockets: clinical and histological events. *Int J Periodontics Restorative Dent* 1989;9:140-153.
- Sant'ana AC, Ferraz BF, de Rezende ML, Greggi SL, Damante CA, Passanezi E. Newly forming bone graft: a novel surgical approach to the treatment of denuded roots. *J Appl Oral Sci* 2012;20:392-398.
- Amler MH. The effectiveness of regenerating versus mature marrow in physiologic autogenous transplants. *J Periodontol* 1984;55:268-272.
- Cardaropoli G, Araujo M, Hayacibara R, Sukekava F, Lindhe J. Healing of extraction sockets and surgically produced - augmented and non-augmented - defects in the alveolar ridge. An experimental study in the dog. *J Clin Periodontol* 2005;32:435-440.
- Evian CI, Rosenberg ES, Coslet JG, Corn H. The osteogenic activity of bone removed from healing extraction sockets in humans. *J Periodontol* 1982;53:81-85.
- Penteado R, Romito GA, Pustiglioni FE, Marques MM. Morphological and proliferative analysis of the healing tissue in human alveolar sockets covered or not by na e-PTFE membrane: a preliminar immunohistochemical and ultrastructural study. *Braz J Oral Sci* 2005;4:664-669.
- Heberer S, Wustlich A, Lage H, Nelson JJ, Nelson K. Osteogenic potential

- of mesenchymal cells embedded in the provisional matrix after a 6-week healing period in augmented and non-augmented extraction sockets: an immunohistochemical prospective pilot study in humans. *Clin Oral Implants Res* 2012;23:19-27.
19. Annibaldi S, Bignozzi I, Iacovazzi L, La Monaca G, Cristalli MP. Immediate, early, and late implant placement in first-molar sites: a retrospective case series. *Int J Oral Maxillofac Implants* 2011;26:1108-1122.
  20. Esposito M, Barausse C, Pistilli R, et al. Immediate loading of post-extractive versus delayed placed single implants in the anterior maxilla: outcome of a pragmatic multicenter randomised controlled trial 1-year after loading. *Eur J Oral Implantol* 2015;8:347-358.
  21. Esposito M, Grusovin MG, Polyzos IP, Felice P, Worthington HV. Interventions for replacing missing teeth: dental implants in fresh extraction sockets (immediate, immediate-delayed and delayed implants). *Cochrane Database Syst Rev* 2010:CD005968.
  22. Esposito M, Grusovin MG, Polyzos IP, Felice P, Worthington HV. Timing of implant placement after tooth extraction: immediate, immediate-delayed or delayed implants? A Cochrane systematic review. *Eur J Oral Implantol* 2010;3:189-205.
  23. Felice P, Pistilli R, Barausse C, Trullenque-Eriksson A, Esposito M. Immediate non-occlusal loading of immediate post-extractive versus delayed placement of single implants in preserved sockets of the anterior maxilla: 1-year post-loading outcome of a randomised controlled trial. *Eur J Oral Implantol* 2015;8:361-372.
  24. Felice P, Soardi E, Piattelli M, Pistilli R, Jacotti M, Esposito M. Immediate non-occlusal loading of immediate post-extractive versus delayed placement of single implants in preserved sockets of the anterior maxilla: 4-month post-loading results from a pragmatic multicentre randomised controlled trial. *Eur J Oral Implantol* 2011;4:329-344.
  25. Felice P, Zucchelli G, Cannizzaro G, et al. Immediate, immediate-delayed (6 weeks) and delayed (4 months) post-extractive single implants: 4-month post-loading data from a randomised controlled trial. *Eur J Oral Implantol* 2016;9:233-247.
  26. Menini M, Signori A, Tealdo T, et al. Tilted implants in the immediate loading rehabilitation of the maxilla: a systematic review. *J Dent Res* 2012;91:821-827.
  27. Zhao D, Wu Y, Xu C, Zhang F. Immediate dental implant placement into infected vs. non-infected sockets: a meta-analysis. *Clin Oral Implants Res* 2016;27:1290-1296.
  28. Araujo MG, Lindhe J. Dimensional ridge alterations following tooth extraction. An experimental study in the dog. *J Clin Periodontol* 2005;32:212-218.
  29. Qabbani AA, Razak NHA, Kawas SA, Sheikh Abdul Hamid S, Wahbi S, Samsudin AR. The Efficacy of Immediate Implant Placement in Extraction Sockets for Alveolar Bone Preservation: A Clinical Evaluation Using Three-Dimensional Cone Beam Computerized Tomography and Resonance Frequency Analysis Value. *J Craniofac Surg* 2017;28:e318-e325.
  30. Vera C, De Kok IJ, Chen W, Reside G, Tyndall D, Cooper LF. Evaluation of post-implant buccal bone resorption using cone beam computed tomography: a clinical pilot study. *The Int J Oral Maxillofac Implants* 2012;27:1249-1257.