

A modified graftless sinus lift: case report

➤ **S. D'AMATO, N. SGARAMELLA, G. TARTARO, M. SANTAGATA**

Division of Oral and Maxillofacial Surgery, Multidisciplinary Department of Medical-Surgical and Dental Specialties. AOU – University of Campania “Luigi Vanvitelli”, Naples, Italy

TO CITE THIS ARTICLE

D'Amato S, Sgaramella N, Tartaro G, Santagata M. A modified graftless sinus lift: case report. *J Osseointegr* 2019;11(1):7-10.

DOI 10.23805 /JO.2019.11.01.02

ABSTRACT

Aim AAA (Alveolar Antral Artery) injuries are the most frequent intra-operative lesions occurring during maxillary sinus surgery. The aim of this work is to evaluate the role of preoperative CBCT and the effectiveness of piezosurgery to prevent bleeding. Furthermore, a modified Lundgren technique is presented, that can significantly reduce the risk of bleeding and of damages to maxillary sinus structures.

Methods A case of maxillary sinus lift with immediate implants placement is reported. Preoperative CBCT scan allowed to study the course in the anterior-lateral sinus wall of the AAA and the variability of its patency. Anrostomy was performed with piezosurgery device.

Results Through preoperative identification of the course of the artery and trough this modified piezosurgery technique, it was possible to preserve membrane and artery integrity. Schneider membrane therefore was detached from the sinus floor, and contextually three implants were positioned.

Conclusions In the preoperative phase, a study with CBCT scan is suggested, in order to identify intraosseous arterial course, patency variability and the distance from alveolar ridge. Furthermore, it is strongly recommended the use of piezosurgery, to preserve vascular structures and soft tissues. A modified Lundgren technique can be useful to avoid the use of round bur and thus reduce the risk of perforation of the underlying structures.

KEYWORDS Sinus lift; Antral artery; Modified Lundgren technique.

INTRODUCTION

The Alveolar Antral Artery (AAA) is an intraosseous

anastomosis between the posterior superior alveolar artery (PSAA) and the infraorbital artery (IOA) (1); it gives blood supply to the Schneiderian membrane and maxillary sinus and periosteum. AAA can be easily damaged during surgical procedures that require opening of the lateral maxillary sinus wall; particularly, perforation of sinus membrane and lesion of AAA are the most frequent intra-operative complications during maxillary sinus floor elevation (2, 3). AAA preservation can be difficult, due to the variation of diameter, anatomical course and distance from the alveolar ridge.

The purpose of this work is to illustrate how an adequate preoperative radiographic evaluation and the use of piezosurgery device can be useful to prevent bleeding complications. Moreover, the surgical approach, here proposed, is a modified Lundgren technique: the changes made to the original technique allow to obtain the bone window less traumatically, both for the sinus membrane and for vascular structures.

According the original Lundgren technique (4), after having exposed the sinus wall, a bone window is marked with a small round bur and then cut with a reciprocating microsaw. The saw is tilted during the osteotomy to stably replace the window after surgery. The sinus membrane is dissected to create a compartment for the implants. In the present case, piezosurgery was used to perform the osteotomy, with the saw tilted as in the original technique, but without marking the window with round bur, thus reducing the risk of perforating soft tissues. The use of piezosurgery allows further preservation of vascular and nervous structures.

Moreover, in the present case, surgery was planned with preoperative CBCT-scan, as suggested by several authors. Often AAA has a variable diameter and its intraosseous course can vary too, therefore CT-scan is necessary to design correctly the bone window and to reduce the risk of intra-operative complications, such as the injury of antral artery.

The aim of this work is to illustrate how the association between preoperative CBCT and a modified Lundgren technique performed with piezosurgery significantly reduces the risk of AAA injuries.

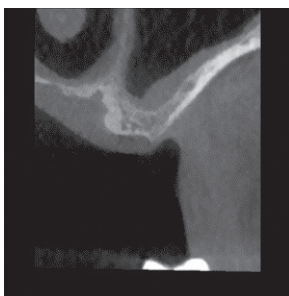


FIG. 1 Preoperative CBCT scan allowed to study the course in the anterior-lateral sinus wall of AAA and the variability of its patency.

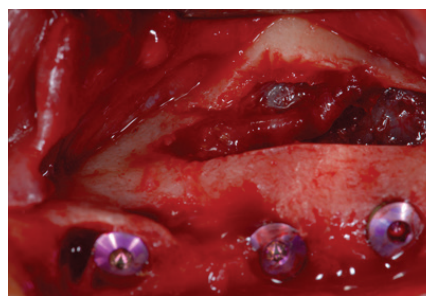


FIG. 2 Once removed the bone fragment, immediately below the AAA, the Schneiderian membrane appeared.

CASE REPORT

A male patient (AC), aged 38 years, with no history of previous or current diseases, presented with maxillary lateral edentulism in the left area. The preliminary radiographic evaluation showed bone dimensions of about 3 to 4 mm in the coronal direction and 6 to 7 mm in the bucco-palatal direction. After the preliminary evaluation, the operation planning started. The rehabilitation of this maxillary edentulism was solved through the placement of three fixtures with the contextual graftless sinus augmentation procedure. In the present case three 3.75 x 11.5 implants (MIS Seven; MIS, Barlev, Israel) were placed for immediate load. The preoperative Cone-beam CT scan allowed to study the course in the anterior-lateral sinus wall of AAA and the variability of its patency (Fig. 1). The vessel course is intraosseous and CT-scan images helped to identify the artery position and allow correct planning of bone windows. Vessel course was highlighted using a surgical pencil on the lateral wall of the sinus, after making the incision and after having raised a mucoperiosteal flap.

Surgical technique

The surgical procedure was performed under local anesthesia (mepivacaine plus epinephrine 1:200.000). The technique used to approach the maxillary sinus was performed creating a replaceable bone window using a piezoelectric bone-cutting instrument (Mectron, Italy): with OT7 tip, an osteotomy of approximately 13 mm in width and height was made on the lateral maxillary sinus wall. This technique was a modification of the one described by Lundgren et al. (4). The piezoelectric bone-cutting instrument was tilted to make a tapered osteotomy; this kind of osteotomy ensures the stability of the bone window when replaced after surgery. Once removed the bone fragment, immediately below the AAA appeared, and, still below, the Schneiderian membrane (Fig. 2): through preoperative identification of the course of the vessel and trough this modified piezosurgery technique, it was possible to preserve membrane and vessel integrity. Schneider membrane was dissected around the margins of the window, extended inferiorly, and elevated from the floor of the maxillary sinus using curettes. After a careful dissection of the sinus membrane, dental implants were inserted (3.75 x 11.5 MIS Seven; MIS, Barlev, Israel) and

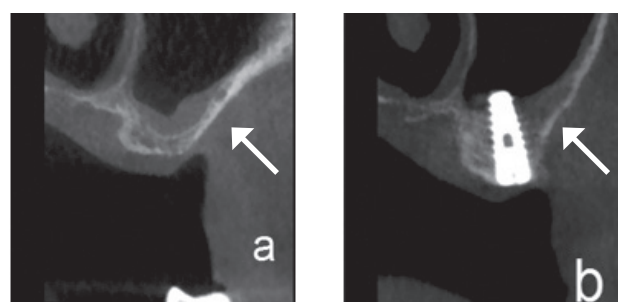


FIG. 3 A comparison between preoperative (A) and postoperative (B) condition, where maxillary sinus bone good healing, bone fragment repositioning, and the integrity of AAA can be observed.

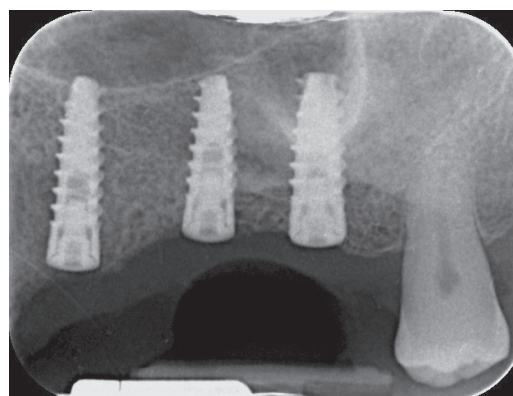


FIG. 4 A postoperative view of three implants.

protruded into the sinus, where the membrane formed a raised "tent" over the implants. After implant insertion, the bone window was replaced in its original position. Finally, once repositioned the bone fragment, the mucoperiosteal flap was sutured. A comparison between preoperative and postoperative, with healing of maxillary sinus and integrity of AAA are showed in figure 3; in figure 4, a postoperative view of the three implants positioned. Postoperative instructions were given, along with antibiotics (amoxicillin 875 mg plus clavulanic acid 125 mg two times daily) and analgesics (ibuprofen 400 mg three times daily).

DISCUSSION

Maxillary sinus lift is one of the most common procedures in the preprosthetic rehabilitation of the patient with atrophic maxilla. The implant positioning can be performed contextually or in a second time. Several complications are possible, but the most frequent are the perforation of sinus membrane and the injury of AAA. The lesion of AAA can cause massive hemorrhage. There are several measures (5) that can be adopted to manage this bleeding complication, such as electrocauterization, bone wax, use of gauzes moistened with tranexamic acid, or particulate bone graft associated with amalgam carrier; however, these methods are not always sufficient to contain the hemorrhage and often, in a few hours, hemosinus can occur. During the preoperative radiologic study, there are several factors that must be considered in order to reduce the risk of interference with the vessel. About AAA, the variability of its anatomical intraosseous course, of its patency and of mean distance from alveolar crest can be evaluated with preoperative CBCT, as reported by several authors (1, 5, 6, 7). Particularly, a study of Rahpeyma et al. (1) shows that AAA was present in 67% CBCTs and determined that there is a positive correlation between bone thickness and AAA diameter; in these cases, CBCT allows to evaluate the possible interference with the large intraosseous caliber of AAA. Danesh-Sani et al. (6), through preoperative CBCT scans, showed that there are different types of pattern in the course of AAA, of which the most frequent is intraosseous (70%), followed by the intrasinus one (24%), and, lastly, the superficial (6%); however, the course of the artery could be detected in 61% of scans.

Varela-Centelles et al. (7) remark how the mean distance of AAA from the alveolar crest decreases in case of atrophic crest, and how this factor significantly increases the risk of vessel injury and hemorrhage.

During surgery, especially if an interference with the vessel is expected, the use of piezoelectric saw is strongly recommended, also in order to preserve the Schneiderian membrane as suggested by several authors (8-11). We believed it was safer to modify the original Lundgren technique and not demarcate the bone window with round bur, in order not to perforate the membrane or AAA. The piezoelectric saw was tilted during the osteotomy to stably replace the window after surgery. These measures, in fact, proved useful in saving both AAA and membrane, although these were in close contact with the bone fragment to be removed.

CONCLUSION

In conclusion, the results from our experience suggest some factors to consider in order to reduce the risk of

AAA lesion, bleeding complications and membrane perforation:

1. In the preoperative phase, a study with Cone-beam CT scan is suggested, in order to identify vessel intraosseous course, caliber variability and the distance from alveolar ridge.
2. During the surgical time, it is strongly recommended the use of piezosurgery, to save vascular structures and soft tissues. We consider it useful to perform a modified Lundgren technique, because it avoids the use of round bur and so reduces the risk of perforation of the underlying structures. This can be useful especially in case of very thin anterolateral sinus wall, or when AAA and/or sinus membrane are strictly adhering to the bone wall.

Conflict of interest

None, nothing to declare. No funding, no conflict of interest.

REFERENCES

1. Rahpeyma A, Khajehahmadi S, Amini P. Alveolar Antral Artery: does its diameter correlate with maxillary lateral wall thickness in dentate patients? *Iran J Otorhinolaryngol* 2014 Jul;26(76):163-7.
2. Solar P, Geyerhofer U, Traxler H, Windisch A, Ulm C, Watzek G. Blood supply to the maxillary sinus relevant to sinus floor elevation procedures. *Clin Oral Implants Res* 1999 Feb;10(1):34-44.
3. Maridati P, Stoffella E, Speroni S, Cicciu M, Maiorana C. Alveolar antral artery isolation during sinus lift procedure with the double window technique. *Open Dent J* 2014 May 30;8:95-103.
4. Lundgren S, Andersson S, Gualini F, Sennerby L. Bone reformation with sinus membrane elevation: a new surgical technique for maxillary sinus floor augmentation. *Clin Implant Dent Relat Res* 2004;6(3):165-73.
5. Valente NA. Anatomical Considerations on the Alveolar Antral Artery as Related to the Sinus Augmentation Surgical Procedure. *Clin Implant Dent Relat Res* 2016 Oct;18(5):1042-1050.
6. Danesh-Sani SA, Movahed A, ElChaar ES, Chong Chan K, Amintavakoli N. Radiographic Evaluation of Maxillary Sinus Lateral Wall and Posterior Superior Alveolar Artery Anatomy: A Cone-Beam Computed Tomographic Study. *Clin Implant Dent Relat Res* 2017 Feb;19(1):151-160.
7. Varela-Centelles P, Loira-Gago M, Gonzalez-Mosquera A, Seoane-Romero JM, Garcia-Martin JM, Seoane J. Distance of the alveolar antral artery from the alveolar crest. Related factors and surgical considerations in sinus floor elevation. *Med Oral Patol Oral Cir Bucal* 2016 Nov 1;21(6):e758-e765.8).
8. Vercellotti T, De Paoli S, Nevins M. The piezoelectric bony window osteotomy and sinus membrane elevation: introduction of a new technique for simplification of the sinus augmentation procedure. *Int J Periodontics Restorative Dent*. 2001 Dec;21(6):561-7.
9. D'Amato S, Sgaramella N, Vanore L, Piombino P, Orabona GD, Santagata M. Piezoelectric bone surgery in the treatment of an osteoma associated with an impacted inferior third molar: a case report. *Clin Cases Miner Bone Metab*. 2014 Jan;11(1):73-6.
10. Itró A et al. The piezoelectric osteotomy technique compared to the one with rotary instruments in the surgery of included third molars. A clinical study. *Minerva Stomatol*. 2012 Jun;61(6):247-53.
11. Rossi F, Pasqualini ME, Grivet Brancot L, Colombo D, Corradini M, Lorè B, Calabrese L. Minimally invasive piezosurgery for a safe placement of blade dental implants in jaws with severe bone loss. *J Osseointegr* 2014;6(3):56-60.

