

# A comparative study of ridge preservation using calcium sulfate and collagen membrane with and without freeze-dried bone allograft following tooth extraction

➤ REZA AMIRZARGAR<sup>1</sup>, GHOLAMREZA SHIRANI<sup>2</sup>, HAMID MAHMOUDHASHEMI<sup>3</sup>, AHAD KHOSHZABAN<sup>4</sup>, MARZYEH HASHEMINEJAD<sup>5</sup>

<sup>1</sup> DDS, Chief resident of Oral And Maxillofacial Surgery, Department of Oral and Maxillofacial Surgery, School of Dentistry, Tehran University of Medical Sciences, Tehran, Iran

<sup>2</sup> DDS, OMFS, Assistant professor, Department of Oral and Maxillofacial Surgery, School of Dentistry, Tehran University of Medical Sciences, Tehran, Iran

<sup>3</sup> HDDS, OMFS, Professor, Department of Oral and Maxillofacial Surgery, School of Dentistry, Tehran University of Medical Sciences, Tehran, Iran

<sup>4</sup> DDS, Phd, Private practitioner, Iranian tissue bank research center, Tehran University of Medical Sciences, Tehran, Iran

<sup>5</sup> DDS, resident of Periodontology, School of Dentistry, Isfahan University of Medical Sciences, Isfahan, Iran

## TO CITE THIS ARTICLE

Amirzargar R, Shirani G, Mahmoudhashemi H, Khoshzaban A, Hasheminejad M. A comparative study of ridge preservation using calcium sulfate and collagen membrane with and without freeze-dried bone allograft following tooth extraction. *J Osseointegr* 2018;10(1):11-16.

DOI 10.23805 /JO.2018.10.01.02

**KEYWORDS** Alveolar ridge preservation, Calcium sulfate, Freeze-dried bone allograft, Socket preservation.

## ABSTRACT

**Aim** Alveolar ridge resorption after tooth extraction is a growing challenge in implant therapy. Various surgical techniques have been suggested to minimize ridge volume loss. In this study, we compared the efficacy of medical grade calcium sulfate (MGCS) with and without freeze-dried bone allograft (FDBA) in alveolar ridge preservation.

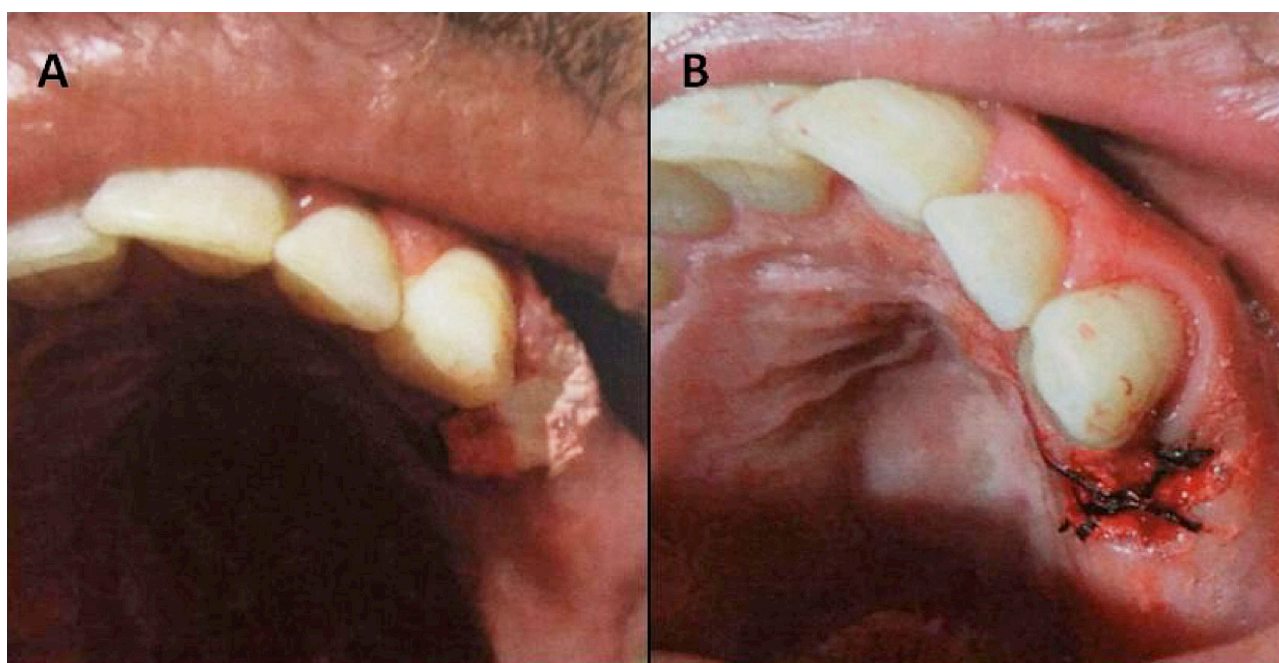
**Materials and Methods** In this randomized clinical trial, we assigned 77 premolar and molar extracted sockets to the following groups: MGCS (n=26), MGCS+FDBA (n=25), and control (no intervention; n=26). The filled sockets were covered by a collagen membrane. All groups returned 3 months after the intervention. We used a digital caliper and intraoral parallel radiography to assess changes in ridge width and height.

**Results** A total of 64 out of 77 patients returned for the 3-month follow-up. No significant difference existed between the groups with respect to age, gender, type and position of the extracted teeth. The control group had significantly greater reductions in both ridge width and height compared to the MGCS and MGCS+FDBA groups ( $P<0.0001$ ). We observed no significant difference between the MGCS and MGCS+FDBA groups with respect to alterations in the alveolar ridge dimensions ( $P>0.05$ ). Men had significantly greater changes in ridge height compared to women ( $P<0.01$ ). Alterations in ridge width were significantly higher in the mandibular compared to maxillary teeth ( $P<0.05$ ).

**Conclusion** There is no difference between effectiveness of MGCS and MGCS+FDBA in preserving human ridge dimensions up to 3 months after a tooth extraction. However, additional studies are proposed to verify these results.

## INTRODUCTION

A tooth and its surrounding tissues (i.e., cementum, periodontal ligament, and bundle bone) form a functional unit that transfers a force to the jaw bone during chewing (1). Alveolar bone resorption following tooth extraction and alterations in gingival contours are a major concern in treatment plan (2, 3). Although the underlying mechanism is uncertain, lack of function in the absence of a tooth appears to drive bone resorption as a physiological response of the cells to adapt to a new condition (4). In addition, local inflammation, surgical trauma due to tooth extraction, and reduced blood supply to tissues that have low function contribute to alveolar ridge resorption (5). The resorption rate is 10 times higher during the first year after tooth extraction (6). Changes in the volume of the alveolar ridge may cause failure of the fixed prosthesis, implant therapy, implant survival, and chewing force transfer to the bone (1, 7). Various surgical techniques proposed to minimize alveolar ridge volume loss include immediate implantation, limited flap elevation, atraumatic extraction, use of barrier membranes, grafts, and bone substitutes/fillers in the sockets (2, 3, 12-14). Although immediate implantation to restore function of the ridge has been recommended as the best approach, it is not always applicable or is ineffective for reducing resorption in the buccal wall;



**FIG. 1** Filling the socket with medical-grade calcium sulfates, with or without Freeze-Dried Bone Allograft covered by collagen membrane (A), and then fixed with suture (B).

in these cases, preservation with membrane and bone grafts is a favorable alternative (8, 9). Calcium sulfate (CS) has long attracted the attention of clinicians as a widely available, relatively inexpensive biomaterial for use in orthopedics and dentistry for periodontal defect repairs, as well as protection of bone resorption without causing considerable inflammation (15-17). In addition, membranes that cover the filled bone are believed to decrease the resorption process (18-20); however, evidence has shown no significant difference in resorption rate with or without a membrane (21). Various mineralized and demineralized freeze-dried bone allografts (FDBAs) have been recently introduced for alveolar ridge preservation (22, 23). To the best of our knowledge, there is no evidence regarding the effectiveness of the combination of CS and FDBA in alveolar ridge preservation after tooth extraction. In the current study, we have compared the efficacy of medical-grade CS (MGCS) alone and in combination with FDBA in terms of a decreased alveolar ridge resorption rate among Iranian patients.

## MATERIALS AND METHODS

This study enrolled a total of 77 premolar and molar sockets from extracted teeth of 77 individuals, aged 17-46 years, who referred to the Oral and Maxillofacial Surgery Ward of the Dental School of Tehran University of Medical Sciences for tooth extraction during February-May 2012. The procedure was done with an expertise attending member.

Inclusion criteria were as follows.

The teeth numbers 4, 5, or 6 according to the Palmer Notation Numbering System needed to be extracted due to endodontic problems or tooth decay.

A tooth was adjacent to the socket of the extracted tooth.

Socket walls remained intact, and the thickness of the buccal and palatal/lingual plates was 0.8-1.3 mm. Exclusion criteria consisted of: ankylosed tooth, socket walls fracture during tooth extraction, chronic or aggressive periodontitis, periodontal or periapical abscess, loose tooth, bone loss, and systemic disease infection, graft and membrane exposure, pregnancy, breast-feeding and medication consumption that altered bone metabolism (i.e., bisphosphonates, glucocorticoids, long term NSAID therapy).

We randomly assigned participants to three groups: MGCS (n=26), MGCS+FDBA (n=25), and control (n=26). The control group did not undergo any socket preservation techniques. Each individual received local anesthesia (lidocaine with epinephrine 1:80000) at the site of the target tooth. The tooth extraction was done simply and atraumatically as a routine way and we tried to preserve all socket walls during procedure. After tooth extraction, we measured the buccal and lingual wall thicknesses, approximately 3 mm below the gingival margin with a digital caliper. Considering the gingival thickness between 0.8-1.3 mm. After washing with normal saline, the socket was filled with MGCS particles (120  $\mu$ m) or with MGCS+FDBA. Next, we covered each socket from both groups with a collagen membrane fixed with a suture (Fig. 1). The

control group received no intervention. We assessed the height of the alveolar ridge by intraoral parallel radiography using Ektaspeed Plus Dental X-ray film (Kodak) and an XCP-DS Sirona Dental System (Kerr, Total Care, Swiss) at 70 kVp, 8 mA, and 0.4 S. Silicone teeth molding (Dental Line, Piraeus, Greece) for 75 S was made for standardization and repeatability of the radiography. A fissure bur was placed adjacent to the socket for magnification measurements.

Patients were prescribed 0.2% chlorhexidine gluconate mouthwash (bid for one week) and acetaminophen/codeine (300 mg/10 mg) each 8 hour for 3 days. They were asked to immediately contact or return in the case of continuous pain or signs of infection. At the three-month follow-up visit, we measured the alveolar width of the ridge, 3 mm below the ridge edge, using a digital caliper (Fig. 2A) with local anesthesia. We used an intraoral parallel radiograph to measure the alveolar height. The radiographs were transferred to a computer with a scanner (HP Scanjet G4010). We used Photoshop CS3 software (Adobe, USA) to draw an anatomical CEJ mesial and distal connecting line, as the reference line (Figure 2B). The distances between this line and three mesial, central and distal points at the top of the crest were measured in mm and reported in actual values based on the degree of magnification. This study has been approved by the ethics committee of research affair of Tehran University of medical sciences and all the participant signed an informed consent.

## RESULTS

A total of 64 patients came for the 3-month follow-up. All the follow up arrangement was done with one expert attending of oral and maxillofacial surgery. Ten patients did not return during follow ups arrangements, 2 patients in the MGCS group suffered severe pain following tooth extraction which was reduced by acetaminophen/codeine administration, and the membrane regressed in one patient in the MGCS+FDDBA group. According to Table 1, there was no significant difference between the MGCS and MGCS+FDDBA groups.

With respect to dimensional ridge alterations, we observed that the control group had significantly more reduction in the width of the alveolar ridge compared to the MGCS and MGCS+FDDBA groups ( $P<0.0001$ ). No significant difference existed between the MGCS and MGCS+FDDBA groups in reduction of the alveolar ridge width ( $P=0.654$ ) (Fig. 3A). There was significantly less reduction in the mean height of the ridge at the mesial, central and distal points in both the MGCS and MGCS+FDDBA groups compared to the control group ( $P<0.0001$ ). No significant difference existed between the MGCS and MGCS+FDDBA groups with respect to alteration in the height of the alveolar ridge ( $P=0.846$ ; Fig. 3B).

The observed differences in the width and height changes between the groups were independent of the age and gender of the patients according to

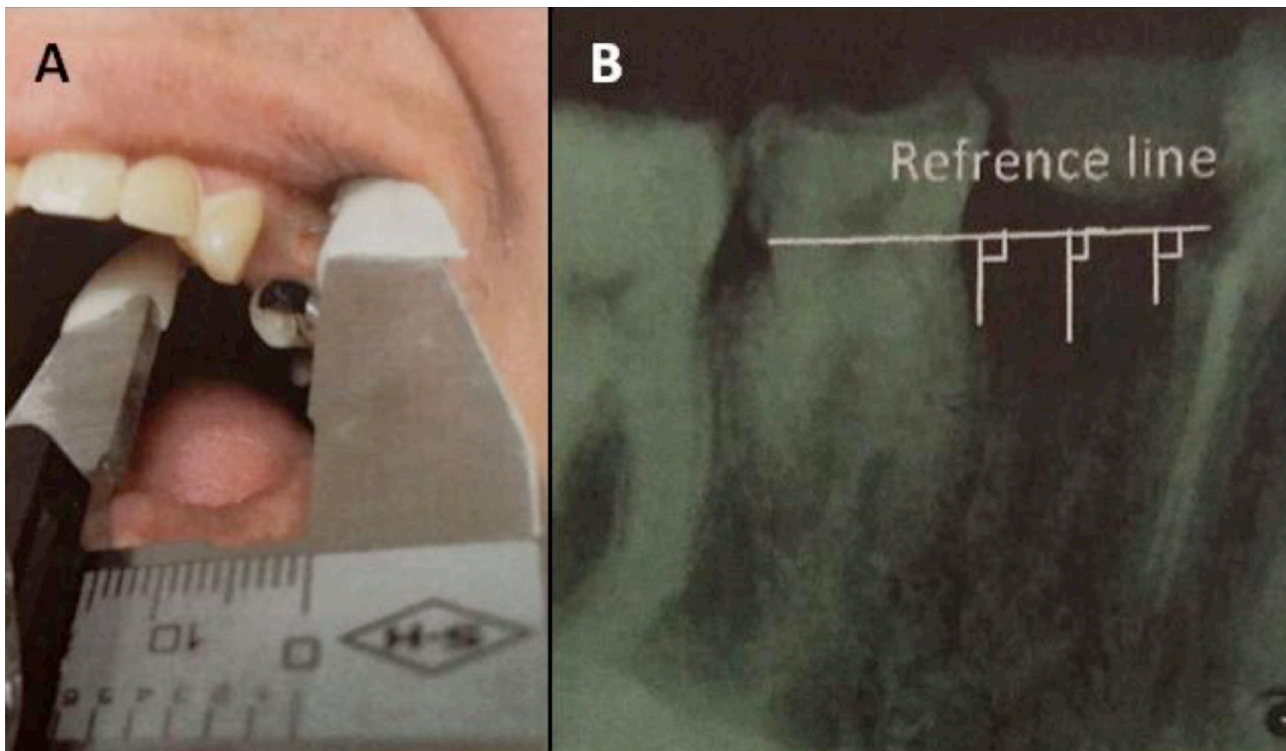


FIG. 2 Width and height of the ridge were measured using a digital caliper (A) and parallel intraoral radiograph (B), respectively.

Variable	MGCS* (n=22)	MGCS+ FDBA** (n=21)	Control (n=21)	P-value
Age, years (mean±SD)	31.73±6.35	31.14±7.6	31.43±8.69	0.969§
Gender (female: male)	14:8	12:9	14:7	0.732‡
Tooth position (Maxillary: mandibular)	14:8	15:6	14:7	0.517
Tooth type (Premolar: molar)	15:7	14:7	13:8	0.849

TABLE 1. Demographic and clinical features of the study groups.

§ One-way analysis of variance (ANOVA) - ‡ Chi-square - \*Medical grade calcium sulfate - \*\*Freeze-dried bone allograft

multivariate ANOVA. However, results of the intra-group analysis regarding gender revealed significantly greater changes in the height of the ridge in men compared to women ( $P < 0.01$ ), particularly at the central and distal points. The alterations in the ridge width were significantly higher in the mandibular compared to the maxillary teeth ( $P < 0.05$ ).

## DISCUSSION

In the present study, we compared the efficacy of MGCS with and without FDBA in the protection of alveolar bone ridge from resorption. Our results indicated that both approaches considerably preserved the ridge dimensions during 3 months after tooth extraction compared to the control group. However, no significant differences existed between the efficacy of MGCS alone and MGCS combined with FDBA in terms of ridge preservation at the 3-month follow-up. This observation supported results by Toloue et al. (24), who reported no significant difference between effectiveness of CS and FDBA in preserving

ridge dimensions at 3 months after tooth extraction. However, Toloue et al. (24) reported lower ridge resorption than observed in the current study. This discrepancy could be ascribed to different tooth type and sample size.

Our findings supported previous studies regarding the potential of MGCS to protect the alveolar ridge after tooth extraction (24-27). Aimetti et al. (25) demonstrated that ridge resorption significantly minimized in extraction sockets filled with CS. Although the reduction in the width of the ridge in our study agreed with Aimetti et al., the current study results showed greater ridge height reduction compared to their study. This discordance might result from a difference in measurement methods. Crespi et al. (6) also reported that both CS and magnesium-enriched hydroxyapatite (MHA) alone significantly delayed human extraction socket resorption during 3 months; however, MHA had a much greater preservation rate compared to CS. The ridge resorption reported by Crespi et al. (6) in the CS group was greater than that observed in our study. This variation might be due to the absence of buccal walls or a wider age range in

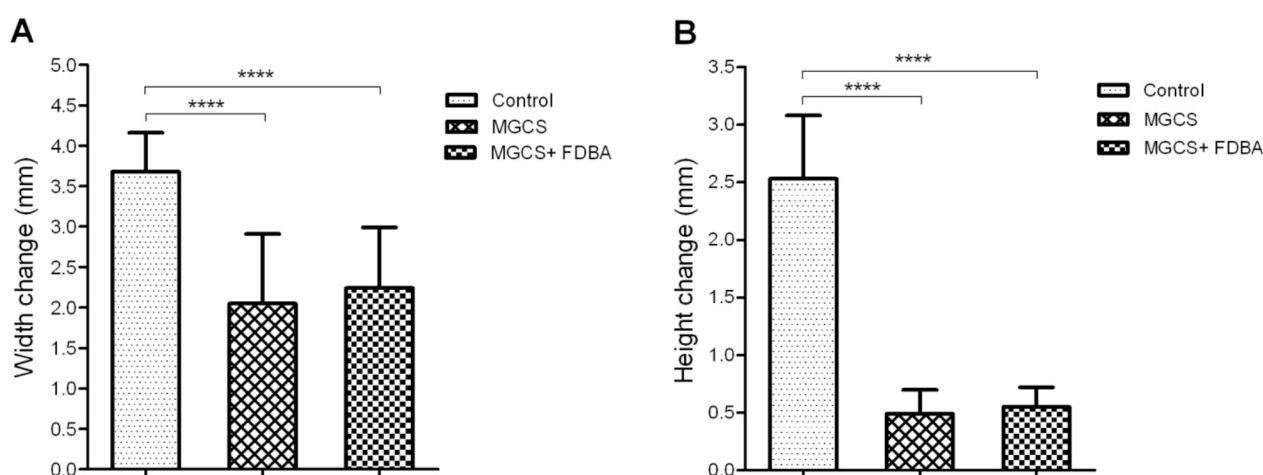


FIG. 3. Comparisons between medical grade calcium sulfate (MGCS), MGCS+freeze-dried bone allograft (FDBA), and control (no intervention) groups with respect to changes in the width (A) and height (B) of the socket/ridge at the 3-month follow-up.

their study. Our results were consistent with previous investigations regarding the beneficial effects of FDBA to lessen ridge dimension alterations (22, 28). Iasella et al. (28), in accordance with our study, found that FDBA diminished resorptive changes in the ridge dimensions after tooth extraction. In the current study, we observed greater resorption rate in both FDBA-treated and untreated groups. This difference might be attributed to the small sample size, non-molar tooth extraction, and modified digital caliper used to measure both width and height dimensions.

CS has been used in combination with numerous other materials in attempts to achieve maximum protective effects of alveolar ridge dimensions. Camargo et al. (30) evaluated the efficacy of combined CS with bioactive glass as a mechanical barrier to decrease ridge resorption after tooth extraction. They found that this approach reduced ridge resorption changes. However, they reported greater ridge width resorption compared to the current study results from both the MGCS and MGCS+FDBA groups. A logical explanation for this difference might be the type of materials as well as the longer follow-up period in the study by Camargo et al. On the other hand, we observed a greater ridge height loss compared to that reported by Camargo et al. (30), which was presumably the result of different measurement methods adopted by these two studies.

Several confounding variables might have influenced the results obtained from the present study. Firstly, it has been shown that pre-molar and molar teeth have differences in width and height loss in their alveolar ridges. This difference is due to differences in their socket wall thicknesses and cortical bone densities (12, 31). We have reported that ridge resorption did not significantly differ between molar and pre-molar sockets. Secondly, controversial data exist regarding the impact of tooth position on ridge resorption after extraction. Some investigators argue that maxillary sites are more vulnerable to ridge resorption loss due to increased blood supply, and therefore show a faster recovery or decay rate (3, 28). In contrast, several lines of evidence show that ridge resorption more likely occurs at mandibular sites compared to maxillary ones (33-35) due to the possibility of more traumatic tooth extraction in the lower jaw that leads to periosteal detachment, decreased blood supply, and osteocyte death in the mandibular sites with increased resorption (4). We have observed greater changes in the mandibular ridge width.

The gender effect on the ridge resorption has not been studied thus far. We observed significantly greater ridge height and width loss after tooth extraction in men. Henry et al. (36) reported that men had greater formation and resorption markers, and bone turnover. Therefore, the difference in ridge bone resorption observed in our study might have been caused by

elevated resorption markers or by increased trauma during the tooth extraction process due to higher bone density in men. With respect to age, there is a lack of evidence in the context of bone resorption. However, it has been suggested that this process is much faster in individuals older than 50 years of age (28). In the current study, we did not include individuals >50 years old. The study results showed no relation between age and ridge-dimension changes. It could be considered that systemic conditions might influence bone metabolism that stimulated resorption.

The surgery technique might determine the outcome in ridge preservation attempts (37, 38). Araujo and Lindhe (38) showed that flap elevation increased ridge resorption over a 2-4-month follow-up period, although it did not influence long-term outcome compared to the flapless operation. Accordingly, we took into consideration a shorter follow-up period in the present study and performed flapless surgery for all individuals to minimize the chance of resorption. A strength of this study was the parallel intra-oral radiography used to assess ridge height. This allowed us to monitor height changes based on three mesial, central and distal points with minimal change in radiography, which resulted in more validated data. However, a weakness of the study included the use of a modified digital caliper to measure the ridge width without flap elevation at the second measurement (3-month follow-up). We also did not histologically analyze the amount of new bone formation which might have been induced by MGCS. Other limits of the present study included the small sample size, shorter follow-up period, and lack of trauma control, all of which should be taken into account in future investigations.

## CONCLUSION

There appears to be no difference in effectiveness of MGCS alone and MGCS+FDBA in preserving human ridge dimensions up to 3 months after tooth extraction. However, we propose that more studies with larger sample sizes and longer follow-up periods should be performed to verify these results.

## ACKNOWLEDGMENTS

This study was financially supported by and performed at the Dental School of Tehran University of Medical Sciences and Iranian tissue bank research center, University of medical sciences. The authors would like to express their appreciation to all patients for their participation, as well as to the hospital personnel for their assistance with the study. The authors declare that they have no conflicting interests in the study results.

## REFERENCES

1. Misch CE. Contemporary implant dentistry. St. Louis, MO: Mosby Elsevier; 2008.
2. Cardaropoli D, Cardaropoli G. Preservation of the postextraction alveolar ridge: a clinical and histologic study. *Int J Periodontics Restorative Dent* 2008;28(5):469-77.
3. Irinakis T. Rationale for socket preservation after extraction of a single-rooted tooth when planning for future implant placement. *J Can Dent Assoc* 2006;72(10):917-22.
4. Araujo MG, Lindhe J. Dimensional ridge alterations following tooth extraction. An experimental study in the dog. *J Clin Periodontol* 2005;32(2):212-8.
5. Kubilius M, Kubilius R, Gleiznys A. The preservation of alveolar bone ridge during tooth extraction. *Stomatologija*.2012;14(1):3-11.
6. Schropp L, Wenzel A, Kostopoulos L, Karring T. Bone healing and soft tissue contour changes following single-tooth extraction: a clinical and radiographic 12-month prospective study. *Int J Periodontics Restorative Dent* 2003;23(4):313-23.
7. Crespi R, Cappare P, Gherlone E. Magnesium-enriched hydroxyapatite compared to calcium sulfate in the healing of human extraction sockets: radiographic and histomorphometric evaluation at 3 months. *J Periodontol* 2009;80(2):210-8.
8. Pagni G, Pellegrini G, Giannobile WV, Rasperini G. Postextraction alveolar ridge preservation: biological basis and treatments. *Int J Dent* 2012;2012:151030.
9. Fickl S, Zuhr O, Wachtel H, Stappert CF, Stein JM, Hurzeler MB. Dimensional changes of the alveolar ridge contour after different socket preservation techniques. *J Clin Periodontol* 2008;35(10):906-13.
10. Hoffmann O, Bartee BK, Beaumont C, Kasaj A, Deli G, Zafropoulos GG. Alveolar bone preservation in extraction sockets using non-resorbable dPTFE membranes: a retrospective non-randomized study. *J Periodontol* 2008;79(8):1355-69.
12. Vignoletti F, Matesanz P, Rodrigo D, Figuero E, Martin C, Sanz M. Surgical protocols for ridge preservation after tooth extraction. A systematic review. *Clin Oral Implants Res* 2012;23 Suppl 5:22-38.
13. Jamjoom A, Cohen RE. Grafts for Ridge Preservation. *J Funct Biomater* 2015;6(3):833-48.
14. Fernandes PG, Muglia VA, Reino DM, Maia LP, de Moraes Grisi MF, de Souza SL, et al. Socket preservation therapy with acellular dermal matrix and mineralized bone allograft after tooth extraction in humans: a clinical and histomorphometric study. *Int J Periodontics Restorative Dent* 2016;36(2):e16-25.
15. Thomas MV, Puleo DA. Calcium sulfate: Properties and clinical applications. *J Biomed Mater Res B Appl Biomater* 2009;88(2):597-610.
16. Guarnieri R, Pecora G, Fini M, Aldini NN, Giardino R, Orsini G, et al. Medical grade calcium sulfate hemihydrate in healing of human extraction sockets: clinical and histological observations at 3 months. *J Periodontol*. 2004;75(6):902-8.
17. Guarnieri R, Aldini NN, Pecora G, Fini M, Giardino R. Medial-grade calcium sulfate hemihydrate (surgiplaster) in healing of a human extraction socket-histologic observation at 3 months: a case report. *Int J Oral Maxillofac Implants* 2005;20(4):636-41.
18. Heinemann F, Hasan I, Schwahn C, Bourauel C, Mundt T. Bone level change of extraction sockets with Bio-Oss collagen and implant placement: a clinical study. *Ann Anat* 2012;194(6):508-12.
19. Al-Hezaimi K, Rudek I, Al-Hamdan KS, Javed F, Nooh N, Wang HL. Efficacy of using a dual layer of membrane (dPTFE placed over collagen) for ridge preservation in fresh extraction sites: a micro-computed tomographic study in dogs. *Clin Oral Implants Res* 2013;24(10):1152-7.
20. Simon BI, Zatcoff AL, Kong JJ, O'Connell SM. Clinical and histological comparison of extraction socket healing following the use of autologous Platelet-Rich Fibrin Matrix (PRFM) to ridge preservation procedures employing demineralized freeze dried bone allograft material and membrane. *Open Dent J* 2009;3:92-9.
21. Brkovic BM, Prasad HS, Rohrer MD, Konandreas G, Agrogiannis G, Antunovic D, et al. Beta-tricalcium phosphate/type I collagen cones with or without a barrier membrane in human extraction socket healing: clinical, histologic, histomorphometric, and immunohistochemical evaluation. *Clin Oral Investig* 2012;16(2):581-90.
22. Borg TD, Mealey BL. Histologic healing following tooth extraction with ridge preservation using mineralized versus combined mineralized-demineralized freeze-dried bone allograft: a randomized controlled clinical trial. *J Periodontol* 2015;86(3):348-55.
23. Sadeghi R, Babaei M, Miremadi SA, Abbas FM. A randomized controlled evaluation of alveolar ridge preservation following tooth extraction using deproteinized bovine bone mineral and demineralized freeze-dried bone allograft. *Dent Res J (Isfahan)* 2016;13(2):151-9.
24. Toloue SM, Chesnoiu-Matei I, Blanchard SB. A clinical and histomorphometric study of calcium sulfate compared with freeze-dried bone allograft for alveolar ridge preservation. *J Periodontol* 2012;83(7):847-55.
25. Aimetti M, Romano F, Griga FB, Godio L. Clinical and histologic healing of human extraction sockets filled with calcium sulfate. *Int J Oral Maxillofac Implants* 2009;24(5):902-9.
26. Kutkut A, Andreana S, Kim HL, Monaco E, Jr. Extraction socket preservation graft before implant placement with calcium sulfate hemihydrate and platelet-rich plasma: a clinical and histomorphometric study in humans. *J Periodontol* 2012;83(4):401-9.
27. Irinakis T, Tabesh M. Preserving the socket dimensions with bone grafting in single sites: an esthetic surgical approach when planning delayed implant placement. *J Oral Implantol* 2007;33(3):156-63.
28. Iasella JM, Greenwell H, Miller RL, Hill M, Drisko C, Bohra AA, et al. Ridge preservation with freeze-dried bone allograft and a collagen membrane compared to extraction alone for implant site development: a clinical and histologic study in humans. *J Periodontol* 2003;74(7):990-9.
29. Wood RA, Mealey BL. Histologic comparison of healing after tooth extraction with ridge preservation using mineralized versus demineralized freeze-dried bone allograft. *J Periodontol* 2012;83(3):329-36.
30. Camargo PM, Lekovic V, Weinlaender M, Klokkevold PR, Kenney EB, Dimitrijevic B, et al. Influence of bioactive glass on changes in alveolar process dimensions after exodontia. *Oral Surg Oral Med Oral Pathol Oral Radiol Endod* 2000;90(5):581-6.
31. Januario AL, Duarte WR, Barriviera M, Mesti JC, Araujo MG, Lindhe J. Dimension of the facial bone wall in the anterior maxilla: a cone-beam computed tomography study. *Clin Oral Implants Res* 2011;22(10):1168-71.
32. Huynh-Ba G, Pjetursson BE, Sanz M, Cecchinato D, Ferrus J, Lindhe J et al. Analysis of the socket bone wall dimensions in the upper maxilla in relation to immediate implant placement. *Clin Oral Implants Res* 2010;21(1):37-42.
33. Morjaria KR, Wilson R, Palmer RM. Bone healing after tooth extraction with or without an intervention: a systematic review of randomized controlled trials. *Clin Implant Dent Relat Res* 2014;16(1):1-20.
34. Ten Heggeler JM, Slot DE, Van der Weijden GA. Effect of socket preservation therapies following tooth extraction in non-molar regions in humans: a systematic review. *Clin Oral Implants Res* 2011;22(8):779-88.
35. Darby I, Chen S, De Poi R. Ridge preservation: what is it and when should it be considered. *Aust Dent J* 2008;53(1):11-21.
36. Henry YM, Eastell R. Ethnic and gender differences in bone mineral density and bone turnover in young adults: effect of bone size. *Osteoporos Int* 2000;11(6):512-7.
37. Engler-Hamm D, Cheung WS, Yen A, Stark PC, Griffin T. Ridge preservation using a composite bone graft and a bioabsorbable membrane with and without primary wound closure: a comparative clinical trial. *J Periodontol* 2011;82(3):377-87.
38. Araujo MG, Lindhe J. Ridge alterations following tooth extraction with and without flap elevation: an experimental study in the dog. *Clin Oral Implants Res* 2009;20(6):545-9.