

# An unconventional approach for retrieval of fractured prosthetic screw: A case report

> **A. JOSHI, V. T. KALE, G. SURAGIMATH, S. A. ZOPE**

School of Dental Sciences, Krishna Institute of Medical Sciences Deemed University, Karad, Dist.- Satara, Maharashtra, India, Pin

## TO CITE THIS ARTICLE

Joshi A, Kale VT, Suragimath, Zope SA. An Unconventional approach for retrieval of fractured prosthetic screw: A case report. J Osseointegr 2018;10(3):75-78.

DOI 10.23805 /JO.2018.10.03.02

## ABSTRACT

**Background** Implant-supported restorations can fail biologically or mechanically. Mechanical failures include crown fracture, framework fracture, screw loosening, and screw fracture. Fracture of the implant abutment screw can be a serious problem leading to implant failure. Unavailability of universal standard screw retrieval kit in market makes it difficult to retrieve the fractured screw of various implant systems.

**Conclusion** This clinical report describes the management of an implant prosthetic screw fracture using an unconventional technique and simple armamentarium available in regular clinic setup.

**KEYWORDS** Abutment screw, Diamond bur, Goldman Fox probe, Implants, Prosthetic screw, Ultrasonic tip.

## INTRODUCTION

Dental implants have become highly successful and widely accepted as a treatment for the replacement of missing teeth. The overall success rate of implants is above 90%, but still an implant treatment is not devoid of complications (1). Implant related complications are categorized into biological or mechanical complications (2). The surface treatments of dental implants have increased the predictability of osseointegration, thereby reducing the prevalence of biological complications.

Multiple components are involved in the superstructure of dental implants which can lead to mechanical complications. Mechanical complications include crown fractures, framework fractures, problems of retention, screw loosening and screw fracture (3). A prosthetic screw is required to connect the superstructure to the implant body which is embedded in the alveolar bone. When this particular assembly is subjected to the multidimensional repetitive load at the time of mastication, mechanical complications tend to occur. The abutment screw or prosthesis screw loosening is one of the most frequent mechanical complications followed by the screw fracture, which have a common etiology like bruxism, ill-fitting superstructure or overloading (2). Screw fractures inside the implant make prosthesis retention impossible until and unless the broken segment of the screw is removed and replaced from the implant. Once the abutment screw gets fractured, no universal standard kit is available for retrieval of the fractured screw from the implant. The screw retrieval systems which are available in the market are only compatible with their respective particular implant system and are expensive. This case report highlights the successful retrieval of a fractured abutment screw from the implant body using simple armamentarium available in a dental clinic.

## CASE REPORT

A 58-year-old woman from Karad (Maharashtra, India) reported to department of periodontology (School of Dental Sciences, KIMS DU, Karad, India) with a loosened crown over the implant in the mandibular right first molar region. The crown on this single implant was a screw-retained prosthesis as the access hole was filled with composite which was noticeable. The implant along with its prosthesis had been placed five years before.

The patient noted the mobility of the crown three years back and she reported this to her dentist who had placed the implant previously, but he was unsuccessful in retrieving the prosthesis. The patient reported to our clinic as she had noticed increased mobility during the previous few months. On clinical examination, we observed a mobile prosthesis which was causing discomfort to the patient. On radiographic examination, an improperly seated abutment over the implant was noted along with evidence of marginal bone loss (Fig. 1). A provisional diagnosis of mobile prosthesis associated with an ill-fitting screw was made. After contacting the previous dentist, it was confirmed that the patient had received an MIS M4 implant of 4.2 mm diameter and 11.5 mm length (MIS Implants Technologies Ltd., NJ, USA). It was planned to remove the existing crown followed by placement of a new prosthesis. An informed consent was obtained from the patient prior to the planned procedure. As per the MIS M4 implant specifications, a 1.27 mm hex driver was used to remove the screw. The hex driver did not engage into the screw head through the access hole on repeated attempts. We decided to remove the prosthetic crown by cutting it buccolingually (Fig. 2A). During removal of crown, we discovered that the prosthetic screw was fractured at the midpoint (Fig. 2B).

We attempted and failed to retrieve the fractured screw using the technique described by Manpreet et al. (2). We utilised an innovative technique to retrieve the fractured screw which involved making a groove on the occlusal surface of fractured screw across the diameter using a fine round bur no. BR 49 (Mani, Inc, Utsunomiya, Tochigi, Japan) (Fig. 3A). Utmost care was taken not to touch the internal hex geometry of the implant with the bur. An ultrasonic tip F00359 (Acteon group, Stellac, France) was then engaged and activated into the groove at both ends alternatively to loosen it by mechanically

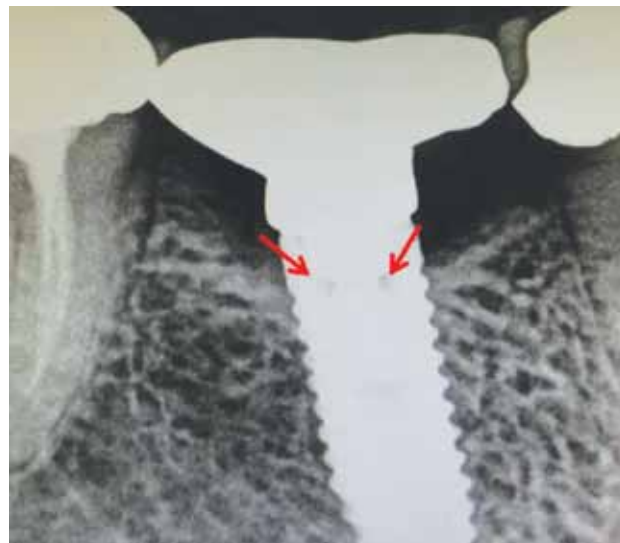

FIG. 2 Improperly seated abutment over the implant along with evidence of marginal bone loss (denoted by arrows).

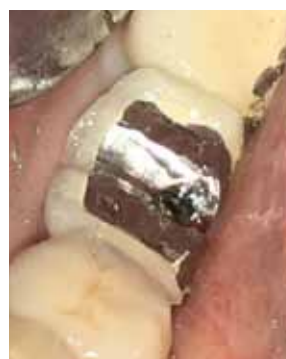

FIG. 2A

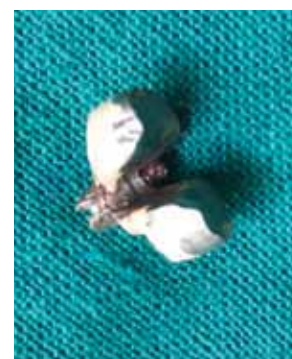

FIG. 2B

FIG. 2 (A) Removal of prosthesis with buccolingual cut. (B) Exposure of fractured prosthetic screw at midpoint.

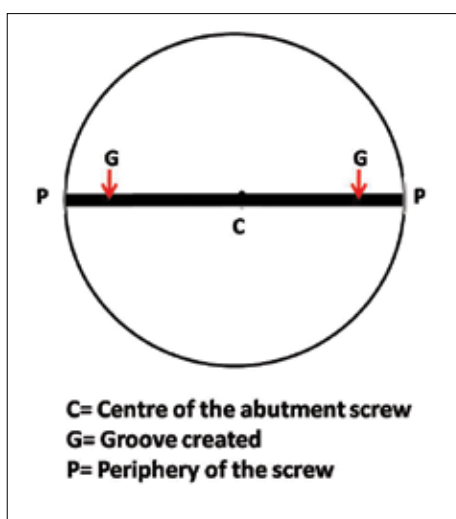


FIG. 3A




FIG. 3B

FIG. 3 Graphic representation. (A) groove created on the head of the fractured screw. (B) Ultrasonic scaler tip engaged and activated in the groove.



FIG. 4A

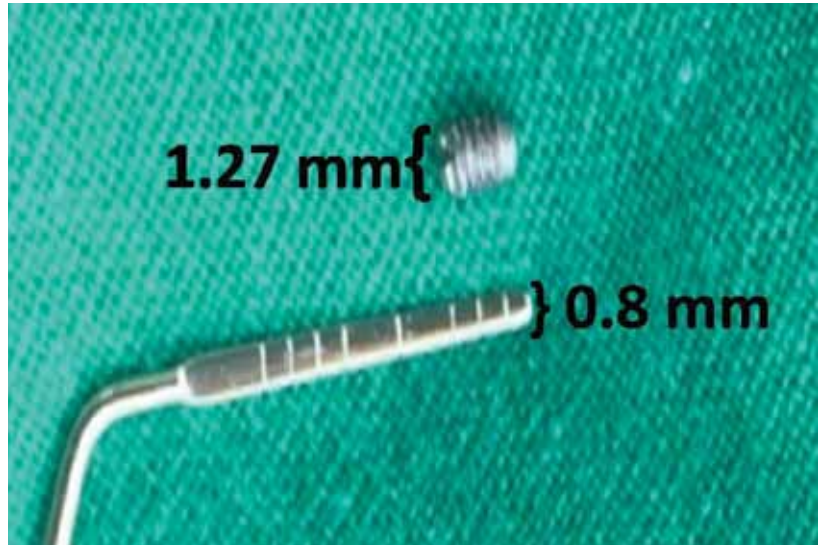


FIG. 4B

FIG. 4 (A) Graphic representation of the Goldman Fox periodontal probe engaged in the groove for screw retrieval. (B) Dimensions of the screw head and working end of the Goldman Fox probe.

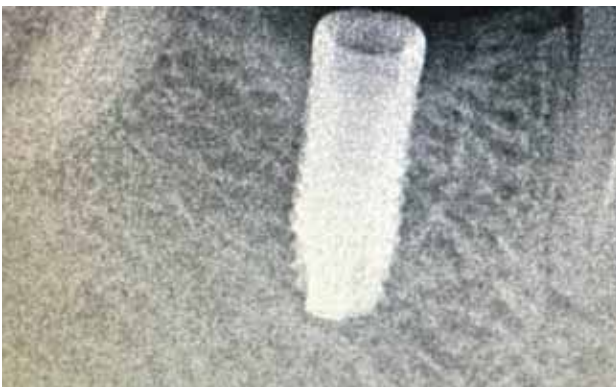

FIG. 5A

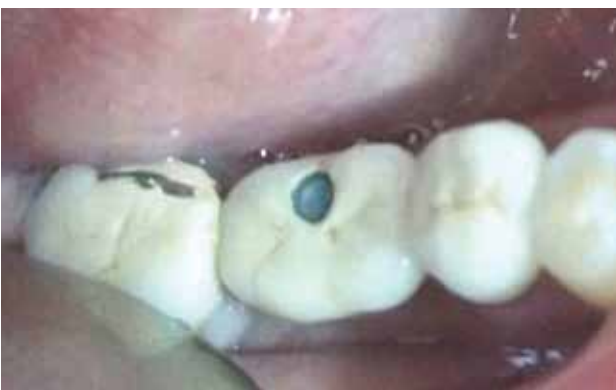

FIG. 5B

FIG. 5 (A) Complete retrieval of the broken part of the abutment screw confirmed with a radiograph. (B) Placement of new screw-retained prosthesis.

moving the tip of the scaler counter clockwise (Fig. 3B). The Goldman Fox periodontal probe (Hu-Friedy Mfg. Co., LLC) was used to engage the notch and the fractured screw was gently driven out of the implant body (Fig. 4A). After the retrieval of the broken part of the abutment screw, a radiograph was taken to confirm its complete removal (Fig. 5A). The new abutment was then tried for the fit and retention which served as an indication to confirm that we did not damage the internal retentive structure of the implant. New abutment and screw were fixed on the implant and the prosthesis was fabricated over it (Fig. 5B).

Written informed consent was obtained from the patient for publication of this case report and any accompanying images.

## DISCUSSION AND CONCLUSION

Fracture of implant components may occur due to fatigue from biomechanical overload, improper placement of implant, non-passive fit of the superstructures, and manufacturing errors (4). Most of these factors can be minimized during treatment planning by appropriate selection of size and number of implants, placing the implants at right angulations and recording the implant impression without any distortion.

The loosened screw develops mobility due to the loss of thread architecture caused by friction. If prosthetic screw loosening is not treated in time, it may lead to a screw fracture (5). Once we come across a situation of screw loosening, the screw needs to be discarded and replaced with a new one. This is critical as the fatigue

that develops in the loosened screw makes it vulnerable to fracture.

There are several techniques available for screw retrieval which include specialized kits (e.g. Abutment Screw Removal Kit by Nobel Biocare™, Yorba Linda, California, USA.; Certain®-Screw Removal Kit by Biomet 3i™, Florida, USA.) which are expensive and system specific. Many clinicians have used unconventional armamentariums for fractured screw retrieval like spoon excavator (6), cotton driver (7), ultrasonic scaler (2), etc

In unconventional technique for screw retrieval, three basic dental instruments are required. The first instrument is used to create a groove on the broken segment of the prosthetic screw. The second instrument is used to loosen the prosthetic screw and the third one is used to drive the prosthetic screw out of the implant body.

The groove can be created on the broken segment of prosthetic screw with a rotary diamond bur or diamond coated ultrasonic scaler tip. The instrument we select for creating a groove should be smaller than 1 mm as the screw head dimension is 1.2 to 1.27 mm. This is important as we should only create a groove on the screw head without damaging the internal anatomy of the implant. In the current case we used the Mani round bur BR 49 which has a diameter of 0.8 mm.

A fine ultrasonic tip F00359 (Acteon group, Stellac, France) was used to loosen the screw by engaging the created groove. The use of round bur and ultrasonic scaler tip to loosen the screw has also been previously reported by Manpreet et al (2).

Once the screw developed noticeable amount of mobility, we used the Goldman Fox probe as a screw driver (Hu-Friedy Mfg. Co., LLC) to unscrew the broken fragment out of the implant. Fractured Prosthetic screw retrieval with the help of a Goldman Fox probe has been reported for the first time through this case report. This is quite unique probe as it has the flat working end rather than round one and the dimension of this flat working end is 1 mm which is less than the smallest prosthetic screw head dimension (Fig. 4B).

Despite of all the precautions undertaken, if there is any damage to the internal anatomy of the implant, post and core like prosthesis for the implant can be considered as last resort to restore it in function (8).

Retrieval of the broken screw out of the dental implant is difficult but not an impossible task. Development of

simple, economical and feasible armamentarium that can be used universally for fractured prosthetic screw retrieval is the requirement of the hour. The described unconventional technique in the current article utilized simple armamentarium that is cost-effective and can be universally used for any implant system.

### Authors' contributions

AJ and VK devised the treatment concept and carried out the procedure. GS and SZ both wrote the manuscript and reviewed the available literature. All four authors read and approved the final manuscript.

### Funding

Nil

### Consent for publication

Consent has been obtained from the patient for the use and publication of all images.

### Competing interests

All the authors declare that they have no competing interests.

## REFERENCES

1. Reyhanian A, Parker S, Moshonov J, Fuhrman N. The use of Er:YAG in laser-assisted broken abutment screw treatment. Case report\_Er: YAG Lasers. 2010;3:6-11.
2. Walia MS, Arora S, Luthra R, Walia PK. Removal of fractured dental implant screw using a new technique: a case report. J Oral Implantol 2012;38:747-50.
3. Francis L, Zeenath H, Lylajam S, Harshakumar K. Implant screw fracture. J Dent Implant 2013;3:181-3.
4. Eckert SE, Meraw SJ, Cal E, Ow RK. Analysis of incidence and associated factors with fractured implants: a retrospective study. Int J Oral Maxillofac Implants 2000;15: 662-7.
5. Quek C E, Tan K B, Nicholls J I. Load fatigue performance of a single-tooth implant abutment system: effect of diameter. Int J Oral Maxillofac Implants 2006; 21: 929–936.
6. Barbosa JM, Ascenso J, Hirata R, Caramês J. The cotton driver: an alternative technique for removing fractured screw fragments. J Prosthetic Dent 2014 Dec 1;112(6):1601-2.
7. Ilser Turkyilmaz et al. Removal of a fractured locator abutment screw fragment. J Contemp Dent Pract 2013;14(5):968-972.
8. Harshakumar K, Bhatia S, Ravichandran R, Joy PT. Salvaging an implant with abutment screw fracture by a custom titanium post and core supported prosthesis-a novel technique. Int J Sci Study 2014;2:36-9.