

# Ectopic tooth involving the orbital floor and infraorbital nerve

➤ **D. BARBIERI<sup>1</sup>, P. CAPPARÈ<sup>2</sup>, G. GASTALDI<sup>2</sup>, M. TRIMARCHI<sup>1</sup>**

<sup>1</sup> Department of Otorhinolaryngology, IRCCS San Raffaele Scientific Institute, Milan, Italy

<sup>2</sup> Department of Dentistry, IRCCS San Raffaele Scientific Institute, Milan, Italy

## TO CITE THIS ARTICLE

Barbieri D, Capparè P, Gastaldi G, Trimarchi M. Ectopic tooth involving the orbital floor and infraorbital nerve. *J Osseointegr* 2017;9(4):323-5.

DOI 10.23805 /JO.2017.09.04.03

## ABSTRACT

**Aim** Ectopic eruption of a tooth within the dental arch is often noticed in clinical practice and is well documented in the literature, while ectopic eruption outside the dental arch (as in the maxillary sinus) is rare. Due to its rarity and lack of consensus over management, its incidence needs to be further defined. Surgical approach, with cyst enucleation, has been considered the treatment of choice. In the present study, a case of an ectopic maxillary third molar with chronic purulent maxillary sinusitis is presented. The aim of this report is to describe the extraction of an ectopic third molar carried out through a nasal endoscopic procedure.

**KEYWORDS** Dentigerous cyst; Nasal endoscopy; Sinusitis; Tooth extraction.

## INTRODUCTION

Tooth development results from a complicated multi-step interaction between the oral epithelium and underlying mesenchymal tissue. A series of complex tissue interactions result in the formation of mature teeth. Abnormal tissue interactions during tooth development may potentially result in ectopic tooth development and eruption (1).

Ectopic tooth formation may rarely occur in a non-oral area, such as the maxillary sinus, nasal septum, mandibular condyle, coronoid process, palate and chin (1, 2). Ectopic eruption may result from one of the three processes: developmental disturbance, pathological process, and iatrogenic activity (3).

Third maxillary and mandibular molars have more ectopic variation than other teeth, since developmental aspects, and developmental anomalies and/or variations are more common (4).

Odontogenic sinusitis is a well-known condition that accounts for approximately 10% to 12% of cases of maxillary sinusitis (5). An odontogenic source should be considered in patients with symptoms of maxillary sinusitis who present a history of odontogenic infection or dentoalveolar surgery or who are resistant to standard sinusitis therapy (6).

Ectopic tooth eruption in the maxillary sinus reported in the literature are usually accidentally detected during routine radiological evaluation, and are rarely coincident with maxillary chronic sinusitis (3, 7). Treatment of such cases requires removal of the ectopic tooth, usually via a Caldwell-Luc procedure (8).

In this work, the case of a third molar impacted in the orbit and removed by means of an endoscopic procedure is reported the first time in the literature.

## CASE REPORT

A 20-year-old woman came to the observation complaining of recurrent purulent rhinorrhea on the right side, lasting 15 months. Orthopantomogram revealed a high posteriorly impacted third molar in the maxilla. CT was taken to ascertain the location, extent, and access: the right third molar process appeared edentulous, associated to ectopic molar of the right orbital floor implanted at the level of the infraorbital nerve canal (Fig. 1).

The patient was submitted to functional endoscopic sinus surgery (FESS) under general anesthesia: a wide antrostomy was performed to obtain a full view of the entire maxillary sinus using 0°-30°-70° endoscopes: submucosal swelling at the level of the transition between the roof and the posterior wall of the maxillary sinus was visible (Fig. 2A). After incision of the mucosa, a bony shell (Fig. 2B, star) covering

the tooth (Fig. 2B, arrow) was detected and removed. The infraorbital nerve crossed the roots of the ectopic molar (Imagine 2C, asterisk), making it necessary to gently release the trapped nerve before extracting the tooth (Fig. 2D).

The anatomy was preserved and patient sensibility of the cheek and upper eye-lid was unaffected. The orbital floor was also untouched and there was no damage to the eye nor extraocular muscles, as confirmed by post-operative CT. It also showed how the FESS allowed for significant reduction of the sinusitis through mechanical removal of inflammatory tissue.

Postoperative recovery was uneventful. Histopathology of the specimen confirmed the diagnosis of dentigerous cyst, thus ruling out keratocystic, ameloblastic, and malignant changes.

## DISCUSSION

Third molars are often impacted or in an ectopic position, and usually associated with dentigerous cysts, which are most frequently found in the age group 20 to 40 years, rarely seen in childhood and with a frequency that decreases with age. About 70% of dentigerous cysts occur in the mandible, and 30% in the maxilla. Dentigerous cysts associated with ectopic teeth within the maxillary sinus are fairly rare: in the literature about 30 cases have been described (8), but only few cases involving the floor of the orbit (9-12). Most patients (90%) had a single dentigerous cyst in

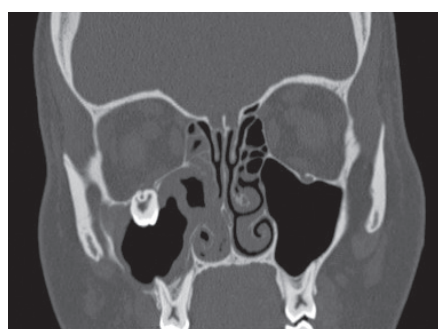
the maxillary sinus and the most frequent tooth was the maxillary third molar tooth, followed by canine, supernumerary, and premolar teeth (8).

Typically, dentigerous cysts are painless, but may cause facial swelling and delayed tooth eruption; dentigerous cysts progress slowly and may exist for many years without being noticed (8, 13). When the maxillary sinus is involved, symptoms may occur late in the process (14); when the cysts become symptomatic, the patient experiences the classic signs of sinus disease such as swelling, facial pain, headache, and nasolacrimal obstruction (8, 13).

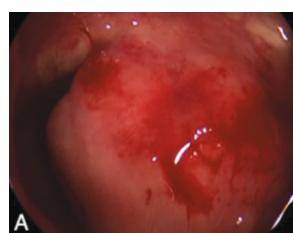
The standard treatment for a dentigerous cyst is enucleation and extraction of the cyst-associated impacted or unerupted tooth (8, 13). There are several surgical approaches in the literature for removal of a displaced root from the maxillary sinus: the alveolar approach, the Caldwell-Luc operation, and an endoscopic approach (2, 8, 15-18). The alveolar approach is based on the principle that most roots fall to the floor of the maxillary sinus or in close proximity of the socket, and thus it is possible to retrieve the root and close the fistula during the same operation. This approach, however, is not suitable for all cases, such as those with dislocated roots between the apices of the standing vital teeth or those impacting in the nasal ostium (15).

In the literature, the most common approach used for removal of dentigerous cysts is Caldwell-Luc procedure and is considered the gold-standard because of direct visualization and a good operating field (15). Nonetheless, there are many disadvantages, including facial pain, numbness from injury to the infraorbital nerve (19, 20), and anesthesia or paresthesia of the upper anterior teeth due to damage to the anterior superior alveolar nerve while bone is being removed from the canine fossa (19, 20). FESS attempts to overcome these drawbacks (19, 20).

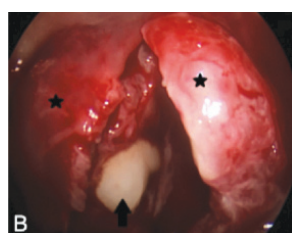
FESS enlarges the natural ostium of the maxillary sinus to reach the target and is less invasive, decreasing the risk of injury to the tooth root; further advantages include a quick recovery and little or no risk of injury to the infraorbital nerve (16, 21, 22). The potential problem of altered facial growth in children associated



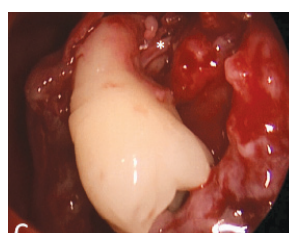
**FIG. 1** Coronal CT scan: ectopic molar of the right orbital floor implanted at the level of the infraorbital nerve canal.



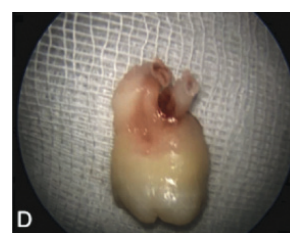**FIG. 2A**



**FIG. 2B**



**FIG. 2C**



**FIG. 2D**

**FIG. 2** Intraoperative images. **2A** Submucosal swelling of the transition between the roof and the posterior wall of the maxillary sinus. **2B** The tooth (arrow) surrounded by bony shell (stars) **2C** Infraorbital nerve (\*) crossing the roots of the ectopic molar. **2D** The extracted tooth.

with the Caldwell-Luc operation is absent with this technique (23, 24).

In the literature, there are only a few small dentigerous cysts in the maxillary sinus close to the osteomeatal complex that have been removed through endoscopic approach. Hasbini described a lesion at the level of the osteomeatal complex, Di Pasquale, Mikozgadoiglu and Taimur Saleem reported a lesion in the medial wall of the maxillary sinus without involvement of the infraorbital region (2, 16–18). No cases of dentigerous cyst at the level of infraorbital nerve removed by endoscopic approach alone have been described. In the literature, only one case of a patient with an ectopic tooth in the roof of the maxillary sinus treated through endoscopic approach alone has been reported: in this case, the patient, as he was asymptomatic, refused to have the tooth surgically removed, but did agree to intranasal antrostomy to help clear the sinus (9). Patients with a dentigerous cyst with involvement of the floor of the orbit and/or the region of the infraorbital nerve have always been treated by means of a Caldwell-Luc procedure (10–12). In 1994 Omer Kaya and Naresh Shetty, in 2012, reported two cases with a tooth in the floor of the orbit, but the documentation in terms of radiological imaging was poor because of the lack of a CT scan showing the precise relation of the tooth with the orbital floor. In contrast, in 2013 Anshul Ray reported a patient who underwent a CT scan that revealed a tooth placed superiorly to the maxillary antrum and posteroinferiorly to the floor of the orbit. Unlike the present case, all these lesions were treated with a Caldwell-Luc procedure.

In our case, the cyst was at the level of the floor of the orbit, in close contact with the infraorbital nerve. The use of 0° and angled endoscopes (30°–70°) helped us to achieve optimal magnification of the surgical field, and in particular of the course of the infraorbital nerve, allowing us to preserve the integrity of the floor of the orbit and the nerve itself.

## CONCLUSION

The present study reports the first case of ectopic tooth involving the orbital floor treated with an endoscopic procedure alone. Moreover, a nasal endoscopic procedure is very well tolerated.

## REFERENCES

- Goh YH. Ectopic eruption of maxillary molar tooth: An unusual cause of recurrent sinusitis. *Singapore Med J* 2001;42:80–1.
- Di Pasquale P, Shermetaro C. Endoscopic removal of a dentigerous cyst producing unilateral maxillary sinus opacification on computed tomography. *Ear Nose Throat J* 2006 Nov;85(11):747–8.
- Bodner L, Tovi F, Bar-Ziv J. Teeth in the maxillary sinus: Imaging and management. *J Laryngol Otol* 1997;111:820–4.
- Kayabasoglu G, Karaman M, Kaymaz R, Nacar A. A rare entity causing chronic sinusitis: ectopic tooth in maxillary sinus. *Eur J Gen Med* 2015;12(1):86–89.
- Akhlaghi F, Esmaeelinejad M, Safai P. Etiologies and treatments of odontogenic maxillary sinusitis: a systematic review. *Iran Red Crescent Med J* 2015 Dec;27:17(12).
- Mehra P, Murad H. Maxillary sinus disease of odontogenic origin. *Otolaryngol Clin North Am* 2004 Apr;37(2):347–64.
- Pracy JP, Williams HO, Montgomery PQ. Nasal teeth. *J Laryngol Otol* 1992;106:366–7.
- Xu GZ, Jiang Q, Yang C, Yu CQ, Zhang ZY. Clinicopathologic features of dentigerous cysts in the maxillary sinus. *J Craniofac Surg* 2012 May;23(3):e226–31.
- Elango S1, Palaniappan SP. Ectopic tooth in the roof of the maxillary sinus. *Ear Nose Throat J* 1991 Jun;70(6):365–6.
- Kaya O, Bocutoğlu O. A misdiagnosed giant dentigerous cyst involving the maxillary antrum and affecting the orbit. Case report. *Aust Dent J* 1994 Jun;39(3):165–7.
- Shetty YN, Majid IA, Patel RU, Shammam M. An unusual case of tooth in the floor of the orbit: the libyan experience. *Case Rep Dent* 2012;2012:954789. Epub 2012 Sep 30.
- Rai A, Rai NJ, Rai MA, Jain G. Transoral removal of ectopic maxillary third molar situated superiorly to maxillary antrum and posteroinferiorly to the floor of orbit. *Indian J Dent Res* 2013 Nov–Dec;24(6):756–8.
- Buyukkurt MC, Omezli MM, Miloglu O. Dentigerous cyst associated with an ectopic tooth in the maxillary sinus: a report of 3 cases and review of the literature. *Oral Surg Oral Med Oral Pathol Oral Radiol Endod* 2010 Jan;109(1):67–71.
- Freedland ES, Henneman PL. An unusual cause of headache: a dentigerous cyst in the maxillary sinus. *Ann Emerg Med* 1987 Oct;16(10):1174–6.
- Ong AH. Caldwell–Luc approach for surgical removal of the root from the maxillary sinus with closure of oro-antral fistula. *Annals Dent Univ Malaya* 1997;4:49–51.
- Hasbini AS, Hadi U, Ghafari J. Endoscopic removal of an ectopic third molar obstructing the osteomeatal complex. *Ear Nose Throat J* 2001;80(9):667–70.
- Micozkadioglu SD1, Erkan AN. Endoscopic removal of a maxillary dentigerous cyst. *B-ENT* 2007;3(4):213–6.
- Saleem T, Khalid U, Hameed A, Ghaffar S. Supernumerary, ectopic tooth in the maxillary antrum presenting with recurrent haemoptysis. *Head Face Med* 2010 Nov 11;6:26.
- Ankit P, Meyers AD. Introduction to functional endoscopic sinus surgery. Medscape reference 2012.
- Slack R, Bates G. Functional endoscopic sinus surgery. *Am Fam Physician* 1998 Sep 1;58(3):707–18.
- Costa F, Robiony M, Toro C, Sembronio S, Politi M. Endoscopically assisted procedure for removal of a foreign body from the maxillary sinus and contemporary endodontic surgical treatment of the tooth. *Head Face Med* 2006;2:37.
- Friedrich J, Rittenberg BN. Endoscopically assisted Caldwell-Luc procedure for removal of a foreign body from the maxillary sinus. *J Can Dent Assoc* 2005;71(3):200–1.
- Wolf G, Anderhuber W, Kuhn F. Development of the paranasal sinus in children. Implications of paranasal sinus surgery. *Ann Otol Rhinol Laryngol* 1993;102(9):705–11.
- Mair EA, Bolger WE, Breisch EA. Sinus and facial growth after paediatric endoscopic sinus surgery. *Arch Otolaryngol Head Neck Surg* 1995;121(5):547–2.