

Early implant placement: 3D radiographic study on the fate of buccal wall

> **A. LANZA¹⁻², F. SCOGNAMIGLIO¹, G. DE MARCO¹, F. DI FRANCESCO¹, F. FEMIANO¹⁻³, M. LANZA⁴, A. ITRO⁵**

¹ DD-Multidisciplinary Department of Medical, Surgical and Dental Sciences, Campania University "Luigi Vanvitelli", Naples, Italy

² Associate Professor, Chair of Prosthodontic and Implant Disciplines, Campania University "Luigi Vanvitelli", Naples, Italy

³ Associate Professor, Chair of Dental Materials, Campania University "Luigi Vanvitelli", Naples, Italy

⁴ MD-Multidisciplinary Department of Medical, Surgical and Dental Sciences, Campania University "Luigi Vanvitelli", Naples, Italy

⁵ Professor and Director of Multidisciplinary Department of Medical, Surgical and Dental Sciences, Campania University "Luigi Vanvitelli", Naples, Italy

TO CITE THIS ARTICLE

Lanza A, Scognamiglio F, De Marco G, Di Francesco F, Femiano F, Lanza M, Itro A. Early implant placement: 3D radiographic study on the fate of buccal wall. *J Osseointegr* 2017;9(3):276-281.

DOI 10.23805 /JO.2017.09.03.02

KEYWORDS Bone regeneration; Computed Tomography; Early implant; Post-extraction socket; Xenograft.

ABSTRACT

Aim Tooth extraction results in a reduction of bone quantity. The scientific literature shows that post-extraction implants do not modify the pattern of bone remodeling secondary to dental extraction. The use of contextual bone regeneration techniques has proven effective in preventing or reducing this bone resorption. The purpose of this case report is to assess the maintenance of the buccal bone volume around an early implant through an analysis with TC dental scan one year after the delivery of the prosthesis.

Case report A 40 years old man with periodontitis came under our observation. After periodontal treatment careful extraction in the premolar area was performed and after 4 weeks an implant was inserted as well as a simultaneous bone grafting was performed with collagen membrane to reduce post-extraction socket-shrinking. After osseointegration period (4 months) the implant was loaded and the clinical and radiographic follow-up is presented. A computed tomography (TC) analysis before and one year from loading was also made to show the preservation of hard tissues and the integrity of the buccal bone plate.

Conclusion The use of bone regeneration around immediate implants can help to obtain good functional and esthetic outcomes. 3D radiographic study demonstrates that the buccal bone can be preserved one year after loading.

INTRODUCTION

After tooth extraction there is a reduction of bone volume(1-3). According a recent review of the literature mean horizontal and vertical bone resorption is 3.79 mm and 1.24 mm respectively after 6 months of healing in humans (4). This bone shrinkage is greater on the buccal side and two thirds of this reduction occur in the first 3 months of healing (5). It is now believed that this process of resorption is the result of the interruption of blood supply to part of the vascular plexus in the periodontal lamina dura delimiting the socket which, as noted, has a stronger presence in the buccal bone (6). Implant positioning immediately after tooth extraction does not counteract this physiological phenomena (1). Sanz et al. in a randomized controlled clinical trial showed that implant placement into extraction sockets will result in significant bone reduction of the alveolar ridge (7).

Studies show that the integrity and thickness of the vestibular cortical plate (8-9) positively influence the outcome of postextraction implants.

In a clinical trial, mean vertical bone resorption of approximately 1 mm of the buccal bone was reported 4 months after immediate implant placement. This osseous shrinkage was more marked when buccal bone was thinner (1.2 ± 2.1 mm) (10).

In order to counteract these changes in the post-

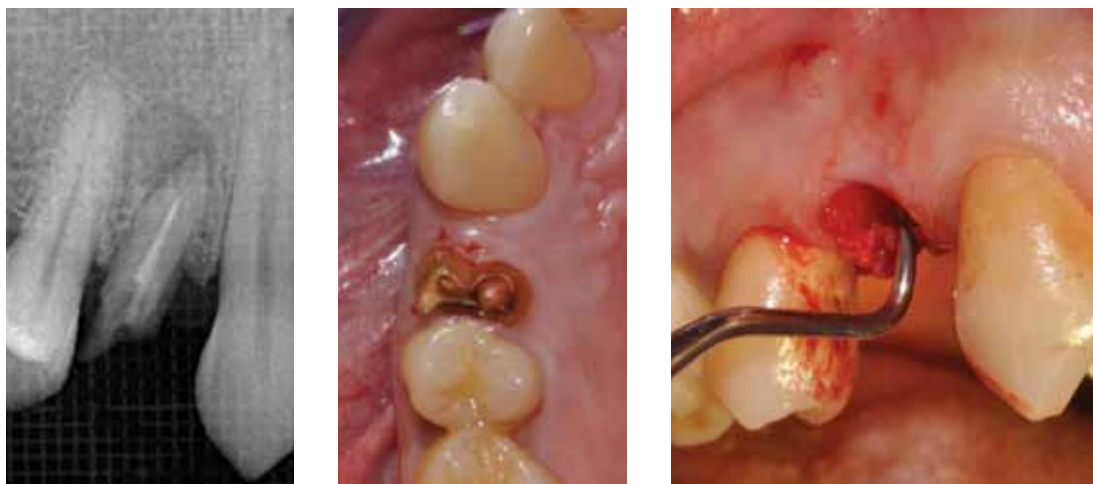


FIG. 1 Initial clinical situation: a) Periapical radiograph; b) Occlusal view; c) Lateral view after extraction.

extraction site and preserve tissue volumes, bone regeneration techniques are used at the time of implant placement (11-14).

Many studies have evaluated the placement of different grafting materials with or without membranes to fill the marginal defects or fenestration of bone tissue that often occur after the placement of implants into fresh extraction sockets. Caneva et al. evaluated (15) the use of a resorbable collagen membrane over immediate implants in dogs. The amount of bone resorption was smaller in the test sites with membrane compared with control sites without it (1.7 vs 2.2 mm).

Araujo e Lindhe (16) showed that the use of xenografts in the buccal gap between immediate implants and buccal and lingual bone plates reduced horizontal and vertical bone loss compared with non grafted controls. Similar results were reported by Barone et al. (17) in another study using cancellous bone and collagen membrane in a submerged healing environment. However, while adequate osseointegration is achieved with or without bone regeneration, no evidence was available to support the superiority of one technique or biomaterial over another (18).

Some literature reviews show that the use of bone substitutes and collagen membranes are useful in the preservation of the buccal wall in the presence of bone defects such as dehiscence and fenestrations (19-20).

In the present article a case is reported of early implant placement and simultaneous bone regeneration 4 weeks after extraction. The step-by-step surgical procedure is described and the clinical and radiographic outcome at 1 year follow-up is presented.

The aim of the 3D radiographic study reported is to demonstrate that the use of Deproteinized Bovine Bone Mineral (DBBM) and collagen membrane in early implants can be effective in limiting ridge alterations in post-extraction sites and contribute to the preservation of the alveolar process also in presence of marginal bone defect and fenestration.

CASE REPORT

Diagnosis and treatment planning

The patient came under our observation with an infected root in premolar area (Fig. 1).

After careful clinical and radiographic examination the fixed prosthetic treatment options were:

- Extraction of #14 and abutment preparation of #13 and #15 to run a bridge of three teeth;
- Extraction of #14 and Type 2 implant placement (after 4 week) with simultaneous GBR with the possibility of reducing surgeries.

The possibility not to sacrifice structurally sound teeth convinced both clinicians and patient to the second therapeutic choice.

Initial periodontal therapy was followed by re-evaluation at 4 weeks, cast model analysis and the prescription of a CT dental scan for the analysis of the maxillary bone volume available at post-extraction site.

CT analysis showed adequate bone volume compatible with type 1 or 2 implant placement (Fig. 2C). Sagittal scans show the fenestration of the buccal bone plate. The patient also did not show contraindication to surgery from a systemic point of view.

Surgical procedure

The root was atraumatically extracted in order to preserve the thin vestibular cortical (Fig. 1). As literature suggests, the presence of suppuration and a fenestration of the buccal bone plate encourages to perform a type 2 implant surgery protocol (1).

Extraction and implant surgery was performed under local anesthesia using 4% articaine solution combined with a vasoconstrictor (Ubistesin forte, 3M ESPE). A full-thickness flap was raised using a crestal incision with extensions through the sulcus of both adjacent teeth. The buccal bone was present but very thin. Following careful debridement of the socket and of the buccal fenestration defect, implant bed preparation started

with spear-shaped bur and spiral drills of increasing diameter.

The implant, a cylindrical 3.5/11mm (OsseoSpeed™ Astra Tech AB, Mölndal, Sweden), was placed in a correct three-dimensional position within the so-called comfort zones, mesio-distally, orofacially and coronopically

(21) (Fig. 3).

Implant primary stability was achieved anchoring the fixture apically in native bone and more palatally.

A residual fenestration defect was present on the buccal plate and was filled with granules of deproteinized bovine bone mineral (DBBM; Bio-Oss, Geistlich

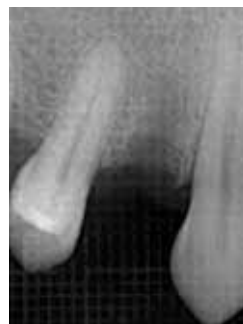
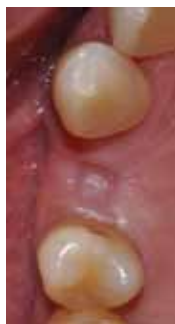
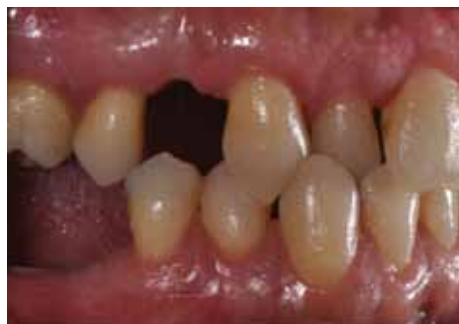FIG.2 Clinical and radiographic control after 4 weeks from extraction and before implant surgery: a-b) Clinical occlusal and lateral view; c) Periapical radiograph; d) CT dental scan. Note the buccal bone fenestration (arrow).

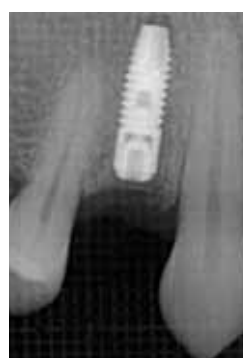
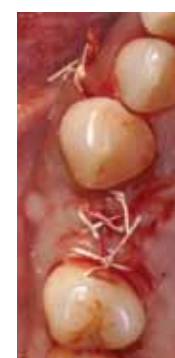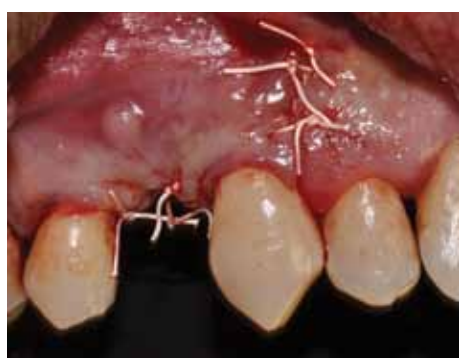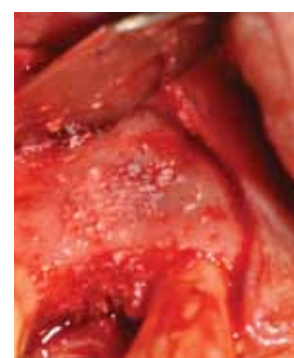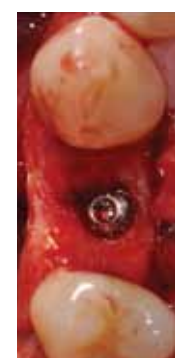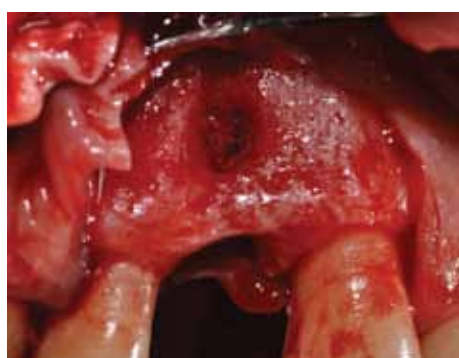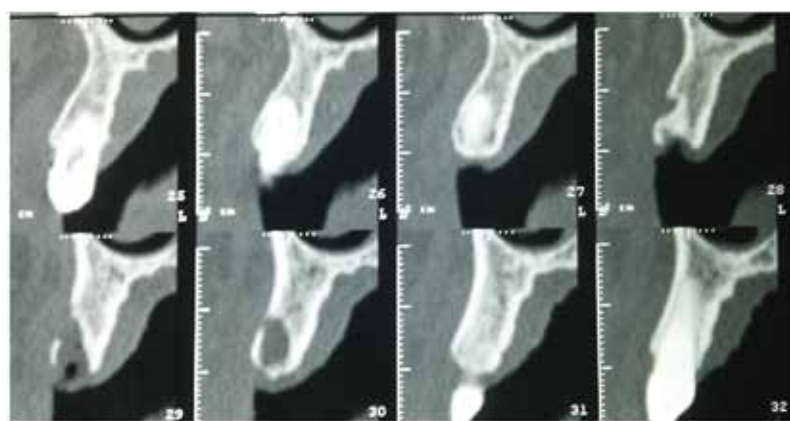


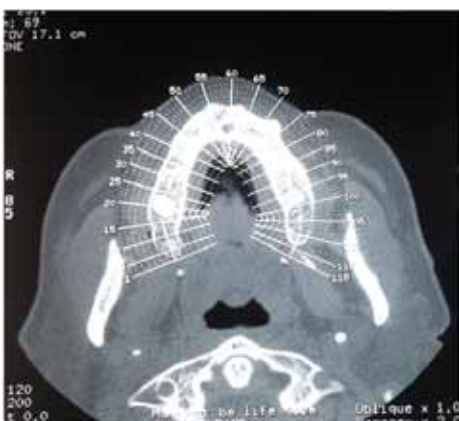FIG.3 Implant surgery: a) Aspect of the buccal fenestration after implant placement; b) Occlusal view; c) The fenestration is filled with xenograft and a collagen membrane is placed to cover the defect and the xenograft; d-e) The flaps sutured with e-PTFE suture; f) Periapical radiographic after implant placement and bone regeneration.

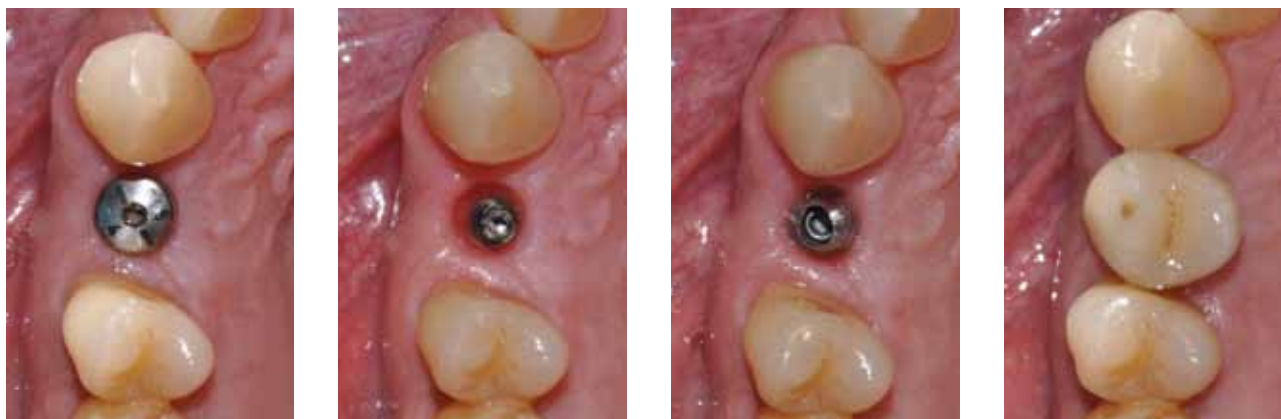


FIG. 4 Prosthetic phase: a) Clinical aspect after 1 week from second stage surgery; b) Soft tissue healing after osseointegration period; c) Individualized abutment; d) Clinical aspect after the delivery of the porcelain fused to metal crown.

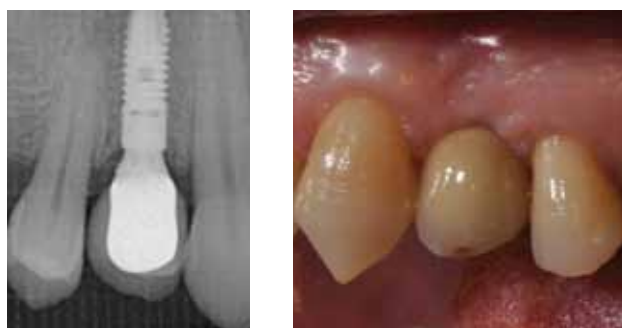

FIG. 5 Clinical control at one year of follow-up: a) Radiographic control; b) Clinical aspect. No bone loss was observed after the observation period of one year. The interdental papillae appeared to fill the embrasure spaces

Biomaterials) of small particle size. Bone grafting was performed exclusively outside because bone to implant distance outside was ≤ 2 mm as recommended by a clinical study (22). Xenograft was then covered with a collagen membrane (Bio-Gide, Geistlich Biomaterials) (Fig. 3 B-C). The flaps were sutured with e-PTFE material (Figure 3D). Figure 3E shows periapical radiographic control after early implant placement.

Antibiotic prophylaxis was prescribed with amoxicillin and clavulanic acid 1 day before and 4 days after surgery. In addition, for plaque control, the patient rinsed with 0.2% chlorhexidine digluconate 3 times a day for two weeks and performed a roll-stroke brushing technique avoiding, in the early days of healing, the surgical site. Clinical checks were carried out after 7 days, when the suture was removed, and at 14, 21 and 28 days; when a complete epithelial closure was achieved, controls were performed on a monthly basis till the prosthetic stage.

Prosthetic stage

Healing occurred uneventfully at four months, when a good maintenance of peri-implant tissue volumes was observed and impressions were taken (Fig. 4). A high

quality polyether precision material was used (Impregum Penta Duosoft, 3M ESPE).

After soft tissue conditioning, the final restoration was delivered after 4 weeks (Fig. 4).

RESULTS

One year after delivery of the prosthesis, it is possible to observe a good soft tissues healing with closure of the proximal part of the gingival papillae (Fig. 5B). No signs of complication such as peri-implant infection or mucosal recession was observed. The periapical radiograph showed stable bone crest levels/peri-implant hard tissue (Fig. 5A-B). The CT scans show the integrity and the maintenance of the buccal bone also after the prosthetic loading (Fig. 6).

DISCUSSION

The need to reduce the treatment times and the number of surgeries in implantology has led operators to seek new therapeutic protocols. The use of post-extraction implants is now a common situation in everyday clinical practice (23-26).

When choosing an immediate and early implant, some factors must be considered to increase the predictability of treatment (10). Among these, the available bone volume and buccal wall thickness, periodontal biotype, the site of the extraction and the correct three-dimensional positioning of the implant (27).

In this specific case we opted for a type 2 implant placement because a buccal fistula and suppuration in implant site were present.

At a recent consensus workshop (1), three different protocols were defined: type 1 or immediate when the implant are placed in the same surgical intervention as the dental extraction; type 2 or early implant placement

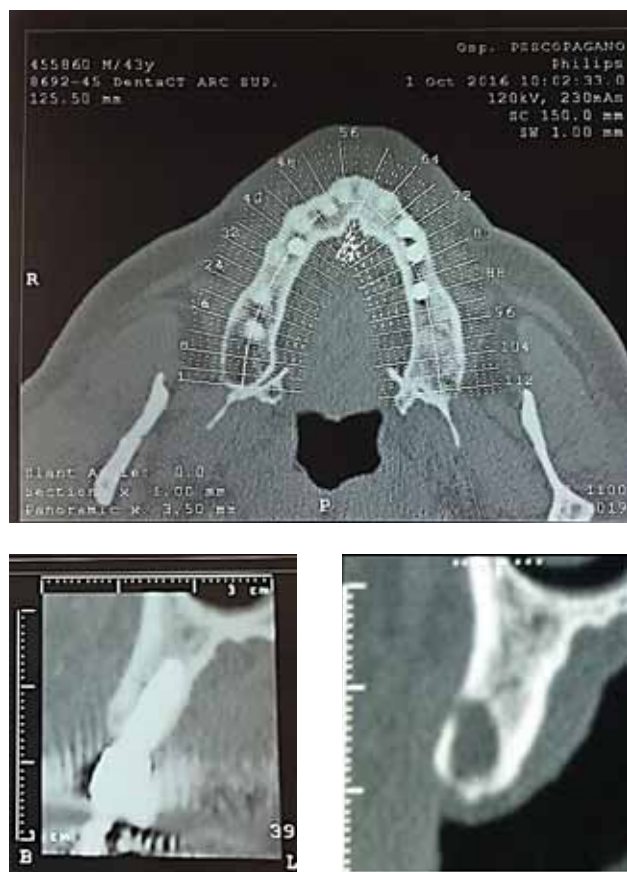


FIG.6 3D radiographic control with CT analysis at one year of follow-up: a) Sagittal scans show the integrity and the healing of the buccal bone after bone regeneration if compared with the initial radiographic condition (b).

when implants are placed in the early stages of healing (from 4 to 8 weeks); and type 3 or delayed implant placement when implants are placed when the ridge has healed (from 3 to 6 months).

The presence of active infection is probably the only contraindication to immediate implant placement (type 1) as described in the literature (1, 20).

The early implant placement protocol used in this case is particularly suitable for augmentation techniques, as the soft tissue healing after tooth extraction has occurred and there is usually enough soft tissue coverage allowing for primary healing without the need of advancing the flaps. This protocol therefore has been advocated whenever there is a need for bone augmentation, either because there are defects in one or more of the socket walls or to close the gap between the implant surface and the socket bone walls in case of wide discrepancies (8, 9). In these situations, different bone regenerative techniques have been utilized such as autologous bone grafts (28, 29), bone substitutes (30, 31) or guided bone regeneration (GBR) with resorbable and non resorbable barriers (13, 14, 32).

The use of a xenograft and a resorbable barrier membrane for this case enabled to preserve the bone

volume and heal the fistula created by the infection on the extracted tooth.

It was possible to appreciate the bone regeneration and healing of buccal defect after 12 months from delivery of the prosthesis through a clinical and radiographic analysis using CT dental scan, as shown in figures 6A and 6B.

The radiographic examination 1 year after the delivery of the prosthesis demonstrates the absence of peri-implant bone loss (Fig. 5A, 6A).

CONCLUSION

The respect of some principles such as correct 3D implant position, preservation of soft and hard post-extraction tissues and adequate prosthetic treatment can lead to good functional and esthetic outcomes of implant supported rehabilitations. The 3D radiographic analysis demonstrated it is possible to keep the cortical bone using regenerative techniques around early implants. However, this case report may not be useful to draw final conclusions about the predictability of the treatment but only to present the clinical procedure and its biological rationale.

Conflict of interests

The authors declare that "no potential conflict of interest relevant to this article was reported".

REFERENCES

1. Hammerle CH, Chen ST, Wilson TG Jr. Consensus statements and recommended clinical procedures regarding the placement of implants in extraction sockets. *Int J Oral Maxillofac Implants.* 2004; 19(Suppl.):26-28
2. Araujo MG, Araujo M.G. & Lindhe, J. Dimensional ridge alterations following tooth extraction. An experimental study in the dog. *Journal of Clinical Periodontology* 2005; 32: 212-218.
3. Vignoletti F, Discepoli N, Muller A, de Sanctis M, Munoz F, Sanz M. Bone modelling at fresh extraction sockets: immediate implant placement versus spontaneous healing: an experimental study in the beagle dog. *J Clin Periodontol* 2012; 39: 91-97
4. Tan WL, Wong TLT, Wong MCM, Lang NP. A systematic review of post-extraction alveolar hard and soft tissue dimensional changes in humans. *Clin. Oral. Impl. Res.* 2012; 23 (suppl 5): 1-21.
5. Schropp, L., Wenzel, A., Kostopoulos, L. & Karring T. Bone Healing and Soft Tissue Contour Changes Following Single-Tooth Extraction: A Clinical and Radiographic 12-Month Prospective Study. *Int J Periodontics Restorative Dent.* 2003; 23: 313-323.
6. Araujo MG, Sukekava F, Wennstrom JL, Lindhe J. Ridge alteration following implant placement in fresh extraction sockets. *J Clin Periodontol* 2005; 32: 645-652.
7. Sanz M, Cecchinato D, Ferrus J, Pjetursson EB, Lang NP, Jan L. A prospective, randomized-controlled clinical trial to evaluate bone preservation using implants with different geometry placed into extraction sockets in the maxilla. *Clin. Oral Impl. Res.* 21, 2010; 13-21.
8. Buser, D., Chen, S.T., Weber, H.P. & Belser, U.C. Early implant placement following single tooth extraction in the esthetic zone: biologic rationale and surgical procedures. *The International Journal of Periodontics & Restorative Dentistry.* 2008b; 28: 441-451.
9. Buser D, Martin W, Belser UC. Optimizing esthetics for implant restorations in the anterior maxilla: anatomic and surgical considerations. *Int J Oral Maxillofac Implants.* 2004; 19: 43-61.

10. Ferrus J, Cecchinato D, Pjetursson EB, Lang NP, Sanz M, Lindhe J. Factors influencing ridge alterations following immediate implant placement into extraction sockets. *Clin. Oral Impl. Res.* 2010; 21:22–29.
11. Gelb DA. Immediate implant surgery: three-year retrospective evaluation of 50 consecutive cases. *Int J Oral Maxillofac Implants.* 1993; 8: 388-399.
12. Becker W, Dahlin C, Lekholm U, Bergstrom C, van Steenberghe D, Higuchi K, Becker BE. Five-year evaluation of implants placed at extraction and with dehiscences and fenestration defects augmented with e-Ptfe membranes: result from a prospective multicenter study. *Clin Implant Dent Relat Res.* 1999;1(1):27-32.
13. Buser, D., Halbritter, S., Hart, C., Bornstein, M.M., Grutter, L., Chappuis, V. & Belser, U.C. Early implant placement with simultaneous guided bone regeneration following single-tooth extraction in the esthetic zone: 12-month results of a prospective study with 20consecutive patients. *Journal of Periodontology.* 2009; 80: 152–162
14. Chen, S.T., Wilson, T.G., Jr & Hammerle, C.H. (2004) Immediate or early placement of implants following tooth extraction: review of biologic basis, clinical procedures, and outcomes. *The International Journal of Oral & Maxillofacial Implants* 19: 12–25.
15. Caneva M, Botticelli D, Salata LA, Scombatti Souza SL, Carvalho Cardoso L, Lang NP. Collagen membranes at immediate implants: a histomorphometrics study in dogs. *Clin Oral Implants Res* 2010; 21: 891-897.
16. Araujo MG, Linder E., Lindhe J. Bio-Oss Collagen in the buccal gap at immediate implants : a 6-month study in the dog . *Clin Oral Impl Res* 2011; 22: 9-13
17. Barone A, Ricci M, Calvo-Guirado JL, Covani U. Bone remodeling after regenerative procedures around implants placed in fresh extraction sockets: an experimental study in beagle dogs. *Clin Oral Implants Res* 2011; 22: 1131-1137.
18. Vignoletti f, Sanz M. Immediate implants at fresh extraction sockets: from myth to reality. *Periodontology* 2000 2014; 66 : 132–152.
19. Chiapasco M, Zaniboni M. Clinical outcomes of GBR procedures to correct peri-implant dehiscences and fenestrations: a systematic review. *Clin. Oral Impl. Res.* 20 (Suppl. 4), 2009; 113–123
20. Sanz , Garcia-Gargallo M, Herrera D, Martin C, Figuero E, Sanz M. Surgical protocols for early implant placement in post-extraction sockets: a systematic review. *Clin Oral Implants Res.* 2012 Feb;23 Suppl 5:67-79.
21. Chen ST, Buser D. Clinical and esthetic outcomes of implants placed in postextraction sites. *Int J Oral Maxillofac Implants.* 2009;24 suppl: 186-217
22. Botticelli D, Berglundh T, Lindhe J: Hard-tissue alterations following immediate implant placement in extraction sites. *J Clin Periodontol.* 2004; 31: 820–828.
23. Gelb DA. Immediate implant surgery: three-year retrospective evaluation of 50 consecutive cases. *Int J Oral Maxillofac Implants.* 1993; 8: 388-399.
24. Becker W, Dahlin C, Lekholm U, Bergstrom C, van Steenberghe D, Higuchi K, Becker BE. Five-year evaluation of implants placed at extraction and with dehiscences and fenestration defects augmented with e-Ptfe membranes: result from a prospective multicenter study. *Clin Implant Dent Relat Res.* 1999;1(1):27-32.
25. Cooper LF, Reside GJ, Raes F, Garriga JS, Tarrida LG, Wiltfang J, Kern M, De Bruyn H. Immediate provisionalization of dental implants placed in healed alveolar ridges and extractionsockets: a 5-year prospective evaluation. *Int J Oral Maxillofac Implants.* 2014 May-Jun;29(3):709-17.
26. Kois JC. Predictable single tooth peri-implant esthetics: Five diagnostic keys. *Compend Contin Educ Dent.* 2001; 22: 199-206
27. Garber DA, Belser UC. Restoration-driven implant placement with restoration-generated site development. *Compend Contin Educ Dent.* 1995.16(8):796-804.
28. Ross, S.E., Crossetti, H.W., Gargiulo, A.W. & Ledakis, J.S. (1989) The use of the ross implant in an immediate extraction site. *CDS Review* 82: 64–68.
29. Becker, W., Becker, B.E. & Caffesse, R. (1994) A comparison of demineralized freeze-dried bone and autologous bone to induce bone formation in human extraction sockets. *Journal of Periodontology* 65: 1128–1133.
30. Block, M.S. & Kent, J.N. (1991) Placement of endosseous implants into tooth extraction sites. *The International Journal of Oral and Maxillofacial Surgery* 49: 1269–1276.
31. Yukna, R.A. (1991) Clinical comparison of hydroxyapatite-coated titanium dental implants placed in fresh extraction sockets and healed sites. *Journal of Periodontology* 62: 468–472.
32. Rosenquist, B. & Ahmed, M. (2000) The immediate replacement of teeth by dental implants using homologous bone membranes to seal the sockets: clinical and radiographic findings. *Clinical Oral Research* 11: 572–582.