

> MANUELA RAPANI¹, VITTORIA PERROTTI¹, CARMINE RAPANI², FLAVIA IACULLI¹, GIOVANNA IEZZI¹

¹Department of Medical, Oral and Biotechnological Sciences, University of Chieti-Pescara, Chieti, Italy

²Private Practice, Chieti, Italy

Implant insertion in a patient with Albers-Schonberg's disease: case report and literature review

TO CITE THIS ARTICLE

Rapani M, Perrotti V, Rapani C, Iaculli F, Iezzi G. Implant insertion in a patient with Albers-Schonberg's disease: case report and literature review. *J Osseointegr* 2013;1(6):13-16.

ABSTRACT

Background The aim of the present report was to present the clinical, radiological and histological outcomes of a case of implant placement in the upper jaw of a patient affected by osteopetrosis.

Case report In a 68 years old patient, 2 implants were placed in a portion of bone with areas with high density bone. Histological evaluation confirmed the radiological diagnosis of osteopetrosis. Implants were loaded 8 months after their placement. No complications or adverse reactions were observed after a 24-month follow up.

Conclusion Within the limitations of the present report, it can be concluded that a successful implant rehabilitation can be done in patients affected by osteopetrosis. Further studies, on a larger sample size, are needed to confirm this result.

KEYWORDS Histology; Implant rehabilitation; Implant success; Osteopetrosis.

INTRODUCTION

Osteopetrosis (Marble bone disease, Marmor Knochenkrankheit, Albers-Schonberg's disease) is a skeletal dystrophy of unknown origin (1). It is a rare, inherited, bone disorder, characterized by generalised, diffuse pronounced osteosclerosis with great brittleness of the bone tissue, frequent spontaneous fractures and obliteration of the marrow cavities and calcified cartilage, hence the name of osteosclerosis fragilis generalisata (1). Osteopetrosis was first described in 1904 by Albers-Schonberg, a German radiologist (2). Owing to the retardation, or partial or total failure of the resorption and formation of the

new bone, the marrow cavity develops defectively (1, 2). The condition is often congenital, with a strong familiar tendency (3-5). Several types may be distinguished: a malignant form, which affects children and is characterized by profound anaemia, and a one more benign one which is often not detected until much later in life (3-5). The malignant form, which is potentially lethal, is autosomal recessive, whilst the more benign is autosomal dominant (3-5). Most children with congenital osteopetrosis die within the first few years of life for infection, bleeding, or both (5). The autosomal dominant form is compatible with a normal life span, although fractures often result from minimal trauma, due to the brittleness of bone (5). Osteomyelitis is common in patients with osteopetrosis because of a reduced resistance to infection, attributed to the lack of marrow vascularity and impairment of white cell function (6). In adults with osteopetrosis, most of the increased radiographic density is due to true osteosclerosis and not to retained calcified cartilage (7). Bone remodelling in adulthood probably removes some residual calcified cartilage that was formed during the enchondral ossification of growth, but new bone is deposited on the primary not resorbed tissue, so that most of the actual tissue that cause the radio-density in the adult is calcified bone (4).

During the management of jaw and dental problems, special attention should be paid to patients with osteopetrosis due to the brittleness of their bone, resulting from defects in osteoclast function and consequent impaired wound healing (6). In implant rehabilitation, where the establishment of a long-term stable dental-implant interface is a crucial clinical issue, clinician should be aware of patients with the disease because of its effect on osteoclast function, which results in impaired wound healing.

To our best knowledge, in the literature there are only very few studies presenting cases of implant rehabilitation in osteopetrotic patients (10, 11). Clinical studies suggested that there is a higher risk of implant failure in sites with compromised cortical bone (thin, porous etc.) and with minimal existing trabecular bone (characterised as type IV bone) (10, 11).

The aim of the present report was to describe clinical, radiological and histological results of a case of implants placement in a patient affected by osteopetrosis.

CASE REPORT

A 68 years old Caucasian man presented to a private practice in Chieti, Italy with the need of prosthetic rehabilitation. The patient didn't smoke, had a negative past medical history for chronic diseases, or chronic systemic alterations and had not taken any medication during the last 6 months. He was informed of all the possible treatment choices for tooth replacement, and, after having decided for a fixed implant supported prosthesis, an informed consent form was signed.

The patient underwent a radiological investigation based on panoramic (OPT) and periapical x-rays before implant placement (Fig. 1); after the surgery (1 month later) (Fig. 2) and 12-month after implant loading. More than 20 mm of residual bone were present, and therefore the implant did not encroach on anatomic structures and had enough bone to guarantee primary implant stability. Before implant placement, an OPT examination and a CBCT (Cone Beam Computed Tomography) showed a uniformly dense and highly radio-opaque bone in 2.4 position, where it could be observed a missing tooth. The radiological diagnosis was "localized osteopetrosis". Good dental hygiene was recorded and a consultancy with a dental hygienist was performed. A total of 2 implants (Leader-Novaxa, Milan, Italia) were placed in the maxilla in 2.4 and 2.5 positions, where the high density area was detected. A biopsy in the same area, at the time of implant placement, was performed to confirm the diagnosis.

Surgical Procedures

The patient was treated with Amoxicilline and Clavulanic Acid (Augmentin, SmithKline Beecham, Philadelphia, PA) (2 g 1 hour before the surgery and 1 g every 12 hours for 6 days). In addition, the patient used before surgery a chlorhexidine mouthwash 0.2% (Corsodyl, GlaxoSmithKline, Verona, Italy). The surgical technique was performed by an experienced surgeon (C.R.) under local anesthesia with Articaine® infiltration (Ubistesin 4% - Espe Dental AG, Seefeld, Germany) with adrenaline 1:100.000.

After a cutting ridge and bilateral oblique releasing incisions (trapezoidal flap design), a delimited surgical area was exposed by full-thickness muco periosteal flap elevation. The implants were inserted according to the manufacturer protocol. Sutures were removed after 10 days.

The healing screw was inserted after 8 months from the implant placement. The final impression was made

15 days after the implant exposure and implants were loaded after one month.

Histological processing

The biopsy specimen was retrieved with a bone cutter hand-piece. The specimen was immediately fixed in 10% buffered formalin and processed to obtain thin ground sections with the Precise 1 Automated System (Assing, Rome, Italy) (13).

The specimen was dehydrated in an ascending series of alcohol rinses and embedded in a glycolmethacrylate resin (Techonovit 7200 VLC; Kulzer, Wehrheim, Germany). After polymerization, the specimen was sectioned along its longitudinal axis with a high-precision diamond disc at about 150 µm and ground down to about 30 µm with a specially designed grinding machine. The slides were stained with acid fuchsin and toluidine blue. The slides were observed in normal transmitted light under a Leitz Laborlux microscope (Laborlux S, Leitz, Wetzlar, Germany). The histomorphometry was performed using a light microscope (Laborlux S, Leitz) connected to a high-resolution video camera (3CCD JVC KYF55B), and interfaced to a monitor and personal computer (Intel Pentium III 1200 MMX). This optical system was associated with a digitizing pad (Matrix Vision GmbH) and a histometry software package with image capturing capabilities (Image-Pro Plus 4.5; Media Cybernetics Inc., Immagini & Computer Snc, Milano, Italy).

Implant Success Criteria

The success criteria for this study were chosen according to Albrektsson et al. (12) and included the following: the absence of persistent subjective complaints, such as pain, a foreign body sensation, and/or dysesthesia; absence of peri-implant infection with suppuration; absence of mobility; absence of a continuous radiolucency around the implant; and marginal bone reabsorption <1.5 mm in the first year of function and <0.2 mm annually in the following years.

Clinical evaluation

The biopsy area took 6 months to be completely covered by soft tissues, and from the x-ray it was possible to observe the presence of bone tissue in the examined site. The postoperative healing was uneventful, no adverse situations occurred after a 24-month (since the implant placement) healing period and no implants were lost (Fig. 3). After 24 months of functional loading, no pain, sensitivity and mobility was observed in all implants. The values of marginal bone resorption were within the Albrektsson et al. (12) criteria for implant success; thus, the cumulative survival and success rates after 24-month follow-up were 100%.

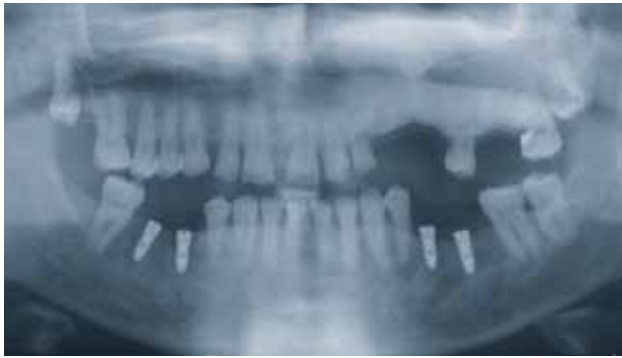

FIG. 1 Orthopantomography before implant placement showing high density bone in 2.4 area.

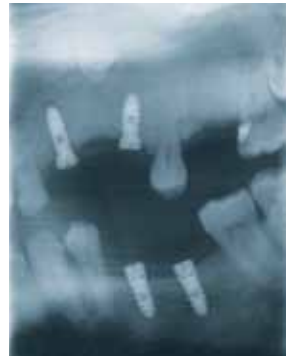

FIG. 2 X ray after implant placement in area 2.3 and 2.4.

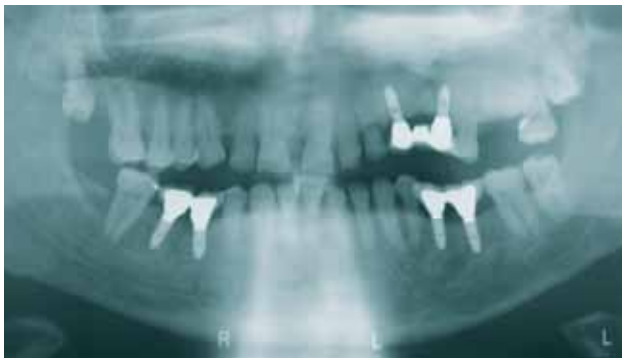

FIG. 3 Orthopantomography showing no complications after a 24-month healing period.

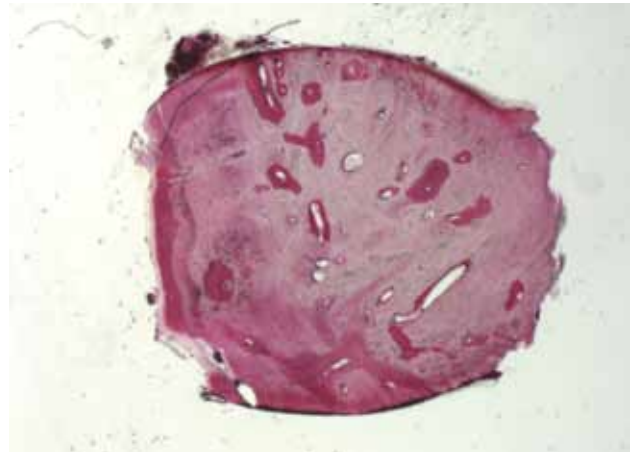


FIG. 4 Very compact bone, with very few small marrow spaces can be observed. Toluidine blue acid fuchsin. 12X.

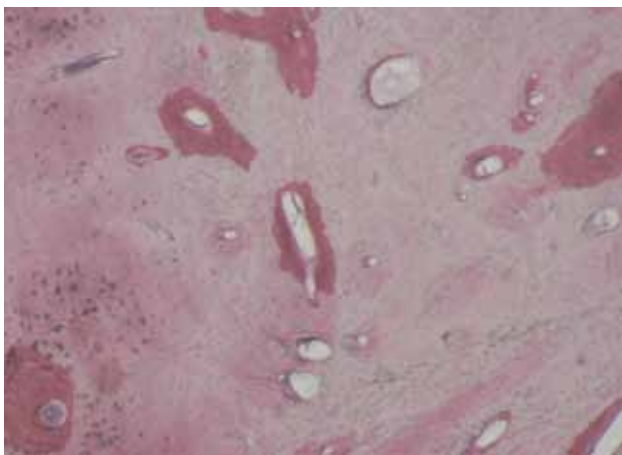


FIG. 5 Few areas of newly formed bone, with a higher affinity for the staining, could be seen. Toluidine blue acid fuchsin. 40X.

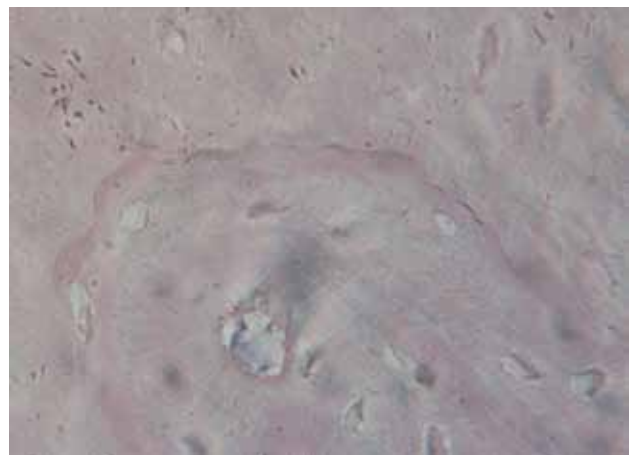


FIG. 6 Cementing lines, a characteristic feature of bone remodeling, were not present. Toluidine blue acid fuchsin. 400X.

Histological analysis

The biopsy specimen was characterized by very compact bone, with very few small marrow spaces (Fig. 4). Few areas of newly formed bone, with a higher affinity for the staining, could also be seen (Fig. 5). Cementing lines, a characteristic feature of bone remodeling, were not present (Fig. 6). Only in some fields it was possible to observe not yet mineralized osteoid matrix, although

osteoblasts were not seen. Within the marrow spaces there was fibrous tissue, with no vessels (Fig. 7). Most of osteocyte lacunae seemed to be empty, and only in some fields it was possible to observe osteocytes within the lacunae.

Histomorphometric analysis showed 98.8% of mineralized bone and 1.2% of marrow spaces.

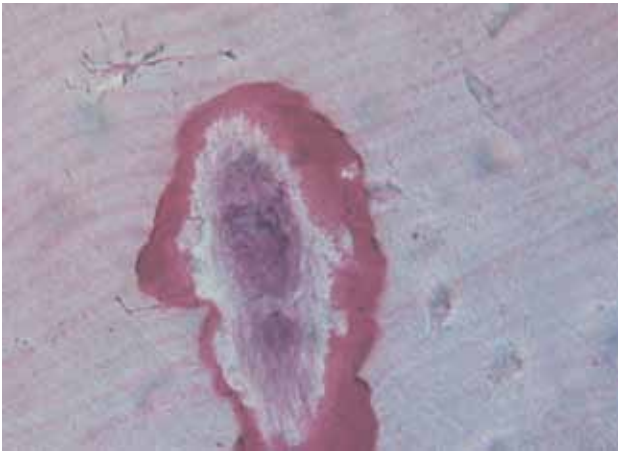


FIG. 7 Within the marrow spaces there was fibrous tissue, with no vessels. Toluidine blue acid fuchsin. 400X.

DISCUSSION AND CONCLUSION

Osteopetrosis is a disease that limits the bone remodelling process, and thus can lead to bone fractures. They are often transverse and may result from minor trauma (14, 15). Most of these fractures can be conservatively treated, whilst surgical intervention, when needed, can represent a real challenge for the surgeon (14, 15). The complexity in surgical treatments is based on the characteristic of bone structure. While osteopetrotic hard bone may be penetrated with a drill bit; high friction and prolonged drilling can make the drill bit blunt. The heat generated can cause bone necrosis and break the drill bit. Besides, this brittleness of bones can cause intra-operative fractures. Due to the difficulties during the operation, the operative time may be prolonged thereby increasing the risk of post-operative infection. The latter should be included in the informed consent (15). There is also a risk of delay in consolidation and non-union owing to impaired bone remodelling (14-15), with a prolonged post-operative course. Due the presence of only few studies on implant rehabilitation in patients affected by Albers-Schonberg's disease, the evidence from studies on orthopaedic's surgery should be considered (15, 16). In the sample analyzed in the present study no cementing lines, hallmark of remodelling, could be detected. Therefore, the surgery could be tricky. Good preoperative planning should anticipate the forthcoming technical difficulties (15). Indeed, the Authors made a careful treatment plan, and undertook all the actions needed to avoid secondary problems. Specifically, the following measures were taken: sequential drilling with regular cooling with saline solution, frequent changes of the drill bit, fractional

decrease in drilling, tapping and screw length, regular clean out of tap, fully coverage of all holes before screw insertion; and finally attention in the use of undue force. The patient had been included in a recall plan with dental hygiene sessions in order to monitor the healing and any eventual risk of infection. During the follow-up it was possible to observe a prolonged healing time of the soft tissues, although no infections or bone complications were present after a 24-month healing time.

In conclusion, results obtained from this case report showed a successful implant prosthodontic rehabilitation in a patient with localised osteopetrosis. Further studies are needed to elaborate a protocol for the implant insertion in patients affected by osteopetrosis.

REFERENCES

- Engfeldt B, Fajers G-M, Lodin H and Pehrson M. Studies on Osteopetrosis. III Roentgenological and Pathologic-anatomical Investigations on Some of the Bone Changes. *Acta Paediatr.* 1960 Jul;49:391-408.
- Vinay C, Uloopi KS, Rao RC, Kumar RS, Madhuri V. Oligodontia Associated With Osteopetrosis: A Rare Case Report. *J Dent Child (Chic).* 2011 Jan-Apr;78(1):53-6.
- Beighton P, Horan F, Hamersma H. A review of the osteopetrosis. *Postgrad Med J.* 1977;53(622):507-16.
- Johnston CC Jr, Lavy N, Lord T, Vellios F, Merritt AD, Deiss WP Jr. Osteopetrosis. A clinical, genetic, metabolic, and morphologic study of the dominantly inherited, benign form. *Medicine (Baltimore).* 1968 Mar;47(2):149-67.
- Shapiro F, Glimcher MJ, Holtrop ME, Tashjian AH Jr, Brickley-Parsons D, Kenzora JE. Human Osteopetrosis. A Histological, Ultrastructural, and Biochemical Study. *J Bone Joint Surg Am.* 1980;62:384-99.
- Manzi G, Romanò D, Moneghini L, Romanò CL. Successful staged hip replacement in septic hip osteoarthritis in osteopetrosis: a case report. *BMC Musculoskelet Disord.* 2012;13:50.
- Armstrong DG, Newfield JT, Gillespie R. Orthopedic Management of Osteopetrosis: Results of a Survey and Review of the Literature. *J Pediatr Orthop.* 1999;19:122-32.
- Bansal V, Kumar S, Arunkumar KV, Mowar A, Khare G. Dental Management in Autosomal Recessive (Intermediate) Osteopetrosis: A Case Report. *Pediatr Dent.* 2010;32:542-5.
- Smith DE, Zarb GA. Criteria for success of osseointegrated endosseous implants. *J Prosthet Dent* 1989;62:567-72.
- Stanford CM, Schneider GB. Functional behaviour of bone around dental implants. *Gerodontology* 2004;21:71-7.
- Trisi P, Rao W. Bone classification: clinical-histomorphometric comparison. *Clin Oral Implants Res* 1999;10:1-7.
- Albrektsson T, Zarb G, Worthington P, Eriksson AR. The long-term efficacy of currently used dental implants: A review and proposed criteria of success. *Int J Oral Maxillofac Implants* 1986;1:11-25.
- Piattelli A, Scarano A, Quaranta M. High-precision, cost-effective cutting system for producing thin sections of oral tissues containing dental implants. *Biomaterials* 1997;18:577-579.
- Marks Jr SC. Congenital osteopetrotic mutations as probes of the origin, structure and function of osteoclasts. *Clin Orthop Relat Res* 1984;189:239-63.
- Dahl N, Holmgren G, Holmberg S, Ersmark H. Fracture patterns in malignant osteopetrosis (Albers-Schonberg disease). *Arch Orthop Trauma Surg* 1992;111:121-3.
- Bhargava A, Vagela M, Lennox CM. Challenges in the management of fractures in osteopetrosis. Review of literature and technical tips learned from long-term management of seven patients. *Injury.* 2009;40:1167-71.