

> **FERNANDO E. KAYATT¹, THALLITA P. QUEIROZ², ROGÉRIO MARGONAR², ELOÁ R. LUVIZUTO³, IDELMO R. GARCIA-JÚNIOR³, ROBERTA OKAMOTO⁴**

¹ DDS, MS, PhD. Private dentist at Ponta Porã, Mato Grosso do Sul, Brazil

² DDS, MS, PhD. Assistant Professor, Department of Health Sciences, Implantology Post Graduation Course, Dental School, University Center of Araraquara – UNIARA, Araraquara, São Paulo, Brazil

³ DDS, MS, PhD. Department of Surgery and Integrated Clinic, Araçatuba Dental School, UNESP-Univ Estadual Paulista, Araçatuba, São Paulo, Brazil

⁴ DDS, MS, PhD. Department of Anatomy, Araçatuba Dental School, UNESP-Univ Estadual Paulista, São Paulo, Brazil

The use of polylactic and polyglycolic copolymer biomaterial in a pre-clinical model of compromised primary stability

TO CITE THIS ARTICLE

Kayatt FE, Queiroz TP, Margonar R, Luvizuto ER, Garcia-Júnior R, Okamoto R. The use of polylactic and polyglycolic copolymer biomaterial in a pre-clinical model of compromised primary stability. *J Osseointegr* 2012;5(1):3-7.

ABSTRACT

Aim Primary implant stability can be compromised by overdrilling of the implant bed. Filling the gap between the implant and the bone with a highly viscous copolymer of polylactic and polyglycolic acid (PLA/PGA) might stabilize the implant and thus supply osseointegration. The aim of this study was to evaluate implants installed in overdrilled beds associated with PLA/PGA in rats tibia model by means of removal torque test and fluorochrome analysis.

Materials and methods For this experiment two groups were selected: in the test group 0.4 mm overdrilled defects (2.0 in diameter and 3 mm long) were produced in the right tibia of seven rats and implants were placed covered with PLA/PGA biomaterial to fill the gap; the control group was not overdrilled and the implants were placed without the biomaterial. Implants of 1.6 mm in diameter and 3 mm long were placed into all defects. Calcein, alizarin and oxytetracyclin were injected at 7, 15 and 21 postoperative days, respectively, and the animals were sacrificed at 35 postoperative day.

Results The results showed that all the implants achieved osseointegration. There were no statistical significance differences in torque-reverse and fluorochrome analysis ($P > 0.05$).

Conclusion We can conclude that overdrilled defects filled with PLA/PGA did not disturb osseointegration in this experimental model.

KEYWORDS Bone remodeling; Dental implants; Fluorochrome; Osseointegration; Polylactic acid; Polyglycolic acid.

INTRODUCTION

Long term dental implants success depends on the rigid implant fixation to the host bone by osseointegration (1). Several factors interfere in the peri-implant bone formation and subsequent mineralization, among them stands out the local involvement in the interface between the bone and the implant (2). On this regard, literature has shown that implant primary stability is a prerequisite to achieve osseointegration (3, 4).

Clinical experimental studies have shown that bone growth can occur in the presence of a relative movement between the implant and the host bone, while the presence of excessive movement results in fibrous membrane formation around the implant (5). The interface between the implant and the host bone constitutes a complex situation which involves revascularization process, graft incorporation and implant integration (6).

Although literature has shown that primary stability plays a fundamental function for the osseointegration process, several clinical situations disable the adequate locking of the implant, in particular the presence of cortical and thin trabecular bone, wide medullar spaces and limited bone availability.

Overdrilling in diameter can be corrected by changing the diameter of the planned implant to a wider one. When this possibility fails another technique may be possible to avoid the abortion of the surgical procedure. Association of biomaterial to implants has been carried out in the past years, especially in post-extraction defects and bone fenestration (6, 7). But an alternative to handle overdrilling has not been studied. In order to avoid implant failure, the insertion of biomaterials to fill the gaps in order to reduce micromovement at the surgical area, can prevent fibrous tissue formation around the implant, which may cause displacement at the bone-implant interface (5, 8). PLA/PGA is a

synthetic biocompatible polymer, well studied for tissue regeneration which attracts much attention owing to its excellent biocompatibility, easy manipulation into desired shapes, uniform quality and controllable degradation timescales compared with natural macromolecules (9).

The presence of a diastase when implants are inserted in fresh tooth sockets allows an acceptable contact between the implant and the host bone (7). Carlsson et al. (7) installed a set of implants in receptor beds, with several distances between the implant to the host bone (Group A: 0 mm; Group B: 0.35 mm; Group C: 0.85 mm) and found out that just in the groups B and C a residual space was observed.

Akimoto et al. (8) assessed the bone filling in defects varying from 0.5–1.4 mm, between the host bone and the implant surface inserted in postextraction alveolus. They concluded that the defect size is inversely proportional to the contact between the bone and the implant. However, Botticelli et al. (10) compared conventional implants installation to stable fixations inserted in the receptor places with a wide marginal defect and they concluded that in defects of up to 1 mm bone neoformation occurs as well as a high osseointegration degree.

When attempting to correct the gap between the implant and the host bone, the use of biomaterials can be necessary (11). In this context, the use of biomaterials in the field of implantology has been important, mainly in cases with inadequate quantity and quality of the host bone.

The aim of this study was to evaluate implants installed in overdrilled beds associated with PLA/PGA in a pre-clinical model (rats tibia) by means of removal torque test and fluorochrome analysis.

MATERIALS AND METHODS

Study design and ethics

Fourteen Wistar rats (90 days old) that were acquired

from the Animal Center of São Paulo State University were maintained at a temperature of 22°C in a 12-h light/12-h dark cycle with free access to water and rodent food. The present study complied with the principles of laboratory animal care and national laws on animal use, and the study was authorized by the Animal Research Ethics Committee of the São Paulo State University, Brazil.

Surgical procedures and fluorochrome labeling

After general anesthesia with xylazine (0.03 ml/100 g body weight [bw]/intraperitoneal [ip]; Dopaser® Laboratories Calier SA, Barcelona, Spain) and ketamine (7 ml/kg bw/ip; Fort Dodge Saúde Animal Ltd, Brazil), the animal right tibias were shaved and disinfected with polyvinylpyrrolidone iodide (Indústria Química e Farmacêutica Rioquímica Ltd, Brazil). Using aseptic technique, an incision was made through the skin of the upper third of the tibia and periosteum, and full-thickness flaps were reflected. Under copious sterile saline irrigation, bone drill and implant placement were performed in both groups as described below.

- › Control group (CG): Implants of commercially pure degree II titanium in screw form with the surface modified by acid etching with nitric acid, with 1.6 mm of diameter and 3.0 mm of length, were installed in the medial portion of the right tibia. The osteotomy was realized with a spiral drill of 1.4 mm in diameter mounted in electric motor in speed of 1500 rpm, under irrigation with isotonic solution of chloride of sodium to 0.9%, and handpiece with reduction 1:16 and depth of 3 mm, with locking and initial stability.
- › Test group (TG): In this experiment implants were inserted, according to the previous group (CG), but the osteotomy was realized with spiral drill of 2 mm in diameter and the implants were installed without locking and stability, however covered with a PGA/PLA copolymer layer and the beds were filled out with the same biomaterial (Fig. 1).

The periosteum was repositioned and sutured using

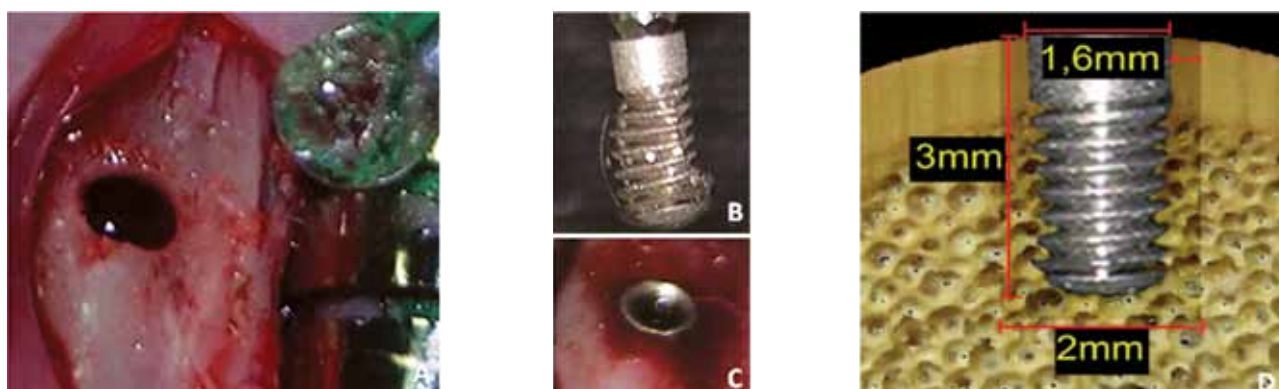


FIG. 1 Test Group. A) Drill hole at the right tibia. B) Implant involved in PLA/PGA. C) Implant inserted at the recipient bed. D) Study design of the implant size and the gap between the implant and the host bone.

polylactic acid sutures (Vycril 5.0, Ethicon, Johnson Prod., São José dos Campos, Brazil). The skin was closed using nylon sutures (Nylon 5.0, Mononylon, Ethicon). All animals received a single dose of 20.000 UI of penicillin G benzathine (Pentabiótico, Veterinário Pequeno Porte, Fort Dodge Saúde Animal Ltd, Campinas, Brazil) by intramuscular injection. Rats received 20 mg/kg body weight of calcein, alizarin and oxytetracyclin (Sigma Chemical, St. Louis, MO, USA) at the 7th, 15th and 21st postoperative day, respectively. The rats were euthanized by anesthetic overdose after the 35th postoperative day and the implants were submitted to the mechanical analysis of reverse torque, until a possible breaking of the bone/implant interface occurred, using analogical torquimeter (ATG3CN(S), Tohnichi, Tokyo, Japan) with graduate scale from 0 to 3N/cm coupled to the intermediary adaptor key with hexagonal tip of 1.4 mm.

Sample processing

The relevant part of the tibia was removed and fixed in neutral buffered 10% formalin solution. The samples were dehydrated in ascending grades of alcohol and followed the routine laboratory processing for non-decalcified sections, with inclusion in hard-grade acrylic resin (LR White®, London Resin Company Ltd, Berkshire, England). After inclusion, the blocks were set on slides, cut lengthwise to a thickness of 40 µm (Microslice 2® Ultratec Inc, Santa Ana, USA) and worn out to a thickness of about 15 µm.

Histomorphometric analysis

Images were acquired using a digital camera coupled to an epifluorescence microscopy and connected to the computer by Leica DC 300F program, with a magnification of 25x. Two selected areas were evaluated for each animal (one area along the implant and the other area at valleys of the implant threads). Stained (marked) area were quantified using ImageLab 2000 program, version 2.4. The data were tabulated and presented in the tables.

Statistical analysis

The obtained data were statistically analyzed by GMC 2002 program. Comparisons were made between the absolute and medium areas marked by fluorochromes of both groups, using Student's t test.

RESULTS

Fluorescence analysis allowed to evaluate the deposition of calcium occurred for each period. The fluorochromes used were calcein, injected at 7 postoperative days (green staining), alizarin, injected at 14 postoperative days (red staining) and oxytetracyclin, injected at 21 postoperative days (visualization of deposited calcium in blue staining). Based on interactively drawn false color

images (Adobe Photoshop, Adobe, San Jose, CA, USA), images from the same field were overlapped allowing a dynamic analysis of bone tissue deposition in each analyzed period (Fig. 2). Besides, the quantification of the fluorescence stained areas allowed a more dynamic visualization of the bone tissue mineralization process in the three periods.

The fluorescence stained areas values obtained in the control group are described in Table 1. The fluorescence stained areas values obtained in the tested group, are described in Table 2. The obtained values of the fluorescence stained areas of the threads of the implants from controls and test groups are described in Table 3 and Table 4, respectively. All implants, when submitted to the reverse torque test, resisted to 35N/cm, without the occurrence of breaking of the bone/implant interface and with no statistical significant difference ($P>0.05$).

DISCUSSION

Overdrilling in diameter can be corrected changing the diameter of the planned implant to a thicker one. When this possibility fails another technique may be possible to avoid the abortion of the surgical procedure.

Association of biomaterial to implants has been carried out in the last years, especially in post extraction defects and bone fenestrations (12, 13), though have not been studied as an alternative for handling overdrilling. This association can reduce micro movement at the surgical site, preventing fibrous tissue formation around the implant, which may cause displacement at the bone-implant interface, and avoiding implant failure (14, 15). This study evaluates the process of osseointegration in two forms of implant insertion: implants with primary locking (established by the literature with high success indices) and implants without initial stability, hypothesis studied by Ivanoff (16) however, filling the receptor area with PLA/PGA polymer.

Several authors discuss the distance allowed between the implant and the alveolar wall, associated or not to the use of biomaterials. Harris et al. (17) affirm that with a distance between the bone wall and implant up to 0.5 mm an acceptable bone/implant contact can be established. However, Botticelli et al. (10) and Paolantonio et al. (18) found different results in defects created with 1 mm and 2 mm, respectively, concluding that these marginal defects are filled by bone and with a high osseointegration degree, independently of the use of mechanical barriers.

Evaluating the PLA/PGA polymer, none of the experimental areas had presented indications of inflammatory reaction. The biomaterial degrades by hydrolysis, cellular degradation or enzymatic pathways (19). It is mentioned, commonly, as being highly biocompatible when applied as synthetic barrier or as

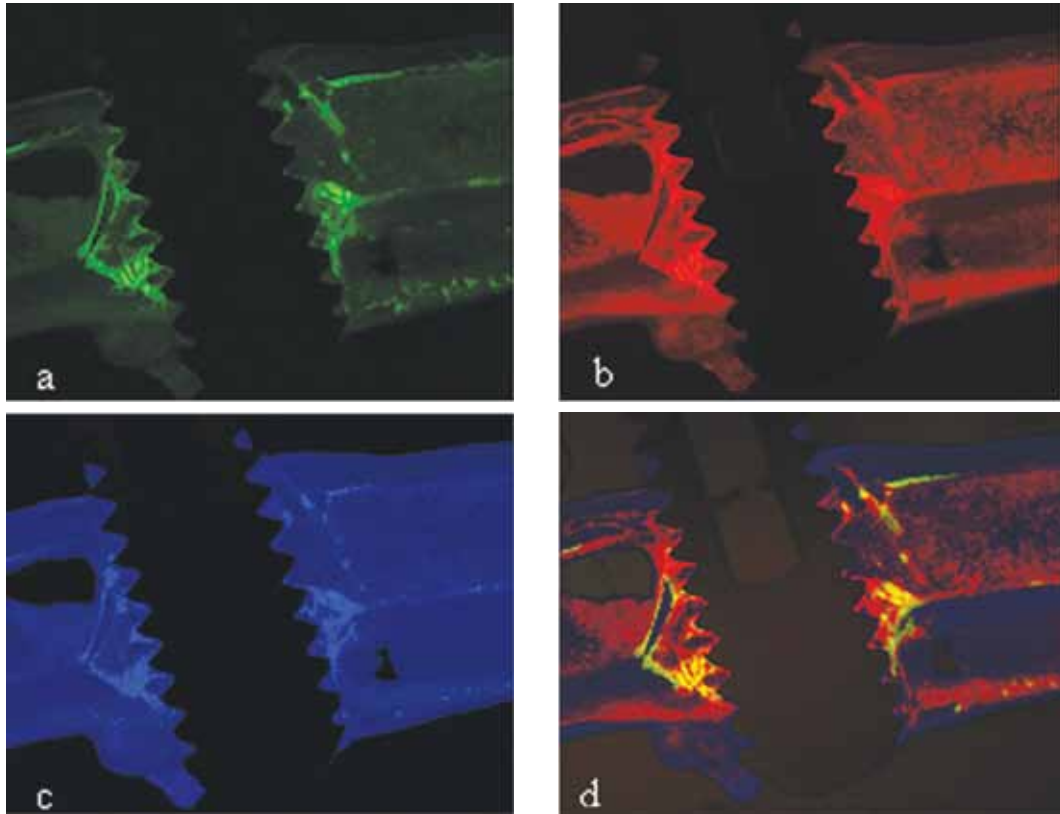


FIG. 2 Calcein (a), alizarin (b) and oxytetracyclin (c) stained at treated group. Images from the same field overlapped allowing a dynamic analysis of bone tissue deposition (d).

CG	Studied area	Calcein Area	Alizarin Area	Oxytetracyclin Area
Mean Value	470,3	46,4	57,8	47,7
%	100%	9,9%	12,30%	10,14

TABLE 1 Area (μm^2) of fluorochrome staining in the control group.

TG	Studied area	Calcein Area	Alizarin Area	Oxytetracyclin Area
Mean Value	512,1	28,6	29,04	27,68
%	100%	5,58%	5,67%	5,40%

TABLE 2 Area (μm^2) of fluorochrome staining in the test group.

These values were submitted to the Student's "t" test, being considered significant, at the level of 1% $\alpha = 0,01$, in the marked areas by the calcein and alizarin with equality probability of 0,84% and 0,12%, respectively. In the marked areas by the oxytetracyclin, were considered significant statistically, at the level of 5% $\alpha = 0,05$, with equality probability of 1,02%.

CG	Total area	Calcein Area	Alizarin Area	Oxytetracyclin Area
Mean Value	0,54	0,11	0,18	0,12
%	100%	20,3%	33,3%	22,2%

TABLE 3 Fluorochrome stained area (μm^2) of the threads in the control group.

TG	Total area	Calcein Area	Alizarin Area	Oxytetracyclin Area
Mean Value	0,345	0,059	0,086	0,067
%	100%	17,1%	24,93%	19,42%

TABLE 4 Fluorochrome stained area (μm^2) of the threads in the test group.

These values were submitted to Student's "t" test, being considered significant, at the level of 5% $\alpha = 0,05$, in the marked areas by the calcein with equality probability of 4,48%. In the marked areas by the alizarin and oxytetracyclin, they were considered statistically no significant, same samples $\alpha > 0,05$, with equality probability of 24,16% and 31,04%, respectively.

bioactive molecules carrier (20).

The use of polymer in our study aided in the stabilization and in the appropriate positioning of the implant, fact that clinically contributes with the prosthetic result. There was delay in the bone tissue deposition in the implant periphery in the test group, as the substitution of the polymer occurred slowly, justifying to smallest speed of bone tissue formation, when compared to the control group. Clinically in these situations, the beginning of the prosthetic phase is postponed a little, which can help bone deposition that does not interfere in the final clinical results. However, in our results the polymer allowed bone growth into the defects present around the implants.

The results found in this analysis with fluorochromes corroborate the histological studies of Okamoto and Russo (21) for the largest deposition of calcium, what suggests the largest bone formation, in the period of 14 days, identified by alizarin. However, the methodology consists in absence of delimitation of the cells of bone tissue, once this allows the evaluation just of the calcium deposition, not being possible the realization of an analysis of the bone tissue cells formed around the implant. The results showed that the control group presented the highest medium value of marked area by the fluorochromes in all areas and studied periods, justified for the largest contact between the bone and the initial implant; however, no statistically significant difference was observed between the studied groups in implant valleys areas at 14 and 21 postoperative days. No evidence of deficiency in the mineralization process was found, as shown by the demarcations of calcium deposition enhanced by the fluorochromes.

In spite of the expectation of a lower index of osseointegration for the tested group, our results showed that both groups presented similar results considering bone deposition on the implants surface in all analysed periods.

CONCLUSION

From our results we can conclude that overdrilled defects filled with PLA/PGA did not disturb osseointegration in this experimental model. Nevertheless, new studies are necessary in order to better evaluate osseointegration in implants placed in overdrilled beds, especially in the oral environment. Even though the implant is submerged, masticatory forces can influence the results.

REFERENCES

- Olsen S, Ferguson SJ, Sigríst C, Fritz WR, Nolte LP, Hallermann W, Caversaccio M. A novel computational method for real-time preoperative assessment of primary dental implant stability. *Clin Oral Implants Res* 2005 Feb;16(1):53-9.
- Szmukler-Moncler S, Salama H, Reingewirtz Y, Dubruille JH. Timing of loading and effect of micromotion on bone-dental implant interface: review of experimental literature. *J Biomed Mater Res* 1998;43(2):192-203.
- Brånemark PI, Hansson BO, Adell R, Breine U, Lindström J, Hallén O, Ohman A. Osseointegrated implants in the treatment of the edentulous jaw. Experience from a 10-year period. *Scand J Plast Reconstr Surg Suppl* 1977;16:1-132.
- Albrektsson T, Brånemark PI, Hansson HA, Lindström J. Osseointegrated titanium implants. Requirements for ensuring a long-lasting, direct bone-to-implant anchorage in man. *Acta Orthop Scand* 1981; 52:155-70.
- Søballe K, Hansen ES, B-Rasmussen H, Jørgensen PH, Bünger C. Tissue ingrowth into titanium and hydroxyapatite-coated implants during stable and unstable mechanical conditions. *J Orthop Res* 1992;10(2):285-99.
- Sjöström M, Lundgren S, Nilson H, Sennerby L. Monitoring of implant stability in grafted bone using resonance frequency analysis. A clinical study from implant placement to 6 months of loading. *Int J Oral Maxillofac Surg* 2005 Jan;34(1):45-51.
- Carlsson L, Röstlund T, Albrektsson B, Albrektsson T. Removal Torques for polished and rough titanium implants. *Int J Oral Maxillofac Implants* 1988;3(1):21-4.
- Akimoto K, Becker W, Persson R, Baker DA, Rohrer MD, O'Neal RB. Evaluation of titanium implants placed into simulated extraction sockets: a study in dogs. *Int J Oral Maxillofac Implants* 1999;14(3):351-60.
- Zhou G, Liu W, Cui L, Wang X, Liu T, Cao Y. Repair of porcine articular osteochondral defects in non-weightbearing areas with autologous bone marrow stromal cells. *Tissue Eng* 2006;12(11):3209-21.
- Botticelli D, Berglundh T, Buser D, Lindhe J. The jumping distance revisited: An experimental study in the dog. *Clin Oral Implants Res* 2003;14(1):35-42.
- Huys LW. Replacement therapy and the immediate post-extraction dental implant. *Implant Dent* 2001;10(2):93-102.
- Botticelli D, Berglundh T, Lindhe J. The influence of a biomaterial on the closure of a marginal hard tissue defect adjacent to implants. An experimental study in the dog. *Clin Oral Implants Res* 2004;15(3):285-92.
- Jung RE, Hälgl GA, Thoma DS, Hämmerle CH. A randomized, controlled clinical trial to evaluate a new membrane for guided bone regeneration around dental implants. *Clin Oral Implants Res* 2009 Feb;20(2):162-8.
- Lioubavina-Hack N, Lang NP, Karring T. Significance of primary stability for osseointegration of dental implants. *Clin Oral Implants Res* 2006;17(3):244-50.
- Huiskes R, Van Driel WD, Prendergast PJ, Søballe K. A biomechanical regulatory model for periprosthetic fibrous-tissue differentiation. *J Mater Sci Mater Med* 1997;8(12):785-8.
- Ivanoff CJ, Sennerby L, Lekholm U. Influence of initial implant mobility on the integration of titanium implants. An experimental study in rabbits. *Clin Oral Implants Res* 1996;7(2):120-7.
- Harris WH, White RE Jr, McCarthy JC, Walker PS, Weinberg EH. Bony ingrowth fixation of the acetabular component in canine hip joint arthroplasty. *Clin Orthop Relat Res* 1983;(176):7-11.
- Paolantonio M, Dolci M, Scarano A, d'Archivio D, di Placido G, Tumini V, Piattelli A. Immediate implantation in fresh extraction sockets. A controlled clinical and histological study in man. *J Periodontol* 2001;72(11):1560-71.
- Issa JP, Bentley MV, Iyomasa MM, Sebald W, De Albuquerque RF. Sustained release carriers used to delivery bone morphogenetic proteins in the bone healing process. *Anat Histol Embryol*. 2008;37(3):181-7.
- Rimondini L, Nicoli-Aldini N, Fini M, Guzzardella G, Tschon M, Giardino R. In vivo experimental study on bone regeneration in critical bone defects using an injectable biodegradable PLA/PGA copolymer. *Oral Surg Oral Med Oral Pathol Oral Radiol Endod* 2005;99(2):148-54.
- Okamoto T, de Russo MC. Wound healing following tooth extraction. Histochemical study in rats. *Rev Fac Odontol Aracatuba* 1973;2(2):153-69.