

> S. LONGONI<sup>1</sup>, L. DUSI<sup>2</sup>, A. BALDINI<sup>3</sup>, S.G. MARINO<sup>4</sup>, M. SARTORI<sup>5</sup>

<sup>1</sup> MD, DDS Specialist in Oral Surgery, Head of Prosthodontics, Milano-Bicocca University Dental School, Monza, Italy

<sup>2</sup> DDS Private practice, Lazzate (MB), Italy

<sup>3</sup> DDS Private practice, Bergamo, Italy

<sup>4</sup> DDS Specializing in Oral Surgery, Milano-Bicocca University Dental School, Monza, Italy

<sup>5</sup> DDS, PhD in Experimental Periodontology, Milano-Bicocca University Dental School, Monza, Italy

## Preoperative adaptation of allogeneic bone graft using a stereolithographic model: case report of a fixed complete denture

### TO CITE THIS ARTICLE

Longoni S, Dusi L, Baldini A, Marino SG, Sartori M. Preoperative adaptation of allogeneic bone graft using stereolithographic model: a fixed complete denture case report. *J Osseointegr* 2013;5(2):31-36.

### ABSTRACT

**Aim** To replace an adequate bone volume for the implant placement in presence of a severe maxillary atrophy reducing intraoperative times and postoperative morbidity.

**Materials and methods** After a diagnostic waxing up aimed at identifying the bone volumes to be regenerated for implant placement, a stereolithographic model (obtained from a computed tomography) was used for adapting an iliac crest allogeneic block. The 6-part division of the block was performed using templates. The obtained bone blocks were shaped to obtain an ideal morphology, at the closest contact possible with the receiving atrophic bone crest.

Six months later eight implants were placed at second-stage surgery and a fixed complete denture was made after 4 months.

**Results** At the second-stage surgery, the mean overall bone ridge horizontal increase was  $4.8 \pm 0.2$  mm, whereas the mean bone blocks resorption was of  $0.9 \pm 0.1$  mm (18.75%). A follow-up three years later revealed that the implants survival was 100% and the patient did not have any major complaint. Clinical, radiographic and histologic results confirm that allogeneic bone graft may be a valid alternative to autologous bone graft.

**Conclusions** Allogeneic bone blocks may represent a viable alternative for ridge restoration in presence of severe atrophy of the jaws. Nevertheless, various factors including suitable blood supply, the thickness and quality of the receiving bone crest and the perfect closure of the soft tissues, are to be taken into account regarding graft integration.

**KEYWORDS** Allogeneic bone block; Bone regeneration; Maxillary atrophy; Stereolithographic model.

### INTRODUCTION

The absence of loads on maxillary bone arches resulting from teeth loss leads to bone resorption and, thus, to alterations of the threedimensional relationships between maxilla and mandible (1). In order to obtain a biomechanically favorable distribution of functional loading and a long-term survival of an implant-prosthetic rehabilitation, adequate bone volume is required (2, 3).

Guided Bone Regeneration, ridge splitting techniques and bone grafts have been successfully used to restore ridge morphology, but not without risks and drawbacks (4-11).

Several parameters must be evaluated to obtain the most predictable result. These include residual ridge width, blood supply, shape and dimension of the volumes that need to be regenerated. Furthermore, the patient's refusal to autogenous bone harvesting has to be taken into account. Autogenous bone graft leads to longer operative times, higher costs and post-operative morbidity and it requires surgery at donor site, too.

A valid alternative to autogenous harvest, in case of class IV atrophy according to the Cawood and Howell classification, is represented by allogeneic bone blocks grafting. Reducing the operative times requires that the allogeneic bone blocks be shaped and intimately adapted to a stereolithographic model obtained according to the data provided by a computed tomography (CT) during the pre-operative stage.

Although autogenous bone graft is still considered the "gold standard" in ridge augmentation procedures (12-16), several researches reveal that allogeneic bone graft in combination with resorbable membranes is a reliable and predictable alternative if properly planned and standardized surgical technique is followed (15-17)

Keith et al., in a 3-years follow-up study, evaluated the reliability of allogeneic bone graft like grafting material; of the 82 bone blocks they placed, only 7 failures were registered. Most block allograft failures (86%) occurred 0 to 12 months after placement and were due to lack of

remodeling of the corners and edges of the block that had led to the laceration of the overlying tissues, to the trauma exerted by the temporary prosthesis and the development of infections (17).

However, most of these studies are based on a relatively short follow-up; further studies and long-term data are required to ensure long-term bone grafts stability and implants survival (15, 17)

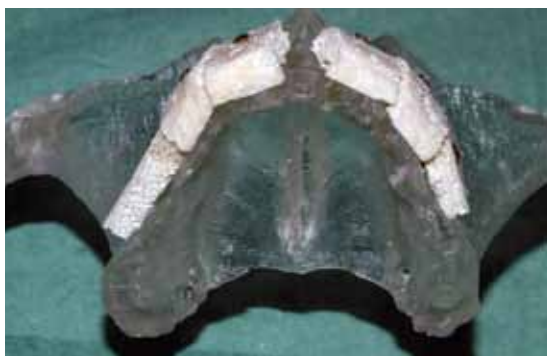The advantages of using bone allografts include convenience for the surgeon, decreased operative trauma for the patient, an almost unlimited supply of reconstructive material, lower blood loss, absence of donor site morbidity, and shorter operative times (18).

Stereolithographic models may be used with the aim of facilitating the surgical operation and reducing the operative times. These models are created based on data collected with tomographic analysis and their average deviation with original dimensions ranges from 0.20–0.85 mm with the percentage of error between 0.6% and 6% (19). Thanks to this technique, and also using diagnostic waxing up, the clinician is able to evaluate the bone volumes that have to be restored. Moreover, the clinician may adapt the bone grafts to the model in order to obtain an intimate contact between the bone ridge and the graft, promoting an earlier graft vascularization. This paper describes a case report in which a complete regeneration of the upper maxilla was carried out using blocks of allogeneic bone. Beside the clinical and radiographic results, histological samples were also collected to assess the bone remodeling process.

## MATERIALS AND METHODS

A 55-year-old female turned to us requesting a fixed prosthesis restoration. The patient revealed severe upper maxillary atrophy. The treatment plan included a first surgery to increase the volume of the bone crest for the implant placement and subsequently the prosthodontic restoration was performed.

The inclusion criteria were as follows: non-smoker



**FIG. 1** Bone blocks were adapted onto the stereolithographic model in order to the maximum surface contact area with the host tissue.

patient, atrophy of class 4 according to Cawood and Howell classification, patient's objection to autogenous harvest, patient enjoying good general health without any disease that might jeopardise graft survival or bone regenerative surgery.

The bone blocks allograft used for this case (Tutogen corticocancellous bone block; Tutogen Medical GmbH, Neunkirchen, Germany) were produced according to the US Food and Drug Administration rules and the standards of the American Association of Tissue Banks (AATB) in order to prevent any kind of immunoreaction, including those due to prions (17, 20).

### First surgery: bone blocks placement on the stereolithographic model

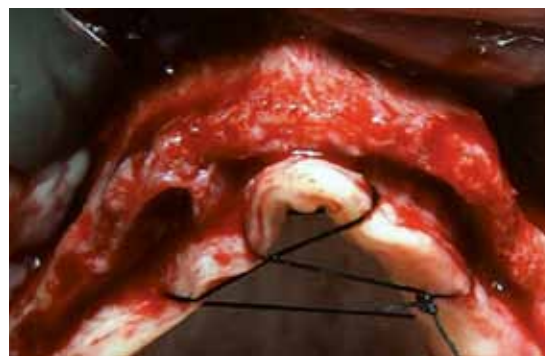One hour before the surgery, a sterile operative field was prepared and the surgeon prepared the aluminium paper templates, which were used as a guide during the bone blocks cutting procedure, in order to optimize the available bone.

The bone blocks were then cut, adapted and fixed on the stereolithographic model (Fig 1). The model was then dipped into a 0.9% sterile saline solution to allow the rehydration of the bone blocks.

### First surgery: bone block placement on the patient

After midazolam sedation (intravenous administration) and local anesthesia with articaine 4% plus adrenaline (1:100,000) (Ubistesin; 3M ESPE, Seefeld, Germany), a crestal incision, from second right molar to second left molar, with distal vertical releasing incision was performed and a full-thickness flap was raised (Fig. 2). The periosteal debridement of the bone ridge was done with a pear-shaped bur at 20,000 rpm. The bone ridge was then perforated with a fissure bur to induce bleeding and promote graft vascularization.

Bone blocks were then removed from the stereolithographic model and transferred on the patient's crest. All the six blocks were closely fixed with osteosynthesis screws in order to obtain the maximum surface contact area. The cancellous part of the graft



**FIG. 2** The full thickness flap showed the thin residual bone ridge (Class IV according to Cawood a & Howell).

was placed in contact with the host bone to promote the graft revascularization while the cortical surface of the graft was placed outside to reduce bone resorption (Fig. 3). To prevent graft rotation and obtain maximum stability, 2 screws for each block were used and screwed up to the palatal plate of the maxillary crest.

All sharp angles and edges of the blocks were smoothed to avoid perforation of the overlying flap. Bovine pericardium membrane (Tutodent membrane; Tutogen Medical GmbH, Neunkirchen, Germany) was placed over the grafts (Fig. 4) and periosteal incisions were made to reduce flap tension and to obtain the passive closure of the soft tissues over the surgical area.

The mucoperiosteal flap was closed without any tension using Vicryl 4-0 (Johnson & Johnson Somerville, NJ, USA). The patient was given a full temporary prosthesis, with palatal support only, relined with soft resin, (HydroCast® Tissue Treatment, Hackensack, NJ, USA), before being discharged. The prosthesis, obtained according to diagnostic waxing up, allowed offering the patient an idea of the final aesthetic result right from the start. Check-up and selective suture removal followed 10 and 20 days after surgery (Fig. 5).

### Second surgery: implant placement

This phase began 6 months after bone grafts placement. Basing on data collected with CT-scan and diagnostic waxing up, a surgical template for the implant placement was made.

The same intravenous sedation and local anesthesia were used. A mucoperiosteal full-thickness flap was made to expose the bone ridge and the fixation screws were removed and all the bone grafts were successfully incorporated (Fig. 6, 7).

Eight implant sites were prepared and two bone specimens were harvested at graft-ridge interface to evaluate the degree of creeping substitution process into the bone blocks. Bone blocks were fixed in 4% formalin and sent for the histologic examination.

All the implants (Prima™; Keystone dental, Burlington, MA, USA) were placed at crestal level by using a surgical guide (Fig. 8).

After 4 months a partial-thickness flap was raised. The incision line was made along the palatal side of the crest in order to obtain an adequate quantity of keratinized gingiva around the healing abutments (Fig. 9).

The final fixed complete denture was made using intraoral luting technique to achieve precision and passivity (Fig. 10, 11) (21).

## RESULTS

### Clinical results

The buccal/palatal bone increase and graft resorption were calculated using the images from the cross-sections obtained from of the two tomographic examinations.

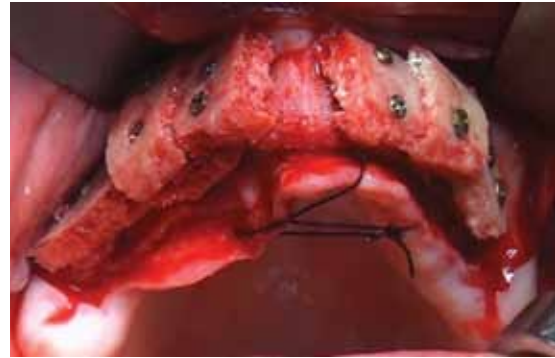


FIG. 3 Bone blocks were closely adapted on bone ridge and fixed.

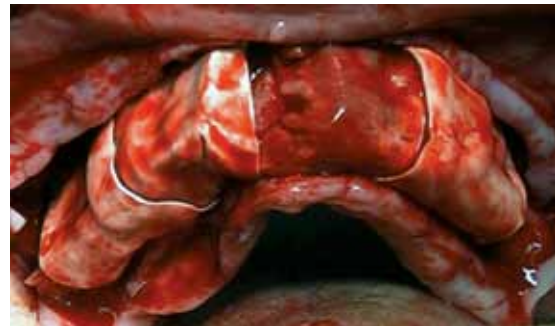

FIG. 4 Bovine pericardium membrane was placed over the bone blocks.

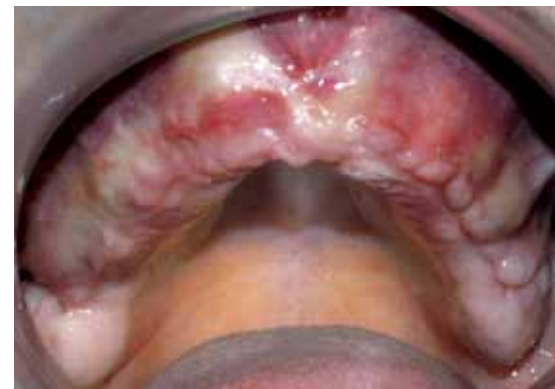

FIG. 5 Soft tissue healing 20 days after surgery.

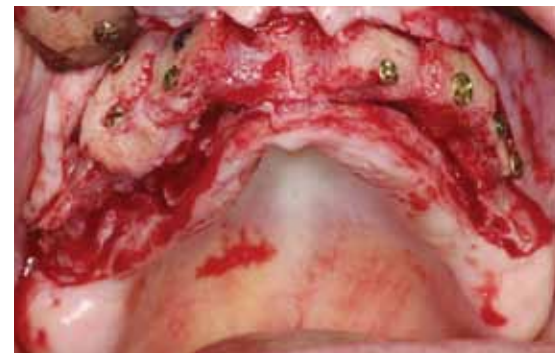
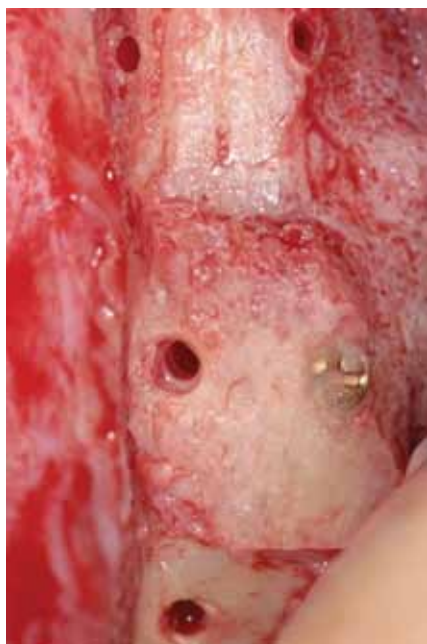
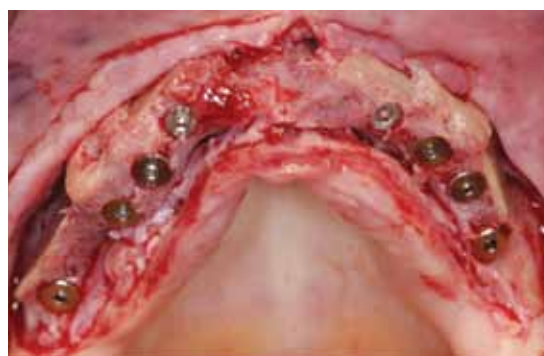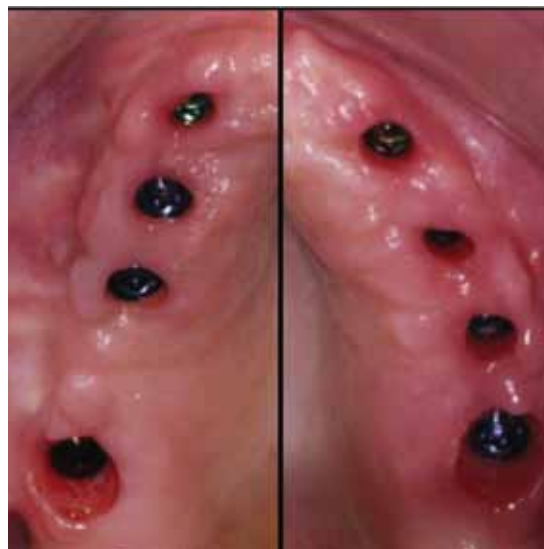FIG. 6 At the re-entry, 6 months after first surgery, all the blocks were well integrated and vascularized.



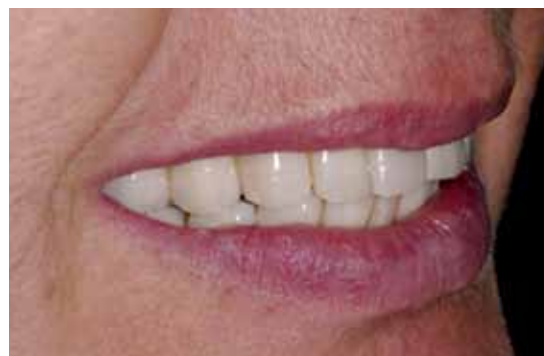**FIG. 7** Osteosynthesis screws were screwed up to bone graft level. In some areas no bone resorption occurred during bone blocks engraftment.



**FIG. 8** According to diagnostic waxing up, eight submerged implants were placed.



**FIG. 9** Soft tissue after healing screws positioning. A great amount of keratinized gingiva was present around each implant.



**FIG. 10** Final aesthetic result.

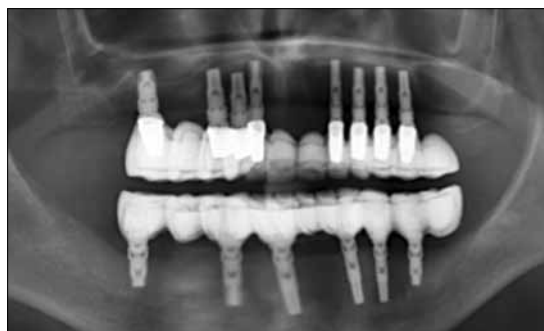The mean overall bone ridge horizontal increase was  $4.8 \pm 0.2$  mm, whereas the mean bone blocks resorption was of  $0.9 \pm 0.1$  mm (18.75%). The results were in line with the values reported in the literature (5, 22, 23, 24). After raising the flap, all bone blocks were well integrated and all the heads of osteosynthesis screws were aligned with regenerated bone level (Fig. 6, 7). A follow-up three years later revealed a 100% implants survival and the patient did not have any major complaint (Fig. 12).

**Histologic results**

All the specimens showed the allograft bone blocks surrounded by new bone. Active signs of osteoclast activity were detectable at the outer limits of bone blocks and along host ridge-graft interface. The newly formed bone was well vascularized and showed vital osteoblasts and fibrillar architecture (Fig. 13, 14, 15).

**DISCUSSION**

Bone autograft still remains the "gold standard" in ridge augmentation procedures due to its osteogenetic, osteoinductive and osteoconductive proprieties. Allograft, on the contrary, only serves as osteoconductive matrix for the new bone formation. Although clinical studies have proven the reliability of allografts (15-18), concerns about disease transmission remain and the risk of immune responses cannot be ruled out (25). The composition of the graft influences both its rate of revascularization and mechanical proprieties. The greater the medullar percentage is, the lower the mechanical resistance and the earlier the revascularization will be. Bone blocks have to be closely



**FIG. 11** Ortopantomography after definitive prosthesis delivery.

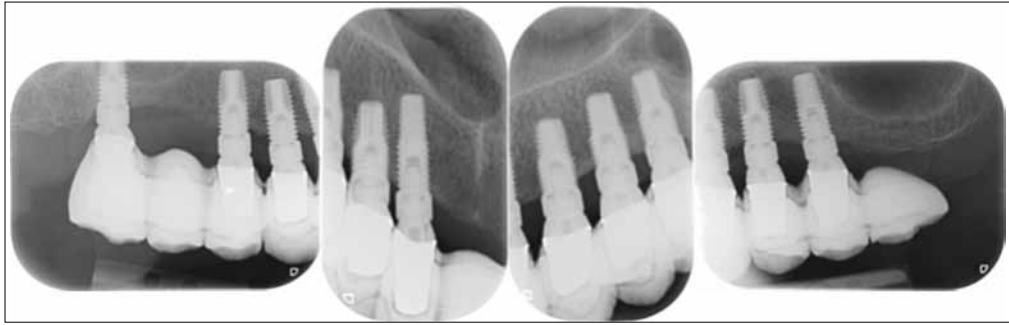

FIG. 12 Three years follow-up; intraoral radiograph.

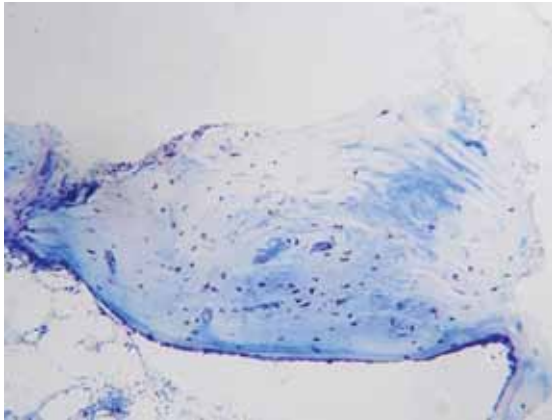


FIG. 13 Toluidine blue staining was used to show vital osteocytes. The new bone was characterized by the presence of vital cells.

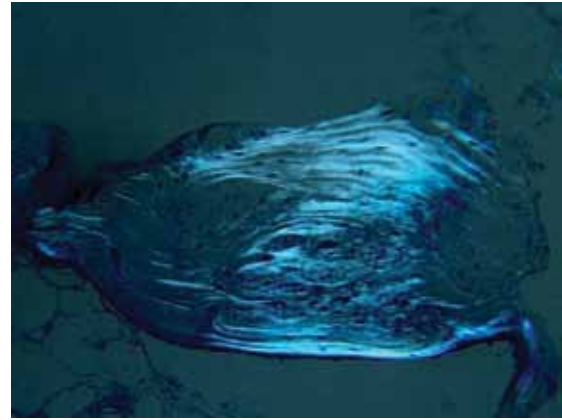


FIG. 14 A polarized light image of the previous field showed the fibrillar architecture of the new formed bone surrounded by allograft bone with its lamellar structure.

adapted to the host ridge with their cancellous side placed towards the recipient site. A rigid fixation of the blocks is mandatory. A movement of 10 to 20  $\mu\text{m}$  during the early stages of wound healing is enough to direct differentiation of mesenchymal cells into fibroblasts instead of osteoblasts (26), ultimately leading to failure of the allograft. To obtain the maximum stability of the graft, osteosynthesis screws should be screwed up to palatal cortical plate.

Accuracy must be also taken into account during edge shaping to avoid soft tissue laceration. A study from Rothamel et al. (27) showed that the pericardium membrane promoted the proliferation of human osteoblasts.

The use of stereolithographic models allowed to shape and adapt the bone blocks on a template almost identical to host bone, thus reducing operative time. Moreover, these procedures enable to place bone blocks with respect to the diagnostic waxing up in order to obtain the most favorable implant position.

## CONCLUSION

This case report suggests the reliability of allogeneic bone graft as restoring material. Pre-operative adaptation of bone blocks onto a stereolithographic model allowed to place the graft material so that an

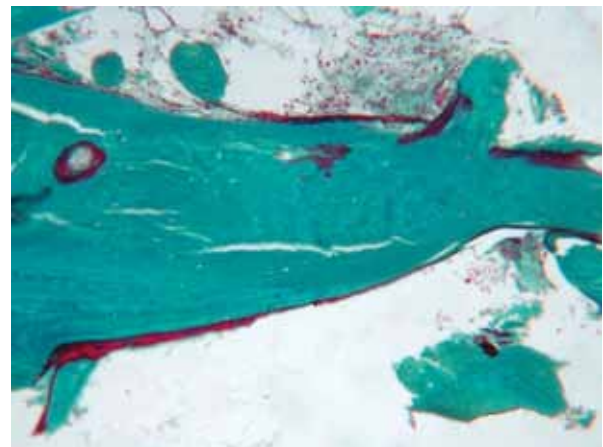


FIG. 15 Trichrome Gomori's stain let to evaluate bone formation: a bone trabecula in which were present both new bone in the upper side and mineralized bone allograft in the central area. On the left side was also visible a blood vessel.

axial distribution of masticatory loading along implants could be obtained. Histologic results showed the presence of newly formed bone surrounding the graft material, sign of active remodeling.

The follow up after three years did not reveal any bone graft failure and all the implants showed good clinical and radiographic signs.

## REFERENCES

1. Cawood JI, Howell RA. Reconstructive preprosthetic surgery. I. Anatomical considerations. *Int J Oral Maxillofac Surg* 1991;20:75-82.
2. Misch CE. Bone classification, training keys to implant success. *Dent Today* 1989;8:39-44.
3. Saadoun AP, Le Gall M. Keys to success in implant osseointegration. *Int J Dent Symp* 1994;2:6-11.
4. Nyström E, Ahlqvist J, Kahnberg KE, Rosenquist JB. Autogenous onlay bone grafts fixed with screw implants for the treatment of severely resorbed maxillae. Radiographic evaluation of preoperative bone dimensions, postoperative bone loss, and changes in soft-tissue profile. *Int J Oral Maxillofac Surg* 1996;25:351-359.
5. Buser D, Dula K, Hirt HP, Schenk RK. Lateral ridge augmentation using autografts and barrier membranes: a clinical study with 40 partially edentulous patients. *J Oral Maxillofac Surg* 1996;54:420-432.; discussion 432-433.
6. Misch CM. Comparison of intraoral donor sites for onlay grafting prior to implant placement. *Int J Oral Maxillofac Implants* 1997;12:767-776.
7. Chiapasco M, Abati S, Romeo E, Vogel G. Clinical outcome of autogenous bone blocks or guided bone regeneration with e-PTFE membranes for the reconstruction of narrow edentulous ridges. *Clinical Oral Implants Res* 1999;10:278-288.
8. Chiapasco M, Romeo E, Casentini P, Rimondini L. Alveolar distraction osteogenesis vs. vertical guided bone regeneration for the correction of vertically deficient edentulous ridges: a 1-3-year prospective study on humans. *Clin Oral Implants Res* 2004;15:82-95.
9. Joshi A. An investigation of post-operative morbidity following chin graft surgery. *Br Dent J* 2004;196:215-218; discussion 211.
10. Raghoebar GM, Meijndert L, Kalk WW, Vissink A. Morbidity of mandibular bone harvesting: a comparative study. *Int J Oral Maxillofac Implants* 2007;22(3):359-365.
11. Demetriades NC, Park J, Laskarides C. Retrospective clinical evaluation of an alternative bone expansion technique for implant placement in atrophic edentulous maxilla and mandible. *J Oral Implantol* 2010 Jul 21. [Epub ahead of print]
12. Khan SN, Cammisa FP Jr, Sandhu HS, Diwan AD, Girardi FP, Lane JM. The biology of bone grafting. *J Am Acad Orthop Surg* 2005;13:77-86.
13. Hjørting-Hansen E. Bone grafting to the jaws with special reference to reconstructive preprosthetic surgery. A historical review. *Mund Kiefer Gesichtschir* 2002;6:6-14.
14. Pape HC, Evans A, Kobbe P. Autologous bone graft: properties and techniques. *J Orthop Trauma* 2010;24 Suppl 1:S36-40.
15. Peleg M, Sawatary Y, Marx RN, et al. Use of corticocancellous allogeneic bone blocks for augmentation of alveolar bone defects. *Int J Oral Maxillofac Implants* 2010;25:153-162.
16. Barone A, Varanini P, Orlando B, Tonelli P, Covani U. Deep-frozen allogeneic onlay bone grafts for reconstruction of atrophic maxillary alveolar ridges: a preliminary study. *J Oral Maxillofac Surg* 2009;67:1300-1306.
17. Keith JD Jr, Petrunger P, Leonetti JA, et al. Clinical and histologic evaluation of a mineralized bone allograft: results from the developmental period (2001-2004). *Int J Periodontics Restorative Dent* 2006;26:321-327.
18. Perrott DH, Smith RA, Kaban LB. The use of fresh frozen allogeneic bone for maxillary and mandibular reconstruction. *Int J Oral Maxillofac Surg* 1992;21:260-265.
19. Sinn DP, Cillo JE Jr, Miles BA. Stereolithography for craniofacial surgery. *J Craniofac Surg* 2006;17:869-875.
20. Moreau Mf, Gallois Y, Basle MF, Choppard D. Gamma irradiation of human bone allografts alters medullary lipids and releases toxic compounds for osteoblastic-like cells. *Biomaterials* 2000;21:369-376.
21. Longoni S, Sartori M, Maroni I, Baldoni M. Intraoral luting: modified prosthetic design to achieve passivity, precision of fit, and esthetics for a cement retained, implant-supported metal-resin-fixed complete denture. *J Prosthodont* 2010 Feb;19:166-170.
22. Acocella A, Bertolai R, Colafranceschi M, Sacco R. Clinical, histological and histomorphometric evaluation of the healing of mandibular ramus bone block grafts for alveolar ridge augmentation before implant placement. *J Craniomaxillofac Surg* 2010;38:222-230.
23. Cordaro L, Torsello F, Accorsi Ribeiro C, Liberatore M, Mirisola di Torresanto V. Inlay-onlay grafting for three-dimensional reconstruction of the posterior atrophic maxilla with mandibular bone. *Int J Oral Maxillofac Surg* 2010;39:350-357.
24. Cordaro L, Armadè DS, Cordaro M. Clinical results of alveolar ridge augmentation with mandibular block bone grafts in partially edentulous patients prior to implant placement. *Clin Oral Implants Res* 2002;13:103-111.
25. Buck BE, Malinin TI. Human bone and tissue allografts. Preparation and safety. *Clin Orthop Relat Res* 1994;(303):8-17.
26. Hürzeler MB, Quiñones CR, Morrison EC, Caffesse RG. Treatment of peri-implantitis using guided bone regeneration and bone grafts, alone or in combination, in beagle dogs. Part 1: Clinical findings and histologic observations. *Int J Oral Maxillofac Implants* 1995;10:474-484.
27. Rothamel D, Schwarz F, Sculean A, Herten M, Scherbaum W, Becker J. Biocompatibility of various collagen membranes in cultures of human PDL fibroblasts and human osteoblast-like cells. *Clin Oral Implants Res* 2004;15:443-449.