

► J.L. CALVO-GUIRADO¹, M.L. RAMOS-OLTRA¹, B. NEGRI¹, R.A. DELGADO-RUIZ², P. RAMIREZ-FERNÁNDEZ¹, J.E. MATE-SÁNCHEZ¹, M. ABOUD², J. GARGALLO ALBIOL, M. SATORRES NIETO³, G. ROMANOS⁴

¹ Department of General and Implant Dentistry, Faculty of Medicine and Dentistry, Murcia University, Murcia, Spain

² Department of Prosthodontics and Digital Technology, School of Dental Medicine, Stony Brook University, New York, USA

³ Department of Oral Surgery, International University of Catalunya, Barcelona, Spain

⁴ Professor and Associate Dean for Clinical Affairs, School of Dental Medicine, Stony Brook University, New York, USA

Osseointegration of zirconia dental implants modified by femtosecond laser vs. zirconia implants in healed bone: a histomorphometric study in dogs with three-month follow-up

TO CITE THIS ARTICLE

Calvo-Guirado JL, Ramos-Oltra ML, Negri B, Delgado-Ruiz RA, Ramirez-Fernández P, Mate-Sánchez JE, Abooud M, Gargallo Albiol J, Satorres Nieto M, Romanos G. Osseointegration of zirconia dental implants modified by femtosecond laser vs. zirconia implants in healed bone: a histomorphometric study in dogs with three-month follow-up. *J Osseointegr* 2013;5(3):39-44.

ABSTRACT

Aim The aim of the present study was to evaluate the stability and osseointegration of zirconia dental implants modified by femtosecond laser vs. zirconia implants with sandblasted surface.

Materials and methods A total of 48 dental implants were used in this study. After the extraction of premolars (P2, P3, P4) and molars (M1), and 2-months healing period, implants were randomly inserted in both sides of the lower jaw of 6 American Foxhound dogs: 16 zirconia implants with sandblasted surface on endosseous portion (Control Group), 16 zirconia implants with sandblasting and laser modification of the endosseous neck portion only (Test Group A), and 16 zirconia implants with sandblasting and laser modification over the whole endosseous portion (Test Group B). Stability was evaluated by Periotest, while osseointegration was evaluated by Bone-to-implant contact (BIC) assessed by histomorphometry at 1 and 3 months after surgery.

Results All implants were stable; Periotest® values (PTV) for Control Group were -5.75 ± 0.22 ; for Group A -6.125 ± 0.26 and for Group B -7.625 ± 0.27 . BIC was greater for group B implants at both 1 and 3 months. No differences between the Control Group and Group A over the examined time periods were detected.

Conclusion The present results suggested that the surface treatment of zirconium implants by femtosecond laser increases implant stability and bone to implant contact.

KEYWORDS Animal model; Bone to implant contact; Femtosecond laser; Implant stability; Zirconia implants.

INTRODUCTION

Nowadays, the use and behavior of titanium implants have extensively been studied over long periods (1-3). Titanium is regarded as the 'gold standard' among contemporary dental implant materials. Different studies postulated the high success and survival rates of titanium implants in many different applications (4-5). However, several complications and disadvantages, such as sensitivity to titanium and its alloys, allergic reactions (6-8), gingival recession around abutments in the esthetic zone and their associated complications (9) have also been reported.

Recently, the use of zirconia implants has been proposed as an alternative to titanium. Ceramics are known for their excellent biocompatibility and high resistance to wear and they are widely used in many clinical applications (10). Recent advances in the development of high mechanical strength ceramics have made them attractive as new materials for dental implants. Yttria partially stabilized tetragonal zirconia offers several advantages due to its flexural strength and high resistance to fracture (11).

Zirconia implants have shown excellent bone response, minimal inflammatory reactions in the vicinity of their surface, biocompatibility, excellent esthetic properties, low bacterial and pathogen adhesion, high fracture resistance and high compression resistance (12-18).

Histologically, zirconia supports good response of connective tissue and bone as well as excellent osseointegration as observed in animal studies (19).

In order to improve initial stability and osseointegration, zirconia implants have been treated with different chemical and pharmacological surface modifications which include: covering with a layer of CaP, sand-blasting or impregnation with collagen type I and biphosphonate solutions (20), sand-blasting in combination with acid etching (21), incorporation of CaP nanocrystals (22-23), sand-blasting with the addition of micro and macro-

retentive areas to the apical portion(24), acid etching with hydrofluoric acid (25), covering with a layer of calcium-liberating titanium oxide (26), sand-blasting in combination with acid etching and alkaline etching (27), covering with zirconia by means of chemical electrodeposition plus a covering of glycine (28).

Recently femtosecond laser microstructuring have been proposed to modify the surface of zirconia dental implants by the following benefits: increases the roughness of the surface without increase the monoclinic phase (29), increases the bone to implant contact (30), improves the bone density when immediate loading is applied (31), and makes comparable the bone to implant contact of titanium versus zirconia implants (32).

The aim of the present study was to evaluate the stability, by Periotest, and the osseointegration, by histomorphometry, of zirconia dental implants modified by femtosecond laser vs. zirconia implants with sandblasted surface.

MATERIALS AND METHODS

Clinical procedures

Six Fox Hound dogs of one year of age, each weighting between 14–15 kg were used in the present study. The Ethics Committee for Animal Research at the University of Murcia, Spain approved the study on November 2010. The study design followed the Royal Decree (RD) 1201 of 10th October 2005 on protection of animals used for experimental and other scientific purposes and Law 32 of November 7th, 2007 for the care given to animals in farming, transport, testing and sacrifice. Furthermore, the project followed the guidelines established by the European Union Council Directive of November 24th, 1986 (86/609/EEC) and Directive 2010/63/EU of the European Parliament and of the Council of 22nd September 2010 on protection of animals used for scientific purposes.

During all surgical procedures, the animals were pre-anesthetized with acepromazine (0.2–1.5%mg/kg [i.m] LABIANA Life Sciences, S.A. PFIZER, Barcelona, Spain) 10 min before administrating butorphanol (0.2mg/kg) and medetomidine (7 mg/kg). An intravenous catheter was inserted in the cephalic vein and propofol was infused at a slow, constant rate of 0.4mg/kg/min.

Local infiltrative anesthesia was administered at the surgical sites. These procedures were carried out under the supervision of a veterinary surgeon (NM). An intrasulcular incision was performed from distal of P1 to mesial of M2, raising a full thickness flap to expose the bone crests and the entire dental crowns of P2, P3, P4 and M1. The teeth were sectioned in a buccolingual direction at the bifurcation using a tungsten carbide bur and the roots individually extracted using a periosteal and forceps, without damaging the bone walls.

Bilateral mandibular tooth extractions (P2, P3, P4 and

M1) were performed. Wound closure was carried out by using single resorbable sutures (Dexon 3-0, Davis & Geck, American Cyanamid Co., Wayne, NJ, U.S.A.). During the first week after surgery, the animals received antibiotics and analgesics: Amoxicillin (500mg, twice a day) and Ibuprofen (600mg, three times a day) via the systemic route. The dogs were fed a soft diet for 14 days followed by a normal pellet diet.

Implants

The dental implants used in the present study were sandblasted White SKY® (Bredent medical® GMBH & Co. KG, Senden, Germany) zirconia implants of 4mm diameter and 10 mm length.

The texturing process (29) was carried out using a system based on a Tsunami® Ti: Sapphire oscillator (Spectra Physics, Newport Corporation, Alberta, Canada) that emits pulses of hundreds of femtoseconds (1 fs = 10⁻¹⁵ s), near infrared wavelengths (795 nm) and energy of the order of 10 nanojoules, with a 80 MHz repetition rate.

In order to provide sufficient energy, this was connected to a Spitfire® regenerative amplifier (Spectra Physics, Newport Corporation Alberta, Canada) that uses the CPA (chirped pulse amplification) technique.

Amplifier output pulses were emitted at 120 fs duration and energies in the order of milijoules. The system's repetition rate was 1 kHz. Pulse output had linear polarization and Gaussian transverse distribution (TEM₀₀ mode), with a beam width of about 9 mm (Fig. 1).

Implant insertion procedure

A total of 48 dental implants were used and they were divided into 3 groups of 16 each: zirconia implants with sandblasted surface on the endosseous portion (CONTROL); sandblasted zirconia implants with laser modification of the endosseous neck portion only (GROUP A); sandblasted zirconia implants with laser modification over the entire endosseous portion (GROUP B) (Fig. 2).

The 48 implants were randomly allocated (www.randomization.org) in molar and premolar areas of the edentulous mandibles of the dogs.

The implants were inserted after a two-month healing period. After crestal incision, a full thickness flap from the P1 to the M2 area was reflected and each site was prepared following the protocol recommended by the implant manufacturer (Bredent medical® GMBH & Co. KG, Senden, Germany), preparing a bed of 4mm diameter and 10mm length. Each mandible received 4 cylindrical screw implants, all with the same dimensions in the intraosseous portion.

Periotest®

Implant stability was evaluated using the Periotest® device (Siemens, Bensheim, Germany), calibrated from -8 (maximum stability) to +50 (minimum stability), recording the periotest (PT) values obtained for each




FIG. 1 Laser and microtexturizing device. Right image showing the laser source, left image showing the complex system of lens that guides the laser beam to the processing platform.

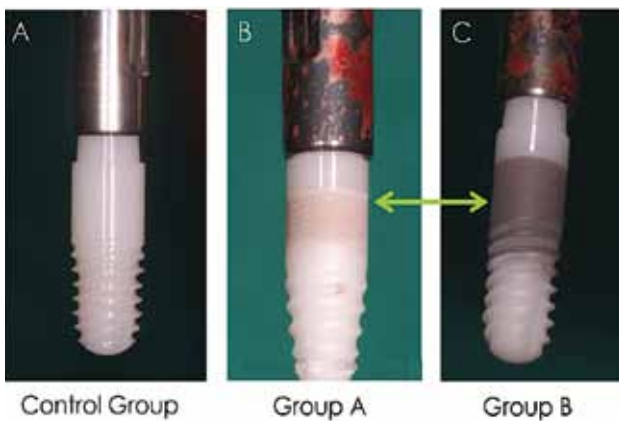


FIG. 2 Clinical view of implant samples from each study group. Control Group (zirconia implant with sandblasted surface), Group A (zirconia implant with microgrooved neck) and Group B (zirconia implant microgrooved over entire endosseous surface). The laser treated implants show a characteristic dark area corresponding to the laser microgrooved surfaces.

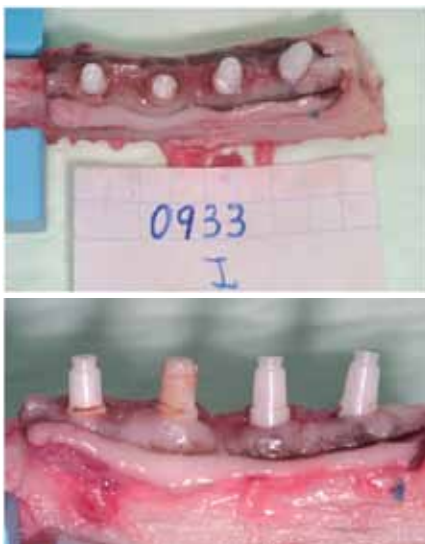

FIG. 3 Samples containing zirconia implants after sacrifice and retrieval. Left: occlusal view. Right: buccal view.

zirconia implant. The first set of PT were registered immediately after implant insertion. Recalibration was performed at each period before the measurements were taken in order to ensure reproducibility; a single

operator (MR) registered three repeated measurements, and the mean average was recorded.

Sacrifice

Three animals were sacrificed after 1 month and the remaining 3 were sacrificed after a 3 months healing period. For euthanasia, the veterinary surgeon administered pentobarbital sodium (Abbott Laboratories, Chicago, IL, USA), subsequently perfused with a fixative (4% formaldehyde solution) through the carotid arteries. The mandibles were en bloc dissected and the surrounding soft tissues were detached (Fig. 3).

Histological preparation and examination

Histological and histomorphometric study was carried out at the Department of Pathology of the University of Cologne, Germany. The samples were fixed in formalin and dehydrated in a graded series of ethanol for 15 min each and dried with acetone at 30%, 50%, 70% and 90% for 15 minutes each, then 100% acetone for 30 minutes. The samples were then embedded in methylmethacrylate (Technovit 7100®, Heraeus Kulzer, Wehrheim, Germany). Using a micro-cut diamond bur (Exakt-Apparatebau, Norderstedt, Germany), samples were cut in vestibulo-lingual direction into 100 μ m-thick sections along the axis of each implant. These sections were ground down to a 50-80 μ m thickness using extrafine paper discs with 2000 grain granulometry. In this way, 3 central sections per implant were obtained. Toluidine blue staining was applied.

The sections were studied and analyzed under light microscopy (Olympus BX 61, Hamburg, Germany). Histomorphometry was performed with a video camera (Sony 3CCD, Berlin, Germany) with 70X magnification. Images were digitalized (Axiophot-System, Zeiss) and benchmarks were established. Bone-to-implant contact (BIC) was assessed as bone in direct contact with the implant in relation to the total implant perimeter (Fig. 4).

Statistical analysis

Statistical analysis was performed using SPSS 16.0 software (SSPS Inc., Chicago, IL, USA). Descriptive analysis was performed for each variable and group. To confirm the normality of the sample, the Kolmogorov-Smirnov test (ANOVA) was applied to determine differences between means for independent variables. The Bonferroni post-hoc test was applied to assess differences between means. Data are reported as mean \pm SD with a significance level of $p < 0.05$.

RESULTS

Clinical data

All animals survived the postoperative period without any complications. No implants failure was detected over the study period (1 and 3 months). The soft tissues were

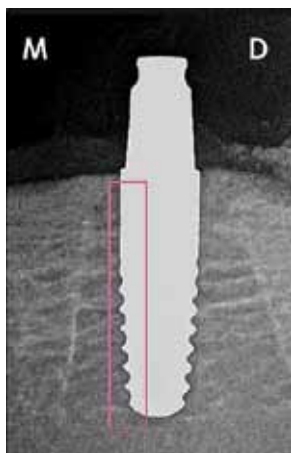


FIG. 4 Rx image of zirconia implant showing the area where BIC was measured.

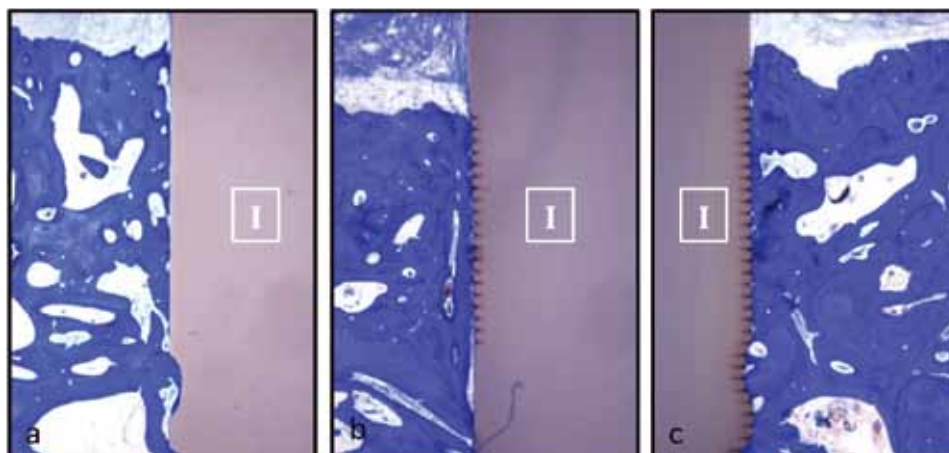


FIG. 5 Histological samples from untreated surface, control (A); neck treated, Group A (B); entire surface treated, Group B, showing the presence of denser bone in the laser treated implants (C). 10X magnification. Toluidine blue staining.

healthy, without signs of inflammation, hyperemia, swelling or oozing.

Periotest®

At day 0, the values obtained ranged between -3 and -7. The lowest values were obtained for control group implants, followed by Group A and Group B. At 1 month, in all the groups PT values decreased in comparison with the day of implant placement, but without statistically significant differences. At 3 months, a significant increase in the PT values was observed in all the groups, with Group B showing the greatest gain (Table 1).

Histological analysis

The presence of peri-implant soft tissue was observed, till the top of the bone crest. There were no signs of inflammation. At 3-month bone density seemed to be higher in areas with microgrooves (Fig. 5)

The trabecular architecture of the bone around the zirconia implants was classified as lamellar bone due to the circular apposition of bone lamellae around Haversian canals. All groups showed few signs of natural bone remodeling, apposition of osteoid matrix and osteoblasts or lacunae of osteoclasts. Mature bone structures were observed with osteoblasts within the mineralized bone and tight alignments of osteoblasts surrounding the osseous trabeculae. In zirconia implants treated with femtosecond laser, the existence of bone alongside the textured area and soft tissue insertion into the microgrooves were observed as it can be seen at higher magnification (Fig. 6).

Histomorphometric analysis

BIC was greater for Group B implants after 1 and 3-month healing periods. There were no significant differences between the control group and Group A over the two study periods. BIC values in Group B were

significantly higher than in the other groups (Table 2, 3).

DISCUSSION

The present work was designed to study the stability and the osseointegration of zirconia dental implants. Three groups of zirconia dental implants with the same geometry but with differences in the surface treatment were selected. The stability was evaluated at day of implants insertion and at 1 and 3 months, and histology was performed at month 1 and month 3. It is known that the microscopic roughness of the implant surface exerts a large influence on the osseointegration process, due to significantly higher percentages of BIC compared to machined or polished surfaces.

In the present study, using a moderately roughened surface created by laser treatment, higher BIC percentages were found after 1 and 3 months of healing in the groups that had received laser treatment; in particular they were significantly higher in the group of implants with the entire intraosseous surface treated. Histological observation showed that the use of implants with moderate surface roughness resulting from laser treatment may affect the amount of newly formed bone tissue and the degree of BIC. These observations are supported by previous studies using zirconia implants with microtexturized surfaces by Lee J et al. (22), Kohal RJ et al. (33), Bacchelli B et al. (34),

| PT VALUES | DAY 0 | 1 MONTH | 3 MONTHS |
|-----------|--------------|-------------|--------------|
| Control | -4.25±0.21 | -4.001±0.23 | -5.75±0.22 |
| Group A | -5.75±0.25 | -5.125±0.21 | -6.125±0.26 |
| Group B | -6.625±0.24* | -6±0.2* | -7.625±0.27* |

TABLE 1 Comparison of Periotest® values between groupI (* p <0.05).

| BIC | HEALING PERIOD | N | MINIMUM % | MAXIMUM % | MEAN | STANDARD DEVIATION |
|---------|----------------|---|-----------|-----------|---------|--------------------|
| Control | 1 month | 8 | 27.3 | 40.34 | 31.786 | 13.04 |
| | 3 months | 8 | 35.12 | 52.06 | 37.864 | 16.94 |
| Group A | 1 month | 8 | 30.21 | 38.32 | 33.732 | 8.11 |
| | 3 months | 8 | 40.23 | 53.53 | 38.265 | 13.35 |
| Group B | 1 month | 8 | 42.16 | 53.64 | 44.6819 | 11.48 |
| | 3 months | 8 | 46.4 | 60.43 | 47.9423 | 14.03 |

TABLE 2 Comparison of BIC between groups (mean ± SD) (* p <0.05). Bonferroni post hoc for multiple comparison (* p <0.05).

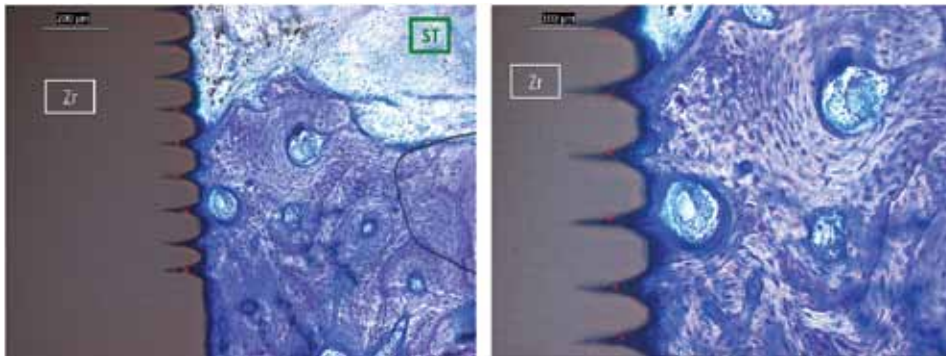


FIG. 6 Bone penetrating the grooves of laser treated zirconia implants can be observed in A) 20X; B) 40X. Toluidine blue staining.

| GROUP | 1 MONTH MEAN SD | 3 MONTHS MEAN SD |
|---------|--------------------|--------------------|
| Control | 31.786 ± 5.89094 | 37.864 ± 3.01417 |
| Group A | 33.732 ± 3.41371 | 38.265 ± 1.78365 |
| Group B | 44.6819 ± 4.65768* | 47.9423 ± 3.15423* |

TABLE 3 Comparison of BIC between groups (mean ± SD) (* p <0.05). Bonferroni post hoc for multiple comparison (* p <0.05).

but as these modifications were not exactly the same as in the present study, they cannot be fully compared. Rocchietta et al. (23), compared the bone tissue responses of 3 different zirconia implant surfaces with titanium implants inserted in rabbits, and concluded that nanometric levels of surface treatment did not increase BIC. The microgroove size in the present work showed, at histological level, penetration of bone inside the microgrooves, that results in higher BIC values. Delgado-Ruiz et al. (31), showed in a dog study that zirconia implants with microgrooved surfaces resulted in an increased bone density in comparison with titanium and zirconia without microgrooves, so the presence of microgrooves probably has an effect on the bone remodeling. This agrees with the results of the present work, although at 1 month the differences were not significant. However, at three months the bone to implant contact was increased, as result of the bone remodeling or of a positive effect of the microgrooves in the bone growth guidance. Calvo Guirado et al. (32), found that microgrooved zirconia implants under immediate load, resulted in

better BIC and crestal bone stability when the implants were inserted subcrestally. In the present study, similar data were obtained regarding the bone to implant contact, although bone remodeling was appreciated but not measured.

With regard to implant stability the present study used the Periotest® method rather than resonance frequency analysis (RFA), as RFA requires the placement of a special attachment (Smartpeg), that is not available for one piece zirconia implants.

Payer et al. (35) made a prospective study of unitary zirconia implants placed in humans. To analyze stability, the Periotest® was used at 6, 12, 18 and 24 months after placement, applying provisional loading in both central and eccentric movements, values obtained were lower than those of the present study. The authors used zirconia implants with untreated surfaces, which may explain the lower Periotest® values.

In the present study, a higher primary stability at the day of implants insertion was followed by a reduction on the stability at first month, and finally a rise of the stability, expressed as more negative Periotest values, was observed at three months.

The stability along the study periods showed variations that probably have relation with the bone healing and bone remodeling, and have a close relation with the values of bone to implant contact. The results of the present study should be carefully considered, due to the small sample size and the differences between species. However the incorporation of microgrooves along the entire intraosseous surface of zirconia dental implants is apparently positive for the bone to implant contact and implant stability.

CONCLUSION

Within the limits of this animal study, it is concluded that the roughness surface of zirconia implants enhanced by laser treatment increases implant stability. The surface treatment of zirconia implants by femtosecond laser produces a significant increase in BIC.

ACKNOWLEDGEMENTS

We would like to thank Prof. Daniel Rothamel of Cologne University (Germany) for his contribution to this study. Source of funding: This study was supported by Bredent Medical (Germany). Conflicts of interest: The authors declare that they have no conflict of interests.

REFERENCES

- Albrektsson T, Sennerby L, Wennerberg A. State of the art of oral implants. *Periodontol* 2000;47:15-26.
- M, Vandeweghe S, Kisch J, Nilner K, De Bruyn H. Long-term follow-up of turned single implants placed in periodontally healthy patients after 16-22 years: radiographic and peri-implant outcome. *Clin Oral Implants Res* 2011 In press.
- Malo P, de Araujo Nobre M, Lopes A, Moss SM, Molina GJ. A longitudinal study of the survival of All-on-4 implants in the mandible with up to 10 years of follow-up. *J Am Dent Assoc* 2011;142:310-20.
- Behneke A, Behneke N, d'Hoedt B. A 5-year longitudinal study of the clinical effectiveness of ITI solid-screw implants in the treatment of mandibular edentulism. *Int J Oral Maxillofac Implants*. 2002;17:799-10.
- Cochran D, Oates T, Morton D, Jones A, Buser D, Peters F. Clinical field trial examining an implant with a sand-blasted, acid-etched surface. *Journal of Periodontology*. 2007;78: 974-82.
- Javed F, Al-Hezaimi K, Almas K, Romanos GE. Is Titanium Sensitivity Associated with Allergic Reactions in Patients with Dental Implants? A Systematic Review. *Clin Implant Dent Relat Res* 2011 In press.
- Siddiqi A, Payne AG, De Silva RK, Duncan WJ. Titanium allergy: could it affect dental implant integration? *Clin Oral Implants Res* 2011;22:673-80.
- Sicilia A, Cuesta S, Coma G, Arregui I, Guisasaola C, Ruiz E, et al. Titanium allergy in dental implant patients: a clinical study on 1500 consecutive patients. *Clin Oral Implants Res* 2008;19:823-35.
- Kan JY, Rungcharassaeng K, Lozada JL, Zimmerman G. Facial gingival tissue stability following immediate placement and provisionalization of maxillary anterior single implants: a 2- to 8-year follow-up. *Int J Oral Maxillofac Implants* 2011;26:179-87.
- Dion I, Rouais F, Baquy C, Lahaye M, Salmon R, Trut L, Cazoria JP, Huang PV, Monties JR, Havlik P. Physico-chemistry and cytotoxicity of ceramics. Part I. Characterization of ceramic powders. *Journal of Materials Science: Materials in Medicine*. 1997;8:325-32.
- Piconi C, Maccauro G. Zirconia as a ceramic biomaterial. *Biomaterials* 1999;20:1-25.
- Deville S, Chevalier J, Gremillard L. Influence of surface finish and residual stresses on the ageing sensitivity of biomedical grade zirconia. *Biomaterials*. 2006;27:2186-92.
- Rimondini L, Cerroni L, Carrasi A, Torricelli P. Bacterial colonization of zirconia ceramic surfaces: an in Vitro and in vivo study. *Int J Oral Maxillofac Implants*. 2002;17:793-8.
- Groessner-Schreiber B, Hannig M, Duck A, Griepentrog M, Wenderoth, DF. Do different implant surfaces exposed in the oral cavity of humans show different biofilm compositions and activities? *European Journal of Oral Sciences*. 2004;112:516-22.
- Canullo L. Clinical outcome study of customized zirconia abutments for single-implant restorations. *International Journal of Prosthodontics*. 2007;20:489-93.
- Kokubo Y, Tsumita M, Sakurai S, Torizuka K, Vult von Steyern P, Fukushima S. The effect of core framework designs on the fracture loads of all-ceramic fixed partial dentures on posterior implants. *Journal Oral Rehabilitation*. 2007;34:503-7.
- Rompen E, Raepsaet N, Domken O, Touati B, Van Dooren E. Soft tissue stability at the facial aspect of gingivally converging abutments in the esthetic zone: a pilot clinical study. *Journal of Prosthetic Dentistry*. 2007;97:119-25.
- Sundh A, Sjögren G. A study of the bending resistance of implant-supported reinforced alumina and machined zirconia abutments and copes. *Dental Materials*. 2008;24:611-7.
- Akagawa Y, Ichikawa Y, Nikai H, Tsuru H. Interface histology of unloaded and early loaded partially stabilized zirconia endosseous implant in initial bone healing. *J Prosthet Dent*. 1993;69:599-604.
- Langhoff JD, Voelter K, Scharnweber D, Schnabelrauch M, Schlottig F, Hefti T, et al. Comparison of chemically and pharmaceutically modified titanium and zirconia implant surfaces in dentistry: a study in sheep. *Int J Oral Maxillofac Surg* 2008; 37:1125-1132.
- Gahlert M, Röhling S, Wieland M, Sprecher CM, Kniha H, Milz S. Osseointegration of zirconia and titanium dental implants: a histological and histomorphometrical study in the maxilla of pigs. *Clin Oral Implants Res* 2009;20:1247-1253.
- Lee J, Sieweke JH, Rodriguez NA, Schüpbach P, Lindström H, Susin C, Wikesjö UM. Evaluation of nanotechnology modified zirconia oral implants: a study in rabbits. *J Clin Periodontol* 2009; 36:610-617.
- Rochietta I, Fontana F, Addis A, Schubach P, Simion M. Surface modified zirconia implants: tissue response in rabbits. *Clin Oral Implants Res* 2009; 20:844-850.
- Pirker W, Korcher A. Immediate, non-submerged, root-analogue zirconia implants placed into single-rooted extraction sockets: 2 year follow-up of a clinical study. *Int J Oral Maxillofac Surg* 2009; 38:1127-1132.
- Gahlert M, Röhling S, Wieland M, Eichhorn S, Küchenhoff H, Kniha H. A comparison study of the osseointegration of zirconia and titanium dental implants. A biomechanical evaluation in the maxilla of pigs. *Clin Implant Dent Relat Res* 2010; 12:297-305.
- Koch FP, Weng D, Krämer S, Biesterfeld S, Jahn-Eimermacher A, Wagner W. Osseointegration of one-piece zirconia implants compared with a titanium implant of identical design: a histomorphometric study in the dog. *Clin Oral Implants Res* 2010; 21:350-356.
- Schliephake H, Hefti T, Schlottig F, Gédet P, Staedt H. Mechanical anchorage and peri-implant bone formation of surface-modified zirconia in minipigs. *J Clin Periodontol* 2010; 37:818-828.
- Bozzini B, Carlino P, Mele C. Electrochemical behavior and surface characterization of Zr exposed to an SBF solution containing glycine, in view of dental implant applications. *J Mater Sci Mater Med* 2011; 22:193-200.
- Delgado-Ruiz RA, Calvo-Guirado JL, Moreno P, Guardia J, Gomez-Moreno G, Mate-Sánchez JE, Ramirez-Fernández P, Chiva F. Femtosecond laser microstructuring of zirconia dental implants. *J Biomed Mater Res B Appl Biomater*. 2011 Jan;96(1):91-100.
- Calvo-Guirado JL, Aguilar-Salvatierra A, Gomez-Moreno G, Guardia J, Delgado-Ruiz RA, Mate-Sanchez de Val JE. Histological, radiological and histomorphometric evaluation of immediate vs. non-immediate loading of a zirconia implant with surface treatment in a dog model. *Clin Oral Implants Res* 2013 . doi: 10.1111/clr.12145
- Delgado-Ruiz RA, Calvo-Guirado JL, Abboud M, Ramirez-Fernandez MP, Mate-Sanchez JE, Negri B, Rothamel D. Histologic and Histomorphometric Behavior of Microgrooved Zirconia Dental Implants with Immediate Loading. *Clin Implant Dent Relat Res* 2013 . doi: 10.1111/cid.12069
- Calvo-Guirado JL, Perez-Albacete Martínez C, Negri B, Delgado-Ruiz RA, Ramirez-Fernández P, Mate-Sánchez JE, Abooud M, Gargallo Albiol J, Satorres Nieto M. Mechanical, histological and histomorphometric evaluation of modified by femtosecond laser zirconia implants versus titanium implants. An experimental study in dogs at three months. *J Osseointegr* 2013;5(2):19-26.
- Kohal RJ, Wolkewitz M, Hinze M, Han JS, Bächle M, Butz F. Biomechanical and histological behavior of zirconia implants: an experiment in the rat. *Clin Oral Implants Res* 2009;20:333-9.
- Bacchelli B, Giavaresi G, Franchi M, Martini D, De Pasquale V, Trirè A, Fini M, Giardino R, Ruggeri A. Influence of a zirconia sandblasting treated surface on peri-implant bone healing: An experimental study in sheep. *Acta Biomater*. 2009;5:2246-
- Payer M, Arnetzl V, Kirmeier R, Koller M, Arnetzl G, Jakse N. Immediate provisional restoration of single-piece zirconia implants: a prospective case series results after 24 months of clinical function. *Clin Oral Implants Res*. 2012 In press.