

> MARCO DEGIDI¹, ADRIANO PIATTELLI², CLAUDIO MARCHETTI³, VITTORIA PERROTTI², GIOVANNA IEZZI²

¹ Private Practice, Bologna, Italy

² Dental School, University of Chieti-Pescara, Italy

³ Dental School, University of Bologna, Italy

Histology of peri-implant bone in a failed implant retrieved from an area of osteonecrosis of the jaw in a patient suffering from multiple myeloma and treated with intravenous bisphosphonates

TO CITE THIS ARTICLE

Degidi M, Piattelli A, Marchetti C, Perrotti V, Iezzi G. Histology of peri-implant bone in a failed implant retrieved from an area of osteonecrosis of the jaw (ONJ) in a patient suffering from multiple myeloma and treated with intravenous bisphosphonates. *J Osseointegr* 2012;1(4):15-20.

KEYWORDS Intravenous bisphosphonates; Dental implants; Failed implants; Osteonecrosis of the jaws.

ABSTRACT

Background Osteonecrosis of the jaw (ONJ) has been reported in the past few years in patients undergoing treatment with bisphosphonates (BP). Few published histological studies of ONJ can be found in the literature and no study has been reported on the peri-implant bone around a dental implant retrieved from an area of ONJ. The aim of the present case was to report the histology of the peri-implant bone around an implant retrieved from an area of ONJ.

Materials and methods Multiple myeloma was diagnosed to a 72-year-old male. The patient underwent treatment with intravenous pamidronate for 2 years and with intravenous zoledronate for additional 3 years. Five years after the diagnosis, 7 immediately loaded dental implants were inserted in the mandible. A preoperative panoramic radiography did show no pre-existing bone lesions. No healing of the post-extraction sockets of the right third molar and of the left second molar was observed. Three years after the implant insertion a breakdown of the oral mucosa covering the implants was observed. The most distal implant was retrieved with a trephine bur, due to mobility.

Discussion The histological findings showed some areas with osseointegration in patients undergoing BP treatment for malignant disease.

Conclusion There is certainly a temporal association between BP use and development of ONJ, but a correlation does not necessarily mean causation. Moreover, generalisations about this complex relationship cannot be made on the basis of a single case report. In patients undergoing intravenous treatment, clinicians must be aware of the increased risk of implant failure and, probably, implant insertion should be avoided at all, until more conclusive data are available.

INTRODUCTION

Nitrogen-containing bisphosphonates (BP) possess a pyrophosphate-like chemical substructure that confers a strong affinity for calcium (1). Nitrogen-containing BPs reduce osteoporotic fracture risk by 50-60% and skeletal-related events by more than 30% (1). In recent years, a complication, consisting in the presence of a non healing oral mucosal ulcer with underlying necrotic bone has been reported in the literature (2, 3). This lesion has been termed Osteonecrosis of the Jaw (ONJ) (2,3). Ninety-four percent of published cases has been reported in multiple myeloma or metastatic bone diseases in patients who received intravenous amino-BPs like zoledronic acid, pamidronate, ibandronate and alendronate (4). The most common site was posterior/lingual mandible, in the area of the mylohyoid ridge (5), and areas with thin mucosa overlying bone prominences such as tori, exostoses (6, 7).

The pathogenesis remains unclear and is probably multifactorial (8-11). BPs could act on the inhibition of osteoclast recruitment, diminution of osteoclast life span and inhibition of the osteoclast activity at the bone surface (2). The profound inhibition of osteoclast function can also inhibit normal bone turnover to an extent that local microdamage from normal mechanical loading or injury cannot be repaired and this can ultimately lead to bone necrosis (6, 7, 11). Moreover, BPs inhibit endothelial function, diminish levels of Vascular Endothelial Growth Factor (VEGF) and, in rat, decrease the rate of capillary formation (12).

BPs have a selective concentration at the interface of the active osteoclast and the bone-resorption surface (8). There is evidence that internalization of the BPs in active osteoclasts disrupts the cytoskeleton and vesicular trafficking, leading to cessation of resorption and induction of apoptosis (3, 4, 13). Treatment with BPs will be aimed also to disrupt the osteocyte signalling (14), and, furthermore, evidence of osteoblastic dysfunction in multiple myeloma has been reported (15). Another action could be on osteoclast precursors to prevent osteoclast formation (4). BPs have also an antiangiogenic effect, being able to decrease endothelial cell proliferation (3, 7) and contributing to the apparent ischemic changes (6). Moreover, they could produce a direct induction of avascular necrosis, an increase in the rate of apoptosis, and a decrease in capillary tube function (8).

A worsening of ONJ during treatment with a novel antiangiogenic drug has been reported (16), and data confirm the possibility that BPs could have a suppressive effect on angiogenesis through an action on IL-17, a proangiogenic cytokine (17). Some drugs could potentiate the known antiangiogenic properties of zoledronate (18). At a molecular level, it has been shown that BP influence osteoclast activity through the modulation of a cell surface receptor or an intracellular enzyme (3). The decrease in bone cellularity and blood flow could lead to a generalized impairment of bone remodelling and of the response to skeletal injury (5). The jaws are constantly undergoing impact loading, which may require a remodelling response and are frequently the site of trauma, such as tooth extraction (5). Furthermore, BPs may prevent hydroxyapatite crystal formation, aggregation and dissolution (19). High concentrations of alendronate and zoledronate were cytotoxic for the osteoblasts (20). In multiple myeloma there is an osteoblast inhibition with absence of bone regeneration and of functional exhaustion and apoptosis of osteoblasts (21).

The available data would, however, suggest that the pathogenesis of ONJ is related more likely to a process in which mucosal damage is the event preceding infection and subsequent bone damage (22). BPs may be toxic to oral epithelium and delayed epithelization may result in exposed bone that, in the presence of oral bacteria, increases the risk of infection (22). A global inhibition of the genes involved in bone remodelling in patients with ONJ has been reported (23).

Patients who take oral BPs are no more at risk of implant failure than other patients (24) and implant success was comparable between patients receiving oral BP therapy and those not receiving this type of therapy (25). Recently, a case was reported of a patient, undergoing oral treatment with BP, who presented a significant bone defect with necrosis after implant placement (26). Clinically, ONJ is characterized by the presence of ulcerated mucosa and exposed, white-yellow,

devitalized bone (5,7). The surrounding soft tissues are often inflamed due to a secondary mucosal infection (5, 6). Pain, oral discomfort, purulent discharge, exudates and fistula are common (5, 6, 8, 27).

The most important clinical characteristic of ONJ is the finding of exposed bone in the oral cavity (28). Patients may be considered to have ONJ if all the following 3 features are present:

- 1) current or previous treatment with a BP;
- 2) no history of radiation therapy to the jaws;
- 3) exposed necrotic bone in the maxillofacial region that has persisted for more than 8 weeks (6, 9, 15, 21, 28).

Tooth extractions were the predominating event preceding ONJ (29), although other causes, such as periodontal disease, dental implant procedures, ill-fitting dentures, were also reported (22). It is unclear why ONJ is limited to the craniofacial bones (19). Probably, there is a unique environment in the oral cavity (6). Patients with a history of periodontal and dental abscesses are at a 7-fold increased risk of developing ONJ (6). Where possible, extractions should be avoided and it is probably best to avoid all elective oral surgery in patients on BP, including endosseous implant placement (30).

Few published histological studies of ONJ can be found in the literature, no microscopic features unique or diagnostic (6). These studies have shown vital cells and bone in more than half the patients (12, 22), pronounced inflammatory changes (12, 22), bone necrosis and infection (2, 28), numerous osteoclasts present in close contact with bone (12), minimal presence of Howship lacunae, congested venules and bacterial infiltrate within deep bone trabeculae (26), an absence of osteoblasts or vascularization (5), fibrosis of marrow spaces in nearly all cases, obliteration of blood vessels only in a few specimens, increased cellularity in the *intima* and *media* of the artery, and actinomyces colonies in all cases (12).

The aim of the present case was to report the histology of the peri-implant bone around an implant retrieved from an area of ONJ.

CASE REPORT

Multiple myeloma was diagnosed to a 72-year-old male. The patient underwent treatment with intravenous pamidronate for 2 years (90 mg every 2 months) and with intravenous zoledronate (4 mg every 2 months) for an additional 3 years.

Five years after the diagnosis, 7 immediately loaded dental implants (XiVE®, DENTSPLY-Friudent, Mannheim, Germany) were inserted in the mandible (Fig. 1, 2).

At suture removal, a delayed healing of the post-extraction sockets of the right third molar and of the left second molar was observed. A bilateral osteonecrosis

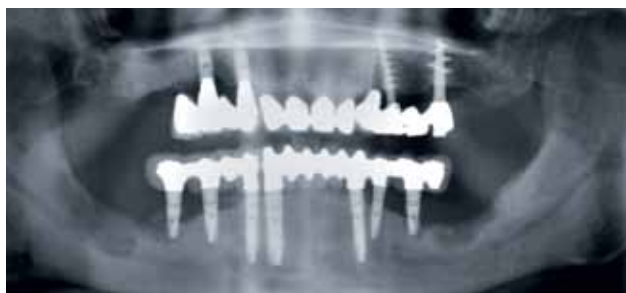
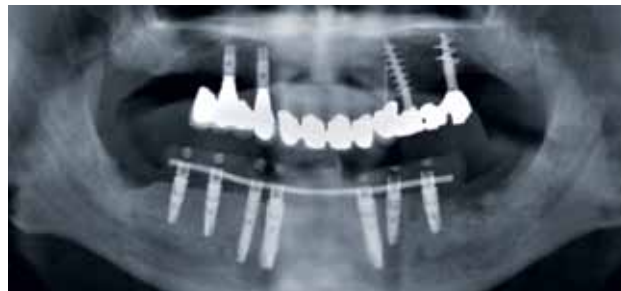
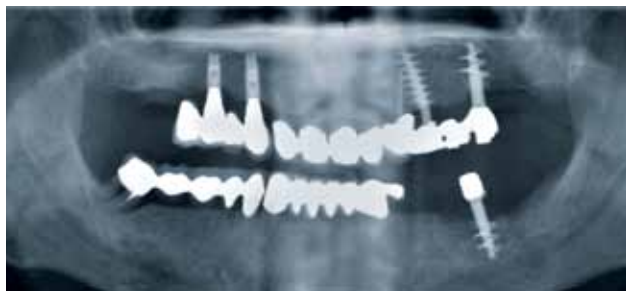FIG. 1 Preoperative panoramic x-ray.

FIG. 2 Postoperative panoramic x-ray.

FIG. 3 The osteonecrosis progressively involved the two distal implants on each side.

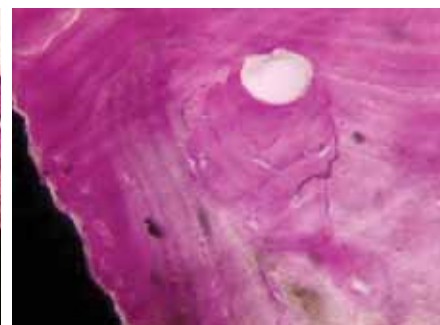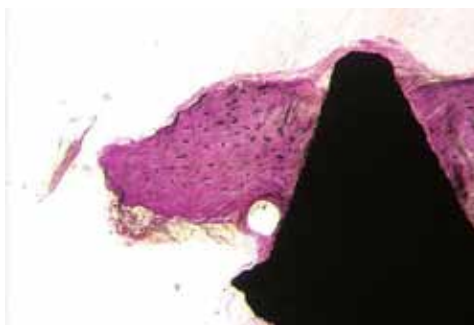
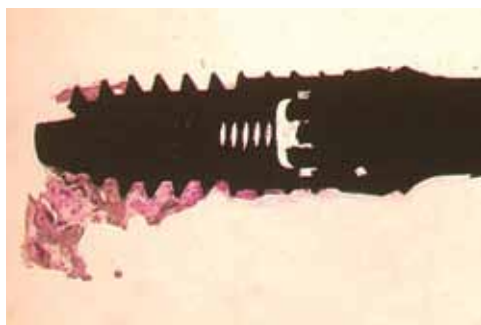


FIG. 4 The bone was present only around the apical portion of the implant. Acid fuchsin-toluidine blue, 10 X.

FIG. 5 At higher magnification, bone was present in contact with the implant surface. Acid fuchsin-toluidine blue, 40 X.

FIG. 6 In some portions of the interface, this bone was still vital, with a normal structure and normal staining characteristics. The osteocyte lacunae were filled by osteocytes. Acid fuchsin-toluidine blue, 100 X.

was then diagnosed.

During the three years after implant placement, the extension of the lesions increased and finally involved the most distal implant in each side (Fig. 3). These two implants were removed; one still had some bone attached to it.

The specimen underwent light microscopical analysis. The implant and the surrounding tissues were stored immediately after removal in 10% buffered formalin and processed to obtain thin ground sections with the Precise 1 Automated System (Assing, Rome, Italy) (31). The specimen was dehydrated in an ascending series of alcohol rinses and embedded in a glycolmethacrylate resin (Technovit 7200 VLC, Kulzer, Wehrheim, Germany). After polymerization, the specimen was sectioned longitudinally along the major axis of the implants with a high-precision diamond disc at about 150 µm and ground down to about 30 µm. Three slides were obtained, which were stained with acid fuchsin and toluidine blue.

RESULTS

At low power modification, bone was present only around the apical portion of the implant (Fig. 4). At higher magnification, bone was present in contact with the implant surface (Fig. 5). In some portions of the interface, this bone was still vital, with a normal structure and normal staining characteristics. A close connection was observed between this bone and the implant surface, and no gaps were found at the interface; also absent were inflammatory infiltrate, connective tissue and epithelial downgrowth. At higher magnification, the osteocyte lacunae were filled by osteocytes (Fig. 6). Osteoid matrix was present in some portions of the interface; no osteoblasts were, however, present. In a few areas bone remodelling and osteons were present. In other areas, non vital bone was present at the interface and also at a distance from the metal surface (Fig 7). This latter type of bone did not show a normal staining and a normal bone. Moreover, this bone appeared to be




FIG. 7 In other areas, non vital bone was present at the interface and also at a distance from the metal surface. Acid fuchsin-toluidine blue, 40 X.

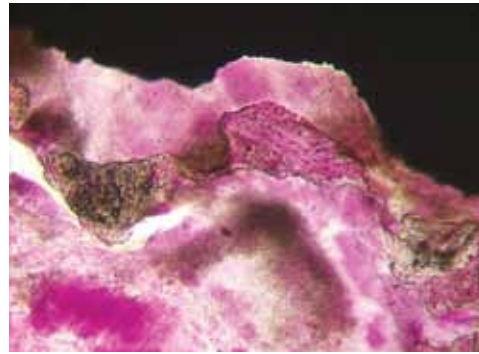


FIG. 8 In some portions, the bone appeared to be partially demineralized. Acid fuchsin-toluidine blue, 40 X.

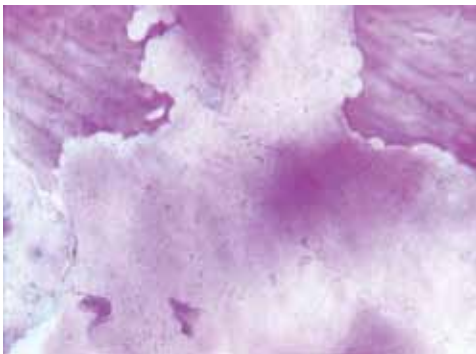


FIG. 9 At higher magnification, Howship lacunae, but no osteoclasts, were observed. Acid fuchsin-toluidine blue, 100 X.

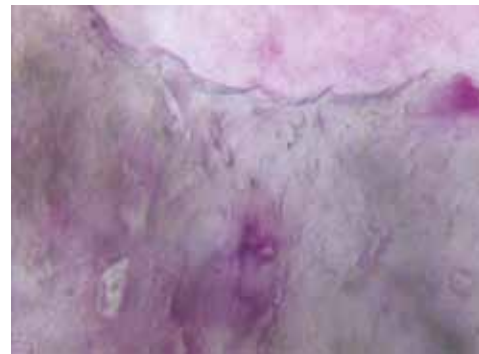

FIG. 10 In other areas, non vital bone was present and the osteocyte lacunae were empty. Acid fuchsin-toluidine blue, 200 X.

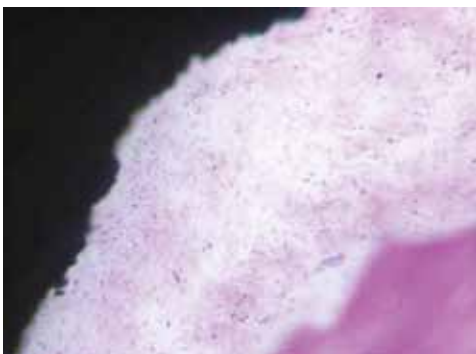

FIG. 11 In some areas of the interface, it was possible to see the presence of a connective tissue with a slight inflammatory cell infiltrate. Acid fuchsin-toluidine blue, 200 X.

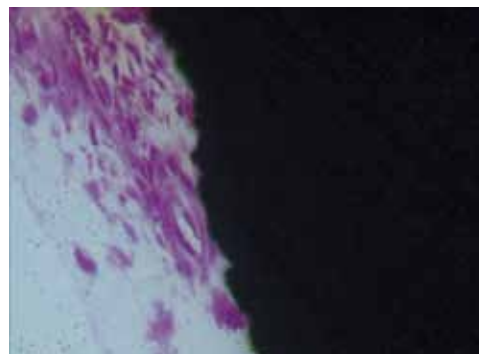


FIG. 12 Only in a few areas, a few small vessels were present; their wall was constituted by a few layers of endothelial cells. Acid fuchsin-toluidine blue, 200 X.

partially demineralized (Fig. 8). No newly-formed bone or osteoblasts were present around this bone. At higher magnification, Howship lacunae, but no osteoclasts, were observed (Fig. 9). The osteocyte lacunae were empty (Fig. 10). In some areas of the interface, it was possible to see the presence of a connective tissue with a slight inflammatory cell infiltrate (Fig. 11). Only in a few areas, a few small vessels were present; their wall was constituted by a few layers of endothelial cells (Fig. 12).

DISCUSSION

Long-term intravenous BP use, especially with zoledronate and pamidronate, seems to be the most important risk for complications (8). Cumulative hazard seems to be 1% after 12 months, 10% after 2 years, and 20% after 3 years (8). After 2 years of treatment, the cumulative hazard of developing ONJ was estimated to be 3% which increased to 11% after 4 years (4). In a retrospective study on 4019 patients, 1.2% of patients

with breast cancer and 2.4% of patients with multiple myeloma developed ONJ (32). A rate of 1 event per 100.000 person-years of exposure for oral BPs has been reported (22). Variables predictive of developing ONJ in multiple myeloma have been reported to be treatment with pamidronate/zoledronate, dental extraction, longer follow-up time, and older age at diagnosis (4,9).

There is evidence that BP use is a contraindication to oral implants (22), like all oral surgical procedures, while other researchers reported no causal relationship between oral BPs and implant failure (24). One patient developing ONJ after implant placement has been reported (33). It is best to avoid all elective oral surgery in patients on BP, including endosseous implant placement (30) above all in patients taking intravenous BP. The present histological findings, that is the presence both of well osseointegrated portions of the implant with a close connection with the surrounding bone and of a gap between bone and implant, with connective tissue and inflammatory cells at the interface, and with the presence of non vital bone, demonstrate that implant osseointegration can occur in patients undergoing BP treatment for malignant disease. A bone regeneration was then present, contrary to reports of a lack of it in patients with multiple myeloma (21). In the present case, no osteoblasts nor osteoclasts were observed; similar results were reported by Badros et al. (33). The present histological results were similar to those reported by Bedogni et al., (27) who found that areas of bone with empty osteocyte lacunae coexisted with areas of bone with viable osteocytes. No inflammatory infiltrate was found in the peri-implant tissues, contrary to the results reported by Badros et al. (33) who, in many cases, found foci of mixed inflammatory cellular infiltration near to the necrotic bone.

BPs are probably involved in the development of ONJ (34), even if a direct causal relationship has yet to be determined (24). While there is clearly a temporal association between BP use and development of ONJ, a correlation cannot be assumed to mean causation (4). It must also be underlined that ONJ is seen overwhelmingly in an oncologic population, where patients are often receiving concomitant chemotherapy and immunosuppressants (35). The combination of compromised immunity and medications, which affect wound healing, suggests that a multifactorial model is required to explain the pathogenesis of ONJ (22). In the literature it is also possible to find cases of ONJ that developed in the absence of BPs and ONJ has been reported to occur only after chemotherapy with no BPs use (10). Osteonecrosis in other sites than the jaws may be produced also by a long-term high-dose glucocorticoids use (10). Moreover, patients with malignancies have a risk of developing osteomyelitis of the jaws that is 4 times higher than the normal, healthy population (10). The clinical picture of ONJ is similar to conventional osteomyelitis of the jaws (10). Moreover, ONJ may be

caused by combined and environmental and genetic risk factors (34). Moreover, toxic effects of chemotherapy have been described in the past 20 years.

In conclusion, there is certainly a temporal association between BP use and development of ONJ, but a correlation does not necessarily mean causation (4). In patients undergoing intravenous treatment, clinicians must be aware of the increased risk of implant failure and retarded wound healing and, probably, implant insertion should be avoided at all, until more conclusive data are available.

ONJ must be differentiated from osteomyelitis, delayed healing of extraction sockets, sequestra development, the presence of fistulae (28, 33).

ACKNOWLEDGMENTS

This work was partially supported by the National Research Council (CNR), Rome, Italy, and by the Ministry of Education, University, Research (MIUR), Rome, Italy.

REFERENCES

1. Kimmel DB. Mechanism of action, pharmacokinetic and pharmacodynamic profile and clinical applications of nitrogen-containing bisphosphonates. *J Dent Res* 2007;86:1022-1033.
2. Ruggiero SL, Mehrotra B, Rosenberg TJ, Engroff SL. Osteonecrosis of the jaws associated with the use of bisphosphonates: a review of 63 cases. *J Oral Maxillofac Surg* 2004;62:527-534.
3. Ficarra G, Beninati F, Rubino I, Vannucchi A, Longo G, Tonelli P, Pini Prato G. Osteonecrosis of the jaws in periodontal patients with a history of bisphosphonate treatment. *J Clin Periodontol* 2005;32:1123.
4. Diehl IJ, Fogelman I, Al-Nawas B et al. Pathophysiology, risk factors and management of bisphosphonate-associated osteonecrosis of the jaw: is there a diverse relationship of amino- and non-aminobisphosphonates? *Crit Rev Oncol/Haematol* 2007;64:198-207.
5. Migliorati CA, Schubert MM, Peterson DE, Seneda LM. Bisphosphonate-associated osteonecrosis of mandibular and maxillary bone. An emerging oral complication of supportive cancer therapy. *Cancer* 2005;104:83-93.
6. Ruggiero SL, Drew SJ. Osteonecrosis of the jaws and bisphosphonate therapy. *J Dent Res* 2007;86:1013-1021.
7. Sarin J, De Rossi SS, Akintoye SO. Updates on bisphosphonates and potential pathobiology of bisphosphonate-induced jaw osteonecrosis. *Oral Dis* 2008;14:277-285.
8. Boonyapakorn T, Schirmer I, Reichart PA, Sturdy I, Massenkeil G. Bisphosphonate-induced osteonecrosis of the jaws: prospective study of 80 patients with multiple myeloma and other malignancies. *Oral Oncol* 2008;44:857-69.
9. King AE, Umland EM. Osteonecrosis of the jaw in patients receiving intravenous or oral bisphosphonates. *Ann Oncol* 2009;20:331-6.
10. Abu-Id MH, Warnke PH, Gottschalk J, Springer I, Wiltfang J, Acil Y, Russo PAJ, Kreutsch T. "Bis-phoshy jaws" – High and low risk factors for bisphosphonate-induced osteonecrosis of the jaw. *J Craniomaxillofac Surg* 2008;36:95-103.
11. Van den Wyngaert T, Claeys T, Huizing MT, Vermorken JB, Fossion E. Initial experience with conservative treatment in cancer patients with osteonecrosis of the jaw (ONJ) and predictors of outcome. *Ann Oncol* (in press).
12. Hansen T, Kunke M, Weber A, Kirkpatrick CJ. Osteonecrosis of the jaws in patients treated with bisphosphonates – Histomorphologic analysis

- in comparison with infected osteoradionecrosis. *J Oral Pathol Med* 2006;35:155-160.
13. Coleman RE. Risks and benefits of bisphosphonates. *Brit J Cancer* 2008;98:1736-1740.
 14. Shoback D. Update in osteoporosis and metabolic bone disorders. *J Clin Endocrinol Metab* 2007;92:747-753.
 15. Ruggiero SL, Mehrotra B. Bisphosphonate-related osteonecrosis of the jaw: diagnosis, prevention and management. *Annu Rev Med* 2009;60:85-96.
 16. Brunello A, Saia G, Bedogni A, Scaglione G, Basso U. Worsening of osteonecrosis of the jaw during treatment with sunitinib in a patient with metastatic renal carcinoma. *Bone* 2009;44:173-175.
 17. Oteri G, Allegra A, Bellomo G et al. Reduced serum levels of interleukin 17 in patients with osteonecrosis of the jaw and in multiple myeloma subjects after bisphosphonates administration. *Cytokine* 2008;43:103-104.
 18. Aragon-Ching JB, Dahut WL. Osteonecrosis of the jaw and the use of antiangiogenic agents: just an association? *The Oncologist* 2008;13:1314.
 19. Stefanik D, Sarin J, Lam T, Levin L, Leboy PS, Akintoye SO. Disparate osteogenic response of mandible and iliac crest bone marrow stromal cells to pamidronate. *Oral Dis* 2008;14:465-471.
 20. Naidu A, Dechow PC, Spears R, Wright JM, Kessler HP, Oppermann LA. The effect of bisphosphonates on osteoblasts in vitro. *Oral Surg Oral Med Oral Pathol Endod Radiol* 2008;106:829-837.
 21. Edwards BJ, Gounder M, McKay JM et al. Pharmacovigilance and reporting oversight in US FDA fast-track process: bisphosphonates and osteonecrosis of the jaw. *Lancet Oncol* 2008;9:1166-1172.
 22. Rizzoli R, Burllet N, Cahall D et al. Osteonecrosis of the jaw and bisphosphonate treatment for osteoporosis. *Bone* 2008;42:841-847.
 23. Raje N, Woo SB, Hande K et al. Clinical, radiographic and biochemical characterization of multiple myeloma patients with osteonecrosis of the jaw. *Clin Cancer Res* 2008;14:2387-2395.
 24. Bell BM, Bell RE. Oral Bisphosphonates and dental implants: a retrospective study. *J Oral Maxillofac Surg* 2008;66:1022-1024.
 25. Grant BT, Amenedo C, Freeman K, Kraut RA. Outcomes of placing dental implants in patients taking oral bisphosphonates: a review of 115 cases. *J Oral Maxillofac Surg* 2008;66:223-230.
 26. Wang HL, Weber D, McCauley LK. Effect of long-term oral bisphosphonates on implant wound healing: literature review and a case report. *J Periodontol* 2007;78:584-594.
 27. Bedogni A, Blandamura S, Lokomic Z et al. Bisphosphonate-associated jawbone osteonecrosis: a correlation between imaging techniques and histopathology. *Oral Surg Oral Med Oral Pathol Endod Radiol* 2008;105:358-364.
 28. Reid IR, Bolland MJ, Grey AB. Is bisphosphonate-associated osteonecrosis of the jaw caused by soft tissue toxicity. *Bone* 2007;41:318-320.
 29. Bagan JV, Murillo J, Jimenez Y, Poveda R, Milian MA, Sanchis JM, Silvestre FJ, Scully C. Avascular jaw osteonecrosis in association with cancer chemotherapy: series of 10 cases. *J Oral Pathol Med* 2005;34:120-123.
 30. Scully C, Madrid C, Bagan J. Dental endosseous implants in patients on bisphosphonate therapy. *Implant Dent* 2006;15:212-218.
 31. Piattelli A, Scarano A, Quaranta M. High-precision, cost-effective system for producing thin sections of oral tissues containing dental implants. *Biomaterials* 1997;18:577-579.
 32. Hoff AO, Toth BB, Altundag K et al. Frequency and risk factors associated with osteonecrosis of the jaw in cancer patients treated with intravenous bisphosphonates. *J Bone Miner Res* 2008;23:826-836.
 33. Badros A, Terpos E, Katodritou E et al. Natural history of osteonecrosis of the jaw in patients with multiple myeloma. *J Clin Oncol* 2008;26:5904-5909.
 34. Sarasquete ME, Garcia-Sanz R, Marin L et al. Bisphosphonate-related osteonecrosis of the jaws is associated with polymorphisms of the cytochrome P450 CYP2C8 in multiple myeloma: a genome-wide single nucleotide polymorphism analysis. *Blood* 2008;112:2709-2712.
 35. Landesberg R, Cozin M, Cremers S, Woo V, Kousteni S, Sinha S, Garrett-Sinha LA, Raghavan S. Inhibition of oral mucosal cell wound healing by bisphosphonates. *J Oral Maxillofac Surg* 2008;66:839-847.