

➤ **ARIS PETROS TRIPODAKIS¹, HERCULES GOUSSIAS², PANAGIOTIS ANDRITSAKIS³**

¹ Associate Professor, National and Kapodistrian University of Athens, Department of Prosthodontics

² Lecturer, National and Kapodistrian University of Athens, Department of Prosthodontics

³ Instructor, National and Kapodistrian University of Athens, Department of Prosthodontics

Immediate prostheses on one-piece trans-mucosal implants in flapless surgical procedures Case Series Report. Part I: full arch rehabilitations

TO CITE THIS ARTICLE

Tripodakis AP, Goussias H, Andritsakis P. Immediate prostheses on one-piece trans-mucosal implants in flapless surgical procedures – Case Series Report. Part I: full arch rehabilitations J Osseointegr 2012;2(4):31-36.

KEY WORDS Flapless surgery; Full arch prosthesis; One piece implants.

ABSTRACT

Aim The aim of the present case series report is to illustrate a clinical technique and present the application of one-piece transmucosal implants in flapless surgical procedures, supporting full arch immediate prostheses.

Materials and methods A total of 294 implants (Xive TG, Friudent, Germany) have been used to support full arch immediate prostheses, over the last six years and have been in function for at least one year. The surgical placement of five or more implants per case involved immediate extraction and intrasocket flapless placement, combined with minimal flap elevation in the areas of healed extraction sites (43 mandibular and 7 maxillary arches). In all cases immediate provisionalization followed. Detailed three-dimensional cone-beam localized volumetric tomography preceded the surgical procedures. The delivery of the final ceramo-metal prostheses was accomplished within a 20 day period.

Results Six implants failed to osseointegrate. All other implants are still successfully bearing the final prosthesis for the time that they have been followed. Soft tissue reaction was favorable from both the biologic and esthetic point of view.

Conclusion The flapless placement of one piece implants into edentulous healed sites is a predictable procedure in the presence of abundance of supporting bone as confirmed by 3-D imaging. On the other hand, immediate extraction placement of one piece implants allows the engagement of sound bone located deeper into the socket and provides adequate mechanical support of the soft tissue architecture that is preserved predictably. In all cases the prosthetic procedures are accomplished without disturbing the hard-soft tissue interface as the abutment-prosthesis interface is coronally elevated by the virtual design of the implant.

INTRODUCTION

Osseointegrated implants were originally successfully applied by the two stage surgical approach. The implant insertion at first stage was followed by the abutment connection during a second stage surgical procedure. In this approach the two piece implant–transmucosal abutment complex was absolutely necessary and therefore implemented. The connection of the two separate pieces in intimate vicinity with the vulnerable hard and soft tissue interface of the supporting structures, inevitably was followed by biological flaws (1,2). The implant–abutment junction's micro gap could act as a bacterial trap (3). The retrieval or interchange of the transmucosal element, on the other hand, could generate an adverse biological consequence of the disruption of the intimate soft tissue adaptation.

Nowadays, one stage immediate transmucosal provisionalisation and function have been widely documented and broadly clinically applied both in single and multiple implant restorations (5, 6, 7). Such an approach totally eliminates the requirement of the two-piece implant/abutment complex, allowing the application of one-piece transmucosal implants. Thus the implant–restorative interface is elevated on a higher level, closer to the marginal area of the peri-implant soft tissue. In that way the previously described biological drawbacks are fully eliminated. Clinical procedures are facilitated and oral hygiene is more controllable.

Minimal or no flap elevation combined with one stage surgery has also been suggested (8, 9). Thus, the surgical trauma is reduced minimizing post-surgical discomfort. By applying one-piece implants in flapless surgical procedures, mechanical support is immediately provided to the soft periimplant tissue collar. Also the

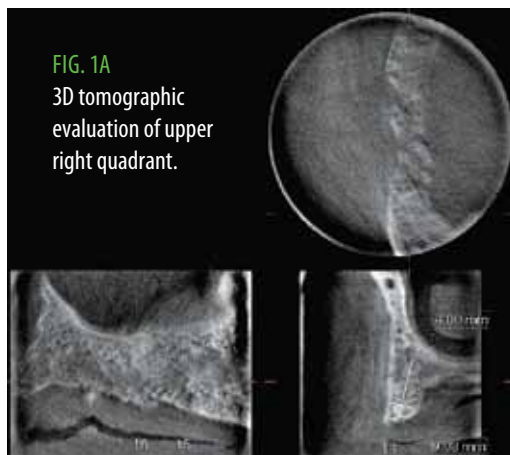


FIG. 1A
3D tomographic
evaluation of upper
right quadrant.

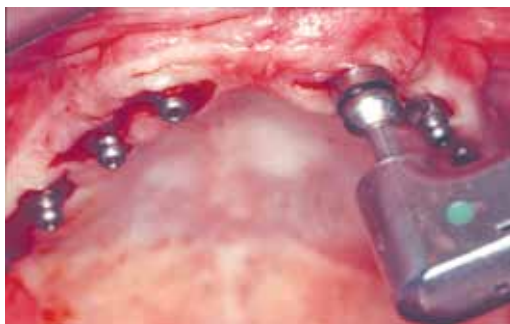

FIG. 1C Flapless implant surgical insertion by levelling the threaded-smooth interface with the soft-hard tissue interface.

intimate soft tissue adaptation on the coronal part of the implant remains undisturbed. Therefore the maintenance and the preservation of the pre-existing soft tissue architecture are fairly accomplished. The aim of the present case series is to illustrate a clinical technique and present the application of one-piece transmucosal implants in flapless surgical procedures, supporting multiple implant immediate full arch prostheses.

MATERIALS AND METHODS

Patient population

A total of 50 patients in general good health (20 men and 30 women) have received full arch immediate prostheses (7 maxillary and 43 mandibular), supported by 294 implants in total, that have been in function over the last six years. Fifteen smokers were not excluded while only 4 patients were fully edentulous.

Radiographic evaluation

The presence of sufficient residual bone volume was confirmed radiographically. In all cases orthopantomographic imaging was followed by detailed three-dimensional cone-beam localized volumetric tomography (Morita Accuitomo, Japan) (Fig. 1a). Only patients that presented supporting bone of at least 13

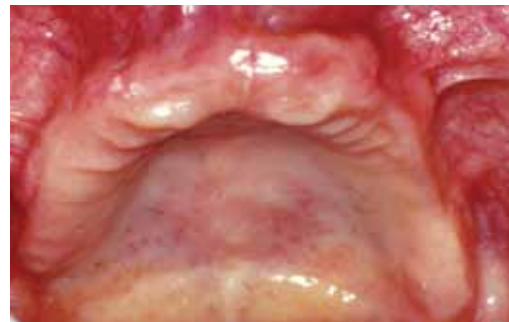

FIG. 1B Preoperative clinical situation of edentulous maxilla.

mm in height and 5 mm in width were included. Therefore the danger of an unsuccessful implant placement due to the limited visual access caused by the flapless surgical approach was minimized.

Presurgical preparation

Conservative periodontal treatment preceding the surgery involved full mouth sub-gingival scaling when natural teeth were preoperatively present. The patients were repeatedly instructed to perform thorough plaque control. Antibiotics were prescribed one day preoperatively.

Surgical procedure

In edentulous sites (Fig. 1b) the surgical approach was accomplished without flap elevation, through a minor slit of the tissue (Fig. 1c), guided by the related tomogram, leveling the threaded-smooth interface with the soft-hard tissue interface. No surgical guide was used while no attempt was made to attain absolute parallelism of the implants. The common path of insertion for the future screw-retained superstructure on the short external retentive square features on the implant heads was granted by their tapered design and therefore was independent of the axial divergence of the implants. In posterior mandible sites, above the mandibular canal, 9,5 or 11 mm long implants were used. Generally, minimal amount of suturing was applied.

In dentate sites (Fig. 2a) after atraumatic extraction of the teeth, the sockets were rinsed thoroughly with clorexidine solution. Thorough rinsing with saline solution followed. The flapless preparation of the implant bed was started inside the extraction socket, on the apical third of the palatal or lingual bone wall guided by the specific tomogram, in order to avoid contact with the labial osseous plate and was directed towards the basal bone. At least 13 mm long and 3.4 mm wide implants excluding the collar (Xive TG, Dentsply-Friudent, Mannheim Germany) were self-tapped with a torque of 42 N/cm (Fig. 2b).

Prosthetic procedures

Impression copings (Standard XiVE TG transfer impression copings, Dentsply-Friudent, Germany)

were mounted on the implants immediately after insertion (Fig. 2c). Although an open tray impression procedure would have been preferable for precision, a closed tray was used. The reason was that the existing open tray impression coping, originally designed for single implant restorations, is firmly engaging the external anti-rotational mechanism located on the head of the implant. In that way upon removal some of the impression copings would not eventually freely disengage. Occasionally however, on specific implants in

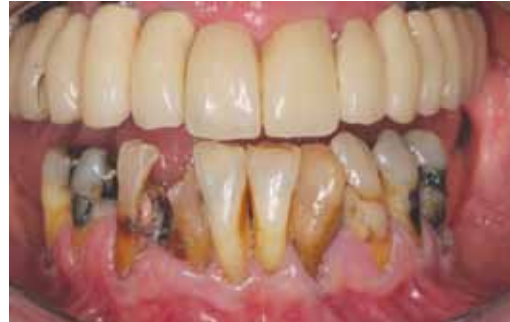

FIG. 2A Preoperative clinical situation of terminal mandibular dentition.

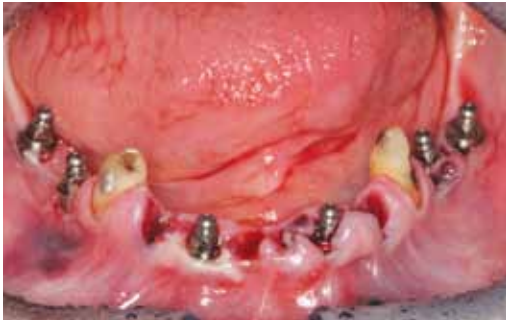

FIG. 2B Immediate intrasocket implant placement providing adequate soft tissue support and preservation.

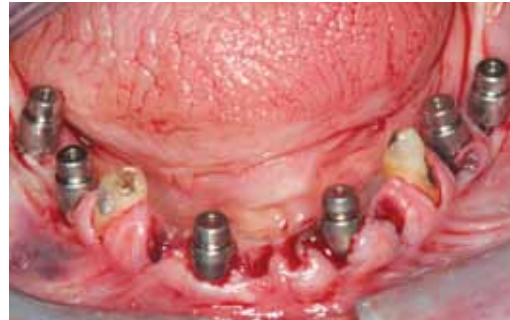

FIG. 2C Closed tray impression copings were mounted on the implants immediately after insertion.

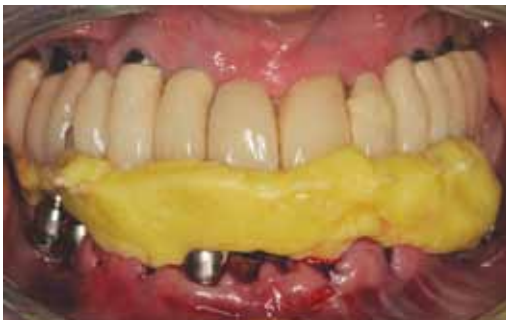

FIG. 2D Initial occlusal registration procedures were immediately performed on the impression copings by using polyether registration material.

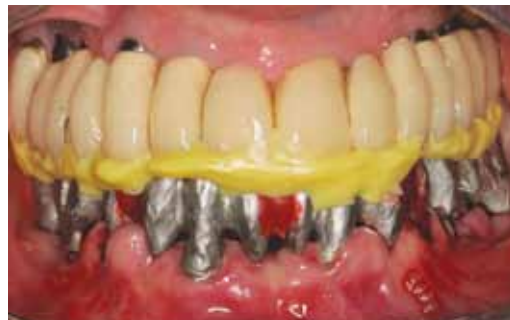

FIG. 2E Improvement of the passivity of the fit of the metal framework was followed by corrective occlusal registration during try-in.

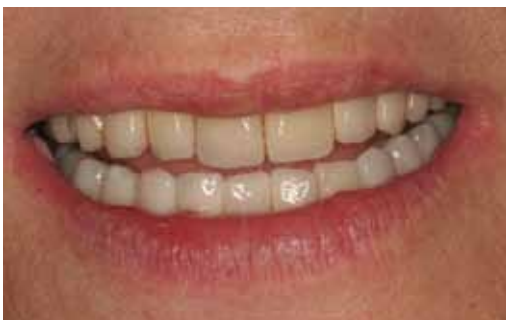

FIG. 2F One year postoperative appearance extraorally.

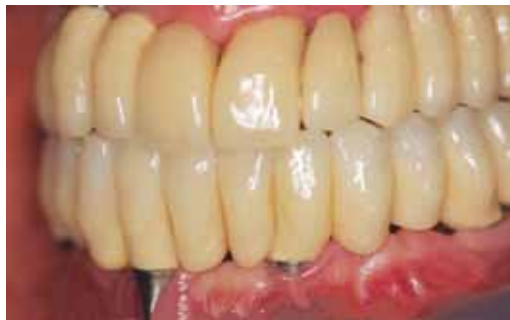

FIG. 2G One year postoperative appearance intraorally.

which the heads were found to be below the soft tissue crest, open tray impression copings were used by simply snapping them on the implant head, without fastening them by the stabilizing screw. By doing so, the retentive impression coping head was engaged and lifted by the closed tray impression material and therefore a more

precise orientation was maintained.

The final impression was made using polyether material (Permadyne heavy body 3M ESPE, Seefeld, Germany) and occlusal registration procedures followed using polyether registration material (Ramitec, 3M ESPE, Seefeld, Germany) (Fig. 2d). The impression copings

were then replaced by healing cups on which transitional pressure cured shell acrylic restorations were intraorally relined. Unfortunately no other available components could offer a more viable transitional approach. The clinical possibility of using additional natural tooth retention for the provisional restoration by strategically postponing the extraction of certain teeth, has also been applied.

Standard prosthetic procedures were used to fabricate the final screw-retained ceramo-metal prostheses that were inserted within the next three postoperative weeks. In most cases during the framework try-in, cut and laser welding procedures secured the passivity of fit (Fig. 2e). The cross-arch rigid stabilization of the implants, achieved by the splinting action of the superstructure, neutralized the effect of the initial reduction of mechanical stability of the implants, while their biologic osseous integration was not fully matured. Moreover upon the final delivery of the prosthesis the soft tissue healing was still in process.

Thus an occasional partial visual exposure of the Titanium transmucosal collar zone was to be expected following the healing completion (Fig.2f, 2g).

RESULTS

In total 294 implants were inserted supporting 7 maxillary and the 43 mandibular full-arch reconstructions. The overall outcome after one to six years of function was shown to be favorable from a functional, biologic and esthetic point of view. Osseointegration was successfully achieved with the exception of 5 implants (4 implants in two mandibular reconstructions and 1 maxillary) that failed after a period of approximately 6-18 months of function. In these 3 cases, the insertion of additional implants was mandatory and the reconstruction of a new prosthesis followed. All other implants are still successfully supporting the final prosthesis.

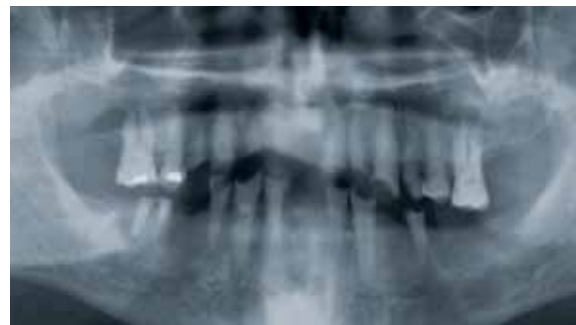
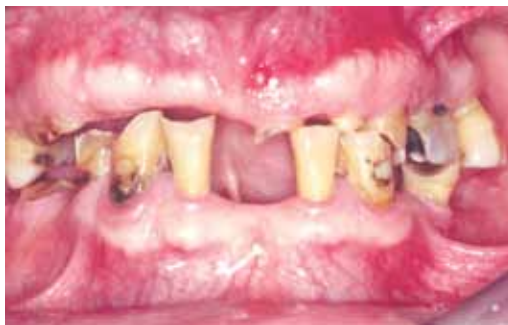

FIG. 3A Preoperative clinical situation of a maxillo-mandibular terminal dentition. FIG. 3B Preoperative orthopantomogram.

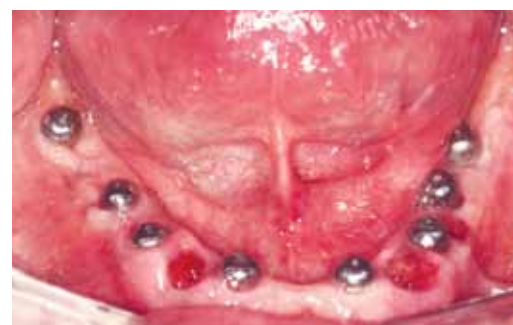
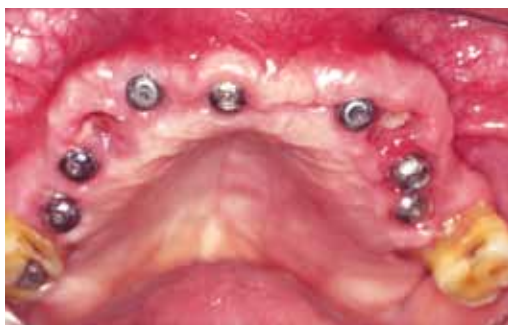
FIG. 3C Soft tissue healing 15 days postoperatively in the maxilla.

FIG. 3D Soft tissue healing 15 days postoperatively in the jaw.

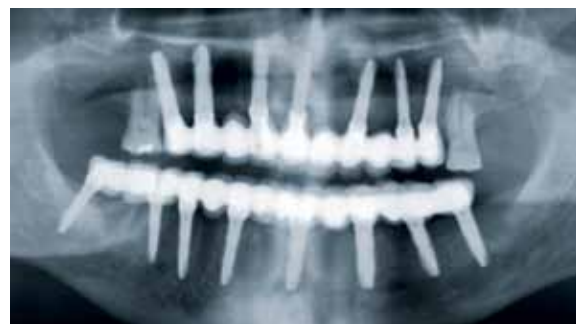
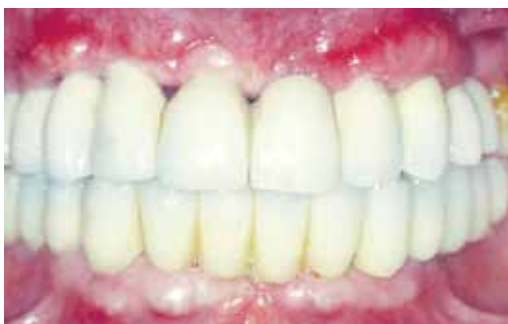
FIG. 3E Clinical appearance 25 days postoperatively.

FIG. 3F Orthopantomogram 5 years postoperatively.

Soft tissue reaction was also biologically favorable. Moreover the prosthetic procedures are accomplished without disturbing the hard-soft tissue junction as the implant/restorative interface is established away from it, due to the virtual one-piece design of the implant (Fig. 3a-3f). In general in the treated cases cervical esthetics was not a priority and therefore the occasional esthetic compromise due to the partial visual exposure of the Titanium transmucosal collar zone, was considered esthetically insignificant.

DISCUSSION

The placement of one-piece trans-mucosal implant by a flapless surgical approach is a clinical procedure providing simultaneously hard and soft tissue integration. It combines the necessary foundation by the anchorage to the supporting bone with the provided adequate mechanical support and undisturbed biologic response of the soft tissue. The machine-polished transgingival implant extension Ti collar (TG), acts as the ideal support for the soft tissue intimate adaptation, while the oral hygiene procedures are facilitated.

The flapless approach in all cases (both dentate and edentulous) is mainly a rather atraumatic surgical procedure. Denuding the bone from the periosteum subsequent to an elevated flap, momentarily jeopardizes the normal blood supply of the surgical site, and inevitably leads to further bone loss. In a flapless surgical intervention the host defense mechanism and the regenerative potential are kept in full action by the uninterrupted blood supply during wound healing (10, 11). In addition to that, the reduced trauma is favorably accepted by patients. Nevertheless the visual access of the surgical site is inevitably limited. Surgical guidance in the presently described clinical approach was assisted by the detailed cone-beam three-dimensional tomographic evaluation. Computer navigation systems could even better secure an accurate implant orientation. In all cases however, the absolute prerequisite for flapless surgical procedures is the presence of adequate bone volume both in height and width. If the bone volume is limited, flap elevation is mandatory.

In edentulous patients immediate implant placement into the extraction socket provides adequate support of the soft tissue architecture that is predictably preserved (12-14). The implant in such cases tends to attain a deeper location that is compensated by the presence of its transmucosal extension. Thus the implant restorative interface is elevated in a more coronal level, away from the supporting bone.

Immediate loading of the implants provided by the function established by the immediate provisionalization is a very well documented modality both experimentally and clinically.

Favorable load distribution, that results from splinting the implants by the immediate provisional restoration, assures the elimination of micro movements. Nkenke et al concluded in their research: immediate loading does not affect the bone mineral apposition rate when compared with unloaded implants. Rigid splinting seems to be the crucial factor for implant success. Uncontrolled masticatory forces can cause failure after partial loss of the provisional restoration (4).

In the 50 clinical cases that were restored by full arch immediate prostheses on one-piece trans-mucosal implants inserted by the flapless surgical approach, the failures that occurred can be interpreted as follows.

- › The reported mandibular failures of four implants 15 mm in length, inserted in immediate extraction compromised sites between two mental foramina developed a painful reaction and subsequent radiographic radiolucency. Possible explanations could be the unfavorable biologic and anatomic condition of the defect or even the overheating of the dense mandibular bone.
- › The maxillary implant failed due to overloading that followed the fracture of a soldered joint.
- › The 3 reconstructions had to be repeated after additional implant placement.

The social advantages and quality of life enhancement of the presented clinical modality are also important. The reduced trauma and the immediate restoration are the important features for treatment acceptance and patient satisfaction.

The decrease of the number of both the necessary clinical procedures and the components required creates a cost effective treatment, financially beneficial for the patient and the dentist.

CONCLUSIONS

1. The flapless placement of one piece implants into edentulous healed sites is a predictable procedure in the presence of abundance of supporting bone as confirmed by 3-D imaging.
2. The placement of such implants in immediate extraction sockets allows the engagement of sound bone located deeper into the socket and provides adequate mechanical support of the soft tissue architecture that is predictably preserved.
3. The limited visual access has to be compensated by the 3-D tomographic evaluation.
4. The prosthodontic procedures are accomplished without disturbing the hard-soft tissue interface as the abutment-prosthesis interface is coronally elevated by the virtual design of the implant.
5. One-piece trans-mucosal immediate implants, combined with flapless surgical procedures can be used predictably for immediate prostheses with functional, biologic and esthetic advantages.

REFERENCES

1. James RA. Peri-implant considerations. *Dent Clin North Am* 1980;24(3):415-20.
2. Jansen VK, Conrads G, Richter EJ. Microbial leakage and marginal fit of the implant-abutment interface. *Int J Oral Maxillofac Implants* 1997;12(4):527-40.
3. Jansen VK, Conrads G, Richter EJ. Microbial leakage and marginal fit of the implantabutment interface. *Int J Oral Maxillofac Implants* 1997; 12(4): 527-40. Erratum in: *Int J Oral Maxillofac Implants* 1997; 12(5): 709.
4. Nkenke E, Lehner B, Weinzierl K, Thams U, Neugebauer J, Steveling H, Radespiel-Tröger M, Neukam FW. Bone contact, growth, and density around immediately loaded implants in the mandible of mini-pigs. *Clin Oral Implants Res* 2003; 14(3):312-21.
5. Degidi M, Piattelli A, Gehrke P, Carinci F. Clinical outcome of 802 immediately loaded 2-stage submerged implants with a new grit-blasted and acid-etched surface: 12-month follow-up. *Int J Oral Maxillofac Implants* 2006; 21(5):763-8.
6. Degidi M, Piattelli A. Immediate functional and non-functional loading of dental implants: A 2- to 60-month follow-up study of 646 titanium implants. *J Periodonol* 2003; 74(2):225-41.
7. Neugebauer J, Traini T, Thams U, Piattelli A, Zöller JE. Peri-implant bone organization under immediate loading state. Circularly polarized light analyses: a minipig study. *J Periodonol* 2006; 77(2):152-60.
8. Brodala N. Flapless surgery and its effect on dental implant outcomes. *Int J Oral Maxillofac Implants* 2009;24 Suppl:118-25.
9. Mahn DH, Polack MA. Esthetic rehabilitation of maxillary incisors in conjunction with flapless surgical techniques, an implant zirconia crown, and porcelain veneers. *J Esthet Restor Dent* 2009;21(5):294-302.
10. Melcher AH, Accursi GE. Osteogenic capacity of periosteal and osteoperiosteal flaps elevated from parietal bone of the rat. *Arch Oral Biol* 1971;16(6):573-80.
11. Hjorting-Hansen E, Andreasen JO. Incomplete bone healing of experiment cavities in dog mandible. *Br J Oral Surg* 1971;9(1):33-40.
12. Tripodakis APD. Sofortimplantation in infizierte und defekte Extraktionsalveolen un kontrollierte Sofortimplantatbelastung. *Implantologie* 2001;1: 13-25.
13. Tripodakis APD. Sofortimplantation in infizierte und defekte Extraktionsalveolen und provisorische prothetische Versorgung. *Implantologie* 2002;10(3):271-286.
14. Tripodakis AP, Nakou M. Microbiologic evaluation of compromised periodontal sites before and after immediate intrasocket implant placement. *Int J Periodontics Restorative Dent* 2011;31(6):109-17.